



## CASE REPORT

### Cutaneous Adverse Drug Reaction in a Cat Following Intravenous Administration of Cephadrine

Min-Hee Kang, Jae-Yun Ko and Hee-Myung Park\*

Department of Veterinary Internal Medicine, College of Veterinary Medicine, Konkuk University, Seoul, 05029, South Korea

\*Corresponding author: parkhee@konkuk.ac.kr

#### ARTICLE HISTORY (18-190)

Received: May 22, 2018  
Revised: June 05, 2018  
Accepted: July 17, 2018  
Published online: October 21, 2018

#### Key words:

Cat  
Cephadrine  
Cutaneous adverse drug reaction  
Vasculitis

#### ABSTRACT

A 3-year-old domestic short-haired cat presented with painful, thick-crust skin lesions on both forelimbs. Following intravenous injection of cephadrine in both forelimbs, edema occurred from the toe to the axillary area, with ulceration and necrosis present around the injection site. A skin biopsy and histological examination revealed severe neutrophil, lymphocyte, and macrophage infiltration in the dermis and hypodermis, without dermo-epidermal separation. Based on the medical history, skin lesions, and histological findings, the cat was diagnosed with CADR from the intravenous injection. Oral prednisolone (2 mg/kg) was administered twice daily, and topical chlorhexidine gluconate 0.5% solution and mupirocin 2% ointment were applied to the lesions. The progress of necrosis was stopped and the skin lesions disappeared completely after 114 days. CADR characterized by extensive necrosis and large skin defects following injection of antibiotics are rare in cats. Long-term management with prednisolone was effective in treating the conditions in this case.

©2018 PVJ. All rights reserved

**To Cite This Article:** Kang MH, Ko JY and Park HM, 2018. Cutaneous adverse drug reaction in a cat following intravenous administration of cephadrine. Pak Vet J. <http://dx.doi.org/10.29261/pakvetj/2018.098>

#### INTRODUCTION

Cutaneous adverse drug reaction (CADR) is a type of adverse drug reaction (ADR) in which the affected skin is primarily targeted by topical, oral, or injectable drug administration (Muller *et al.*, 2012). The skin lesions are variable, but common patterns in CADR include papules, plaques, pustules, vesicles, bullae, purpura, erythema, urticarial, angioedema, alopecia, erythema multiforme or toxic epidermal necrolysis (TEN) lesions, scaling or exfoliation, erosions, and ulcerations (Voie *et al.*, 2012; Sartori and Colombo, 2016). Concurrent fever, depression, or lameness may be present (Muller *et al.*, 2012). The most common drugs associated with CADR are topical antibacterials and anthelmintics (Utrecht and Naisbitt, 2013). ADR is common and remains a challenge to morbidity and mortality in humans, however, their effects are underestimated in veterinary medicine because mild symptoms and the presence of hair makes detection difficult (Voie *et al.*, 2012). This report describes long-term management of the extensive necrosis and large skin defect due to cutaneous vasculitis followed by injected cephadrine in a cat.

**Case history and findings:** A 3-year-old, castrated male, domestic short-haired cat (body weight 5.1 kg) was referred because of cutaneous necrosis on both forelimbs. The cat had been diagnosed with femoral neck metaphyseal osteopathy on both hindlimbs 2 weeks previously, and an excision arthroplasty was performed by the referring veterinarian. After the surgery, the cat was treated with an intravenous injection of 30 mg/kg cephadrine (Cefradine, Dongkwang, Seoul, Korea) on the right forelimb to prevent secondary infection. Following drug injection, edematous change in the right forelimb was observed. The injection site was changed to the left forelimb and the same drug was injected. A day later, the left forelimb also started to swell. Extensive forelimb swelling occurred from shoulder to toes and the injection was discontinued. Erythema and exudate were observed after 8 days and skin necrosis was observed after 14 days around the injection site, which was more severe in the left forelimb and the cat was referred 16 days after the first lesion was noticed.

The abnormal physical findings at presentation were painful, thick crusted skin lesions characterized by devitalized tissue on both forelimbs. The skin between the elbow and the carpal joint on the right side was affected.

The skin lesions of the left elbow were more severe than those on the right side, which extended over the scapula to the metacarpal area (Fig. 1). Based on the history, clinical signs, and skin lesions, the primary differential diagnoses were cutaneous adverse drug reaction (CADR) and other immune-mediated diseases, such as erythema multiforme and TEN. Blood examination including complete blood count, serum biochemistry, and electrolyte levels, were normal. Additional radiographs were taken to assess the thorax, abdomen, and forelimbs; no abnormalities were noted.

Skin biopsy specimens of both forelimbs were obtained from the adherent crusted necrotic tissue around the skin lesions. A punch biopsy (diameter, 6 mm) was used. Histological examinations revealed severe neutrophil, lymphocyte, and macrophage infiltration in the dermis without dermo-epidermal separation. The hypodermal region also showed necrotic changes with neutrophil and macrophage infiltration (Fig. 2A-2C). The lymphocytic infiltration in the perivascular region is marked in Fig. 2D. Further immunohistochemical staining, performed to detect lymphocytes of the perivascular region, noted T lymphocyte infiltration (Fig. 3). Based on history, skin lesions, and histological findings, the cat was diagnosed with vasculitis caused by adverse drug reactions.

Treatment with prednisolone (Solondo, Yuhan Medica, Seoul, Korea) (2mg/kg twice daily PO) was initiated in combination with administration of oral enrofloxacin (Baytril, Bayer, Kansas, USA) 5 mg/kg once daily and pentoxifylline (Trental, Handok, Seoul, Korea) 100 mg/cat twice daily. The area was disinfected with sterile saline and antiseptic dressing was performed daily with chlorhexidine gluconate 0.5% solution and mupirocin 2% ointment. After 1 week, necrotic tissue was sloughing and granulation tissue with exudate was noted. Prednisolone 2 mg/kg twice daily PO was administered for 2 weeks, and daily wet dressing was applied. Additional expansion of the skin necrotic lesion was not observed. Over a period of 4 weeks, the dose of prednisolone was gradually tapered to 0.5mg/kg twice daily. On day 37, skin lesions on the right forelimb disappeared and the skin was restored. The skin of the left forelimb was healed completely at 114 days, at which time treatment with prednisolone was discontinued (Fig. 1). During the 6-month follow-up, no skin lesions were observed.

## DISCUSSION

In this case, cephadrine was administered at a therapeutic dose to both forelimbs intravenously and each showed an edematous change immediately after drug injection, which subsequently progressed to necrosis. ADR results from an undesired response to drug administration, which may be dose-dependent or idiosyncratic (Utrecht and Naisbitt, 2013). Dose-dependent ADR is more common, occurring in a predictable manner according to the pharmacological and toxic properties of the drug. On the contrary, the idiosyncratic form of ADR is unpredictable because it can occur at the therapeutic dose (Muller *et al.*, 2012; Voie *et*

*al.*, 2012). Thus, this case could be classified as an idiosyncratic CADR.

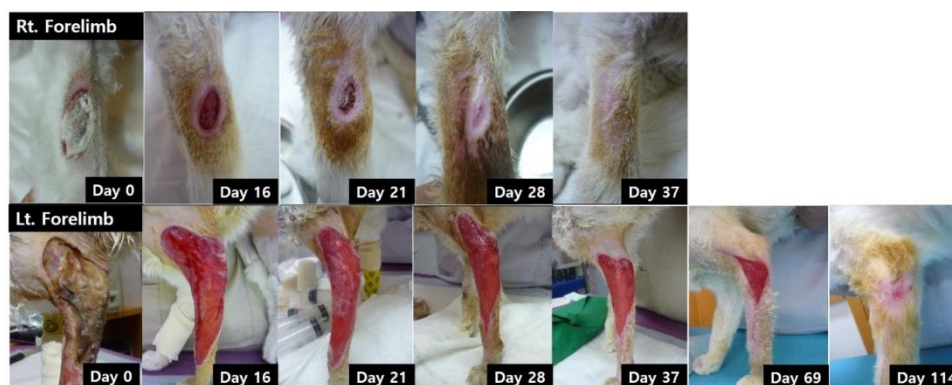For the diagnosis of CADR, accurate history and information about the clinical features are important; moreover, histopathological examinations are helpful for differential diagnosis (Sartori and Colombo, 2016). After consideration of the history and clinical features at the time of admission, severe skin disorders such as TEN and vasculitis were included in the differential diagnosis in the case of this cat. Based on the history, severe skin lesions, and histopathological examination results, this cat was diagnosed with the CADR of vasculitis.

Currently, there are four different theories for the pathogenesis of ADR: 1) the hapten-prohapten hypothesis, in which chemically reactive small molecules (haptens) or protein-reactive metabolites of drugs (prohaptens) form protein-drug complexes that accelerate the inflammatory immune response and T-cell proliferation through antigen presentation; 2) the danger theory, in which the drug or its metabolites lead to cell debris formation, oxidative stress, or inflammation, which cause cell damage by the “danger cascade”; 3) the pharmacological interaction concept, in which the drug itself interacts directly with the major histocompatibility complex or T cell receptors; and 4) viral reactivation, which arises from the relationship between viral disease and drug hypersensitivity (Lavergne *et al.*, 2008; Voie *et al.*, 2012). Among these theories, the hapten-prohapten hypothesis is known to be related to drugs such as penicillins, sulfonamides, and acetaminophen (Lavergne *et al.*, 2008). The cross-reactivity between penicillin and cephalosporin is related to a unique hapten and its determinant shared with penicillin, which causes an allergic reaction (Islek *et al.*, 2003; Antunez *et al.*, 2006). Several types of skin lesions including morbilliform, erythema multiforme, and TEN/Steven-Johnson syndrome, have also been reported to be induced by cephalosporin and cefadroxil in cats (Muller *et al.*, 2012; Sartori and Colombo, 2016). Thus, the injection of cephadrine may have triggered a CADR in this cat that followed the mechanism suggested in the hapten-prohapten hypothesis.

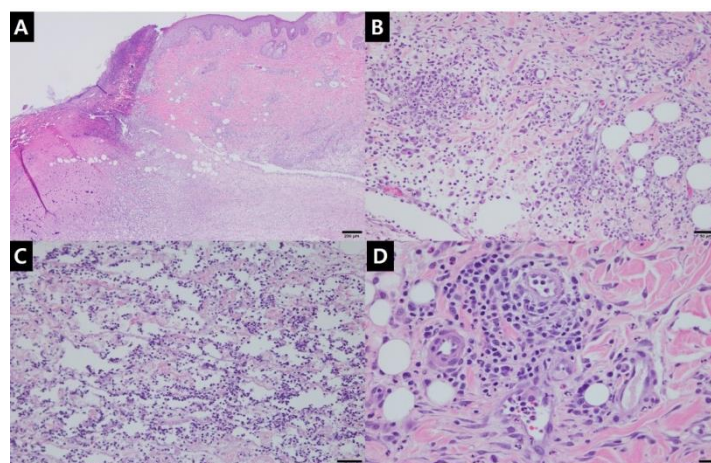
The “gold standard” method for the identification of the cause of a CADR is the drug provocation test (DPT) (Aberer *et al.*, 2003). However, drug hypersensitivity can lead to clinical signs after re-exposure or, in severe cases, may be life-threatening. Therefore, considering the cat’s clinical signs and conditions, DPT was not performed, which prevented confirmation of the cause of CADR.

Although corticosteroids inhibit the function of suppressor T lymphocytes and may be beneficial for controlling CADRs, the use of glucocorticoids in patients with skin necrosis remains controversial because of the risk of sepsis (Manchanda *et al.*, 2018). In this case, the skin lesions were well-managed with glucocorticoids.

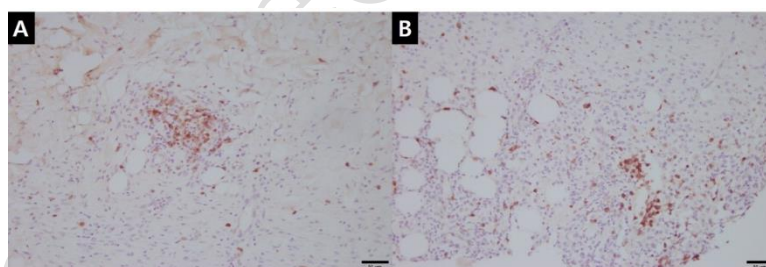
This report has described the history and clinical patterns associated with cephadrine injection. Long-term management with prednisolone was beneficial and successful in this cat. Our report suggests that clinicians should consider the possibility of CADR when using antibiotics, including cephadrine, regardless of the route of administration.



**Fig. 1:** Extensive skin necrosis by cutaneous adverse drug reaction in a cat. On day 0, right and left forelimbs showed well demarcated area of dead skin, necrotic changes and erythema around skin lesions. Over time, the entire area was slough and beginning to form granulation tissue. The necrotic lesions disappeared with the skin restoration (right forelimb, day 37; left forelimb, day 114).



**Fig. 2:** Histopathological evaluation of extensive skin necrosis in a cat. Left forelimb skin lesions showed severe necrotic lesions with numerous inflammatory cells, neutrophils, lymphocytes, and macrophages (A, Bar=200  $\mu$ l). Note the inflammatory cells infiltration in the dermis (B) and hypodermis (C) (Bar=50  $\mu$ l). Lymphocyte infiltration was marked at the perivascular region (D, Bar=20  $\mu$ l) in the dermis. H&E.



**Fig. 3:** Immunohistochemical evaluation of extensive skin necrosis in a cat. Immunohistochemical staining (CD3) for T lymphocyte detection demonstrating numerous positive T lymphocytes at the perivascular region in the dermis (A, B; Bar=50  $\mu$ l).

**Acknowledgements:** This paper was supported by Konkuk University in 2017.

**Authors contribution:** KMH and KJY took part in the care of the patient and contributed in preparation of the manuscript. The manuscript was prepared by KMH under the supervision of PHM. All authors critically revised the manuscript and approved the final manuscript.

## REFERENCES

- Aberer W, Bircher A and Romano A, 2003. Drug provocation testing in the diagnosis of drug hypersensitivity reactions general considerations. *Allergy* 58:854-63.
- Antunez C, Blanca-Lopez N, Torres MJ, et al., 2006. Immediate allergic reactions to cephalosporins: Evaluation of crossreactivity with a panel of penicillin and cephalosporins. *J Allergy Clin Immunol* 117: 404-10.
- Islek I, Baris S and Katrancı AO, 2003. Hypersensitivity vasculitis induced by cefoperazone/sulbactam. *Ann Clin Microbiol Antimicrob* 2:1.
- Lavergne SN, Park BK and Naisbitt DJ, 2008. The roles of drug metabolism in the pathogenesis of T-cell-mediated drug hypersensitivity. *Curr Opin Allergy Clin Immunol* 8:299-307.
- Manchanda Y, Das S, Sarda A, et al., 2018. Controversies in the management of cutaneous adverse drug reactions. *Indian J Dermatol* 63:125-30.
- Muller WJ, Griffin CE and Campbell KL, 2012. Muller and Kirk's small animal dermatology. 7<sup>th</sup> ed. St Louis (MO): Saunders; pp:466-88.
- Sartori R and Colombo S, 2016. Stevens-Johnson syndrome/toxic epidermal necrolysis caused by cefadroxil in a cat. *JFMS Open Rep* 2:2055116916653616.
- Utrecht J and Naisbitt DJ, 2013. Idiosyncratic adverse drug reactions: current concepts. *Pharmacol Rev* 65:779-808.
- Voie KL, Campbell KL and Lavergne SN, 2012. Drug hypersensitivity reactions targeting the skin in dogs and cats. *J Vet Intern Med* 26:863-74.