



RESEARCH ARTICLE

Digit Bones (Acropodium) of Gazella (*Gazella subgutturosa*); Three-Dimensional Modelling and Morphometry

İsmail Demircioğlu¹, Ali Koçyiğit², Yasin Demiraslan³, Bestami Yılmaz¹, Nazan Gezer Ince⁴, Sedat Aydoğdu² and Mustafa Orhun Dayan^{2*}

¹Harran University, Faculty of Veterinary Medicine, Department of Anatomy, 63050, Şanlıurfa, Turkey

²Selçuk University Faculty of Veterinary Medicine, Department of Anatomy, 42100, Konya, Turkey

³Burdur Mehmet Akif Ersoy University Faculty of Veterinary Medicine, Department of Anatomy, 15100, Burdur, Turkey; ⁴Istanbul Cerrahpaşa University, Faculty of Veterinary Medicine, Department of Anatomy, 34093, İstanbul, Turkey

*Corresponding author: modayan@selcuk.edu.tr, orhundayan@gmail.com, sedatay85@gmail.com

ARTICLE HISTORY (21-075)

Received: February 13, 2021
Revised: June 25, 2021
Accepted: August 27, 2021
Published online: September 05, 2021

Key words:

Acropodium
Gazelle
Morphometry
Phalanx
Three-dimensional modeling

ABSTRACT

The present study was conducted to identify morphometric values and to reveal differences between sexes through three-dimensional modeling of digit bones (ossa phalanges) of gazella by using computed tomography images. A total of 14 (7 female, 7 male) adult gazella (*Gazella subgutturosa*) cadavers were used in the study. The images were extracted by scanning acropodium bones of gazella at 64-detector Multi Detector Computed Tomography (MDCT) in cross section thickness of 0.625 mm. Using MIMICS 20.1 program, three-dimensional models of these images were prepared and morphometric measurements were taken. In GLpe and Bd measurements of Phalanx proximalis, a statistically significant difference was established between females and males in terms of the left forelimb internal, the right forelimb internal, the right forelimb external, and the right hindlimb external bones ($P<0.05$). There was a statistically significant difference between females and males in terms of volume of phalanx proximalis and surface area of the right forelimb internal phalanx proximalis ($P<0.001$). In GLpe measurements, a statistically significant difference was determined between females and males in terms of the left forelimb internal, the right forelimb internal, the right hindlimb internal, the left forelimb external, the right forelimb external, and the right hindlimb external phalanx media ($P<0.05$). A statistically significant difference was determined between females and males in terms of the data related to volume and surface areas of the left hindlimb internal the right hindlimb internal, the left hindlimb external, and the right hindlimb external phalanx distalis ($P<0,05$).

To Cite This Article: Demircioğlu İ, Koçyiğit A, Demiraslan Y, Yılmaz B, Ince NG, Aydoğdu S and Dayan MO, xxxx. Digit bones (acropodium) of gazella (*Gazella subgutturosa*); three-dimensional modelling and morphometry. Pak Vet J. <http://dx.doi.org/10.29261/pakvetj/2021.067>

INTRODUCTION

Gazella subgutturosa or goitered gazella is the most common species of Asian antelope spreading from eastern Turkey to the Tigris-Euphrates basin (Mallon and Kindgswood, 2001; Castelló, 2016; Khosravi *et al.*, 2018). Their population has started to decrease rapidly because of poaching, widespread agricultural areas, and unsustainable consumption of biological resources and they are included within the red list of threatened species published by the International Union for Conservation of Nature (IUCN) (IUCN, 1996; IUCN, 2008; IUCN, 2017).

Ruminants have two developed digits and each digit has three phalanxes. They are called as phalanx proximalis, phalanx media, and phalanx distalis (Bahadır and Yıldız, 2008; Bharti and Singh, 2018; König and Liebich, 2020). Phalanx proximalis is the longest one among them (Nourinezhad *et al.*, 2012; Al-Sharoot, 2013). Phalanx media is almost half of phalanx proximalis in length. Phalanx distalis looks like an irregular prism on blackbuck and blue bull (Choudhary and Singh, 2016; Bharti SK and Singh I, 2018). X-rays have been used for numerous medical imaging methods. Another medical imaging method using X-ray is computed tomography

(CT) (Kalender, 2006; Kier *et al.*, 2019). X-rays that are shot to any anatomic region reach to the detector through a certain level of absorption based on the density of tissue and the absorption difference of X-ray is calculated by detectors. By this way, two-dimensional images are extracted in Hounsfield Units (HU) by the computer. These images are commonly used in diagnosis and treatment (Ohlerth and Scharf, 1989; Kılıç, 2008; Birlik, 2015; Bulut, 2016;). Three-dimensional (3D) CT images, on the other hand, are created by reconstruction of two-dimensional images (Dugelay *et al.*, 2008; Jung *et al.*, 2015; Villarraga-Gómez *et al.*, 2019).

Morphometry is a research area examining the differences using the distance between certain points, width, angle and rates through various statistical methods (Rohlf and Marcus, 1993; Mitteroecker and Gunz, 2009; Salvagno and Albarella, 2017; Gündemir *et al.*, 2020). In terms of surgery, knowing the detailed anatomy of the region is very important in terms of both the bone and the extensor and flexor muscles adhering to the bone. It is also important in understanding the biomechanical structure of gazelles from the antelope class. That is why, this study was designed to take measurements of digit bones using computed tomography sections in gazelles, to contribute to species-specific data and the veterinary surgery field.

MATERIALS AND METHODS

A total of 14 (7 females, 7 males) adult gazelle (*Gazella subgutturosa*) cadavers were used in the study. The average age of gazelles was 2-3 years and their average weight is 20-30 kilograms. Permission for the study was obtained from the General Directorate of Nature Conservation and National Parks (Approval number: 21264211-288.04- E.1158739) and Harran University Animal Experiments Local Ethics Committee (Approval number: 2020/003/03). Gazelles' acropodium bones were scanned in a 64-detector Multi-Detector Computed Tomography (MDCT) device with a slice thickness of 0.625 mm, 80kv, 200 MA, and 639 mGY. Prokop (2003) and Kalra *et al.* (2004) were taken as references in the screening and dosing protocol. The reconstruction of the finger bones from images recorded in DICOM (Digital Imaging and Communications in Medicine) format was performed using the MIMICS 20.1 (The Materialize Group, Leuven, Belgium) software program (Bahar *et al.*, 2013; Dayan *et al.*, 2019), Morphometric measurements were based on Von den Driesch (1976).

Phalanx Proximalis (Figure 1);

1. GLpe: Greatest length of the abaxial half (GLpe)
 2. Bp: Breadth of the proximal end (Bp)
 3. SD: Smallest breadth of the diaphysis (SD)
 4. Bd: Breadth of the distal end (Bd)
- Volume (cm³)
Surface area (cm²)

Phalanx Media (Figure 2);

1. GLpe: Greatest length of the abaxial half
2. Bp: Breadth of the proximal end
3. SD: Smallest breadth of the diaphysis
4. Bd: Breadth of the distal end

5. GL: Greatest length (in dorsal direction)
Volume (cm³)
Surface area (cm²)

Phalanx Distalis (Figure 3);

1. DLS: Greatest diagonal length of the sole
 2. Ld: Length of the dorsal surface
 3. MBS: Middle breadth of the sole
- Volume (cm³)
Surface area (cm²)

After the measurements were completed, three indices ($Bp * 100 / GLpe$, $SD * 100 / GLpe$, $Bd * 100 / GLpe$) were calculated for phalanx proximalis and phalanx media, and 1 index ($MBS * 100 / DLS$) was calculated for phalanx distalis (Gündemir *et al.*, 2020). The data obtained in the study were analyzed with a statistically independent t-test according to gender and differences of limbs. For statistical analysis, SPSS 17.0 was used. Nomina Anatomica Veterinaria (2012) terminology was used in this study.

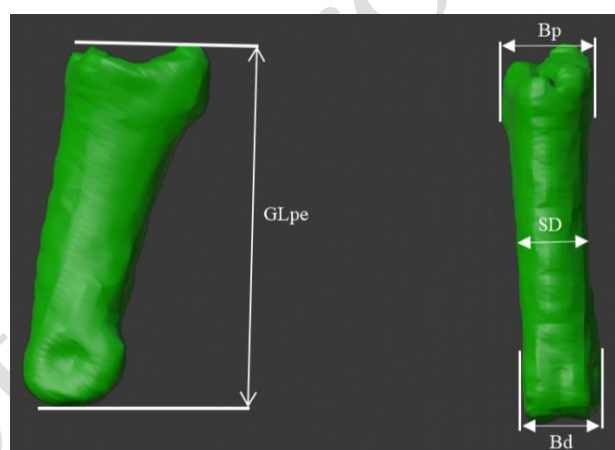


Fig. 1: 3D modelling and morphometric measurement points of Phalanx proximalis.

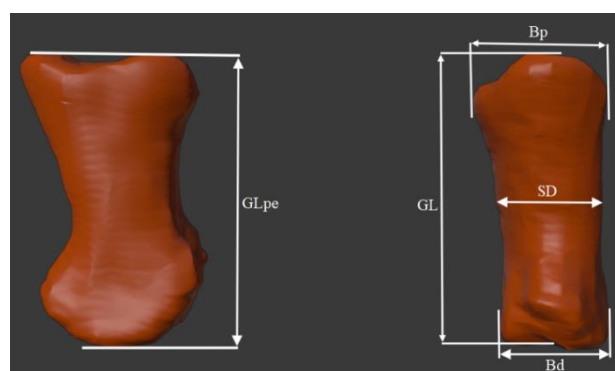


Fig. 2: 3D modelling and morphometric measurement points of Phalanx media.

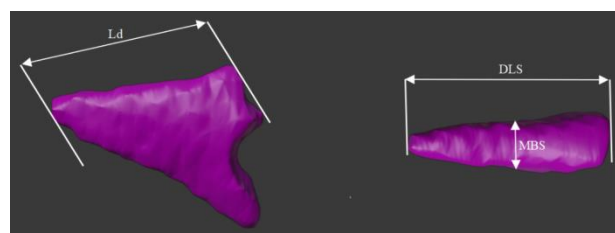


Fig. 3: 3D modelling and morphometric measurement points of Phalanx distalis.

RESULTS

Osteometric measurements of the bones were taken following a 3-dimensional modeling process was made for each bone to be examined through tomographic cross-sections. Table 1 shows osteometry of phalanx proximalis, Table 2 shows its index results, and Table 2 shows its volume and surface area values. When Table 1 was examined, GLpe and Bd measurements revealed a statistically significant difference between females and males in the left forelimb internal, the right forelimb internal, the right forelimb external, and the right hindlimb external bones ($P<0.05$) and no significant difference in the other bones ($P>0.05$). Any sexual dimorphism was not determined statistically in Bp and SD measurements and index results in Table 2. When volume and surface area values of phalanx proximalis bones in Table 2 were examined, there was a statistically significant difference between females and males in terms of volume of the right forelimb external phalanx proximalis and surface area of the right forelimb internal phalanx proximalis ($P<0.05$).

Table 1 shows osteometric measurements of phalanx media, Table 2 shows its index results and shows its volume and surface area values. When Table 1 was examined, a statistically significant difference was determined between females and males in terms of the left forelimb internal, the right forelimb internal, the right hindlimb internal, the left forelimb external, the right forelimb external, and the right hindlimb external phalanx media in GLpe measurement ($P<0.05$). Any sexual

dimorphism was not statistically detected in Bp and SD measurements. There was a statistically significant difference between females and males in terms of the left forelimb internal, the left hindlimb internal, the right hindlimb internal, and the right hindlimb external phalanx media in Bd measurement and in terms of the right hindlimb internal, the left forelimb external, and the left hindlimb external phalanx media in GL measurement ($P<0.05$). When index values in Table 2 were examined, a statistically significant sexual dimorphism was observed in $Bp*100/GLpe$ index for the left forelimb internal, the right forelimb internal, the right hindlimb internal, the left hindlimb external, and the right hindlimb external phalanx media ($P<0.05$). A statistically significant difference was determined in $Sd*100/GLpe$ index for the right hindlimb internal phalanx media ($P<0.05$). When volume and surface area values of phalanx media bones in Table 2 were examined, there was a statistically significant difference ($P<0.001$) between females and males in terms of volume value of the right hindlimb internal phalanx media and surface area of the left forelimb internal, the right hindlimb internal, and the right hindlimb external phalanx media.

Table 3 shows osteometric measurements of phalanx distalis, shows its index values and shows its volume and surface area values. As Table 3 was examined, a statistical difference was determined between females and males in terms of all phalanx distalis in Ld measurement and the left hindlimb internal and external, and the left forelimb external phalanx distalis in DLS value ($P<0.05$). There was a statistically significant difference in the left

Table 1: Osteometric measurements of Phalanx proximalis and Phalanx media

Parameter	Digit(mm)	Gender	GLpe		Bp		SD		Bd		GL	
			Mean	Std. Dev.	Mean	Std. Dev.	Mean	Std. Dev.	Mean	Std. Dev.	Mean	Std. Dev.
Phalanx proximalis	ILF	Male	37.24 ^{ab}	0.85	10.32	0.57	8.03	0.56	9.32 ^b	0.41		
		Female	35.46 ^{ab}	1.95	9.94	0.77	7.59	0.23	8.71 ^b	0.28		
	IRF	Male	37.40 ^{ab}	0.51	10.55	0.69	8.19	0.89	9.42 ^b	0.53		
		Female	35.54 ^{ab}	1.97	9.9	0.74	7.68	0.32	8.61 ^b	0.35		
	ILH	Male	32.97 ^{ab}	0.72	10.36	0.65	8.49	0.88	9.5	1.17		
		Female	31.55 ^{ab}	1.93	10.44	0.65	8.02	0.41	8.75	0.47		
	IRH	Male	33.00 ^{ab}	1.57	10.97	0.78	8.21	0.8	9.54 ^b	0.51		
		Female	31.42 ^{ab}	1.58	10.16	1.04	7.72	0.59	8.58 ^b	0.33		
	ELF	Male	37.58 ^{ab}	1.07	10.61	0.57	8.04	0.65	9.43 ^b	0.57		
		Female	35.60 ^{ab}	1.63	10.18	0.69	7.8	0.27	8.70 ^b	0.45		
	ERF	Male	37.86 ^{ab}	0.58	10.43	0.28	7.89	0.71	9.19	1		
		Female	36.47 ^{ab}	1.7	9.93	0.69	7.76	0.25	8.69	0.41		
ELH	Male	32.75 ^{ab}	2.24	10.84	0.69	7.95	0.71	9.18	0.66			
	Female	31.34 ^{ab}	1.79	10.44	0.72	7.75	0.77	8.79	0.65			
ERH	Male	33.19 ^{ab}	0.48	10.58	0.64	8.14	0.87	9.31 ^b	0.43			
	Female	31.68 ^{ab}	1.56	10.48	0.47	7.7	0.37	8.55 ^b	0.46			
Phalanx media	ILF	Male	20.49 ^b	0.81	10.8	0.81	6.91	1.16	8.23 ^b	0.57	15.11	1.06
		Female	18.71 ^b	1.08	11.23	0.65	6.27	0.42	7.38 ^b	0.4	14.08	0.79
	IRF	Male	20.80 ^b	0.94	10.69	0.98	6.71	0.92	8.19	0.72	15.08	0.56
		Female	18.85 ^b	0.67	10.74	0.94	6.28	0.36	7.38	0.82	13.82	0.85
	ILH	Male	19.91	1.28	10.91	1.07	6.75	0.6	7.98 ^b	0.5	14.95	0.96
		Female	19.07	1.22	11.11	0.42	6.49	0.23	7.48 ^b	0.25	14.67	0.92
	IRH	Male	19.98 ^b	1.18	10.7	0.85	6.54	0.41	7.99 ^b	0.37	14.89 ^b	1.14
		Female	18.31 ^b	0.65	10.53	0.78	6.91	1.03	7.37 ^b	0.32	15.18 ^b	0.65
	ELF	Male	20.36 ^b	0.7	10.68	0.88	6.88	1.11	6.82	2.73	14.78 ^b	0.89
		Female	18.53 ^b	1.28	10.82	0.5	6.12	0.38	7.31	0.61	14.02 ^b	0.83
	ERF	Male	20.63 ^b	1.04	10.8	1.17	6.77	0.89	8.08	0.8	14.97	0.67
		Female	19.15 ^b	0.68	10.85	0.69	6.50 ^a	0.26	7.67	0.71	14.18	1.04
	ELH	Male	19.99	1.26	10.82	0.85	6.66	0.42	7.96	0.29	15.53 ^b	0.78
		Female	19.02	1.01	11.03	0.54	6.53	0.36	7.46	0.26	14.72 ^b	0.62
	ERH	Male	20.20 ^b	1.42	10.88	1.2	6.73	0.52	8.05 ^b	0.45	14.78	0.78
		Female	18.29 ^b	0.61	10.47	1.19	6.54 ^a	0.36	7.53 ^b	0.28	15.01	0.52

ILF: Internal of Left Forelimb, IRF: Internal of Right Forelimb, ILH: Internal of Left Hindlimb, IRH: Internal of Right Hindlimb, ELF: External of Left Forelimb, ERF: External of Right Forelimb, ELH: External of Left Hindlimb, ERH: External of Right Hindlimb, a: There is significant difference legs ($P<0.05$), b: There is significant difference between the genders ($P<0.05$), There is a significant difference between the genders ($P<0.001$).

Table 2: Index values, volume and surface area of Phalanx proximalis and Phalanx media

Parameter	Digit(mm)	Gender	Bp*100/GLpe (mm)		Sd*100/GLpe (mm)		Bd*100/GLpe (mm)		Volume (mm ³)		Surface area (cm ²)		
			Mean	Std. Dev.	Mean	Std. Dev.	Mean	Std. Dev.	Mean	Std.Dev.	Mean	Std. Dev.	
Phalanx proximalis	ILF	Male	27.73 ^a	1.72	21.58 ^a	1.7	25.03 ^a	1.25	2.52	0.46	16.24 ^{ac}	1.06	
		Female	28.16 ^a	3.2	21.45 ^a	1.34	24.6	1.35	2.38	0.22	14.86 ^{ac}	1.57	
	IRF	Male	28.22 ^a	1.95	21.89 ^a	2.3	25.19 ^a	1.41	2.55	0.46	16.29 ^a	1.02	
		Female	27.94 ^a	2.94	21.65 ^a	1.33	24.29 ^a	1.85	2.47	0.16	14.76	1.34	
	ILH	Male	31.46 ^a	2.32	25.72 ^a	2.31	28.78 ^a	3.02	2.31	0.37	14.22 ^a	0.99	
		Female	33.17 ^a	2.63	25.46 ^a	1.43	27.74 ^a	0.87	2.18	0.28	13.22 ^a	1.34	
	IRH	Male	33.35 ^a	3.44	24.96 ^a	3.09	28.96 ^a	2.16	2.41	0.34	14.54 ^a	0.59	
		Female	32.32 ^a	2.89	24.62 ^a	1.99	27.34 ^a	0.77	2.18	0.34	14.45	1.08	
	ELF	Male	28.26 ^a	1.85	21.42 ^a	1.84	25.13 ^a	1.72	2.51	0.45	15.91	1.13	
		Female	28.34 ^a	2.45	22 ^a	1.38	24.57 ^a	1.81	2.42	0.28	14.94	1.48	
	ERF	Male	27.56 ^a	0.52	20.83 ^a	1.8	24.28 ^a	2.62	2.55 ^c	0.44	16.39	0.91	
		Female	27.98 ^a	3.06	21.74 ^a	1.32	24.47 ^a	1.75	2.44 ^c	0.17	14.82	1.57	
	ELH	Male	32.83 ^a	2.08	24.27 ^a	2.05	28.02 ^a	1.54	2.26	0.37	13.95 ^a	0.84	
		Female	33.07 ^a	2.66	24.79 ^a	2.56	28 ^a	1.54	2.23	0.30	13.09	1.07	
	ERH	Male	31.88 ^a	1.75	24.51 ^a	2.33	28.02 ^a	0.95	2.35	0.27	14.44 ^a	0.71	
		Female	33.15 ^a	2.24	24.31 ^a	0.7	27.02 ^a	1.54	2.15	0.34	14.18	1.37	
	Phalanx media	ILF	Male	52.69 ^b	3	33.78	5.85	40.18	2.65	1.09	0.22	7.47 ^c	0.69
			Female	60.21 ^b	5.28	33.62	2.77	39.49	2.11	0.92	0.11	6.50 ^c	0.92
IRF		Male	51.32 ^b	3.55	32.22	3.95	39.41	3.33	1.11	0.22	7.43	0.64	
		Female	57.05 ^b	5.07	33.35	1.75	39.08	3.47	0.97	0.12	6.61	1.12	
ILH		Male	54.9	5.14	34.11	4.39	40.3	4.43	1.01	0.16	6.79	0.51	
		Female	58.4	3.67	34.13	2.49	39.3	1.66	0.87	0.11	6.27	0.79	
IRH		Male	53.53 ^b	2.04	32.79 ^b	2.4	40.14	3.72	1.02 ^c	0.11	6.84 ^c	0.52	
		Female	57.49 ^b	3.09	37.69 ^b	4.78	40.25	0.77	0.87 ^c	0.10	6.11 ^c	0.75	
ELF		Male	51.59	3.82	33.42	5.18	33.51	13.4	1.08	0.23	7.46	0.79	
		Female	58.55	3.84	33.15	2.75	39.43	1.45	0.89	0.15	6.49	1.05	
ERF		Male	52.3	4.11	32.84	4.1	39.26	4.21	1.10	0.21	7.43	0.71	
		Female	56.67	3.51	33.97	2.1	40.08	3.67	1.00	0.12	6.68	1.07	
ELH		Male	54.16 ^b	2.9	33.46	3.36	40.03	3.74	1.02	0.15	6.92	0.41	
		Female	58.06 ^b	3.42	34.38	2.38	39.25	1.57	0.88	0.11	6.36	0.89	
ERH		Male	53.88 ^b	4.63	33.48	3.86	40.04	4.06	1.03	0.11	6.94 ^c	0.57	
		Female	57.16 ^b	5.3	35.76	1.71	41.2	1.28	0.87	0.10	6.12 ^c	0.63	

Table 3: Osteometric measurements, index values, volume and surface area of Phalanx distalis

Parameter	Digit	Gender	LD (mm)		DLS (mm)		MBS (mm)		MBS*100/DLS (mm)		Volume (cm ³)		Surface area (cm ²)	
			Mean	Std. Dev.	Mean	Std. Dev.	Mean	Std. Dev.	Mean	Std. Dev.	Mean	Std. Dev.	Mean	Std. Dev.
Phalanx distalis	ILF	Male	19.38 ^b	1.36	23.25	1.9	4.94	0.57	21.22 ^b	1.57	0.82	0.22	6.24	0.66
		Female	17.12 ^b	1.62	21.57	1.58	5.22	0.39	24.30 ^b	2.7	0.69	0.17	5.47	0.85
	IRF	Male	19.15 ^b	1.14	23.27	2.12	5.17	0.89	22.15	2.4	0.84	0.28	6.37	0.89
		Female	17.36 ^b	1.64	22.01	1.53	5.15	0.38	23.5	2.37	0.78 ^a	0.17	5.77 ^a	0.64
	ILH	Male	18.81 ^b	1.15	22.62 ^b	1.63	5.25	0.5	23.24	1.73	0.81 ^c	0.18	5.86 ^c	0.72
		Female	16.53 ^b	1.44	20.12 ^b	1.3	5.17	0.55	25.78	3.04	0.64 ^c	0.09	4.96 ^c	0.67
	IRH	Male	18.58 ^b	1.29	22.42	1.35	5.02	0.68	22.35	2.47	0.85 ^c	0.17	5.85 ^{ac}	0.68
		Female	17.02 ^b	1.03	21.17	1.37	5.02	0.35	23.75	1.92	0.63 ^{ac}	0.08	4.98 ^c	0.56
	ELF	Male	19.27 ^b	1.28	23.04 ^b	1.74	5.05	0.75	21.91	2.59	0.80	0.22	6.13	0.75
		Female	17.84 ^b	1.08	20.56 ^b	0.83	4.95	0.33	24.08	1.28	0.70	0.16	5.42 ^a	0.73
	ERF	Male	19.44 ^b	1.27	23.3	2.14	5.25	0.84	22.45	2.11	0.82	0.19	6.19	0.58
		Female	18.01 ^b	1.11	21.97	1.53	5.14	0.38	23.47	2.05	0.78 ^a	0.18	5.81 ^a	0.82
	ELH	Male	18.68 ^b	1.03	22.19 ^b	1.74	5.17	0.45	23.36	2.18	0.80 ^c	0.16	5.79 ^c	0.64
		Female	16.76 ^b	1.38	20.02 ^b	1.15	5.06	0.44	25.34	2.43	0.61 ^c	0.08	4.78 ^{ac}	0.63
	ERH	Male	18.52 ^b	1.43	21.86	1.56	5.33	0.66	24.36	2.45	0.84 ^c	0.14	5.87 ^c	0.57
		Female	16.91 ^b	0.76	20.97	1.41	4.97	0.42	23.81	2.67	0.63 ^{ac}	0.07	5.01 ^{ac}	0.53

ILF: Internal of Left Forelimb, IRF: Internal of Right Forelimb, ILH: Internal of Left Hindlimb, IRH: Internal of Right Hindlimb, ELF: External of Left Forelimb, ERF: External of Right Forelimb, ELH: External of Left Hindlimb, ERH: External of Right Hindlimb, a: There is significant difference legs (P<0.05), b: There is significant difference between the genders (P<0.05), There is a significant difference between the genders (P<0.001).

forelimb internal phalanx distalis in MBS*100/DLS index value of phalanx distalis (P<0.05). Upon examination of volume and surface area data of the left hindlimb internal, the right hindlimb internal, the left hindlimb external and right hindlimb external phalanx distalis, a statistically significant difference was detected between female and male (P<0.05).

DISCUSSION

The present study morphometrically analyzed digit bones of gazella in terms of sex and direction factors through images extracted from computed tomography. As

stated in the studies on *Antelope cervicapra* (Choudhary and Singh, 2016), goat (Makungu and Merere, 2017) and blue bulls (Bharti and Singh, 2018) forelimb and hindlimb of phalanx proximalis were observed to be the longest bone among all phalanxes in the present study as well (Choudhary and Singh, 2016; Makungu and Merere, 2017; Bharti and Singh, 2018). Previous research reported that there was no statistical difference between the right and left phalanxes in cattle and water buffaloes (Ocal *et al.*, 2004; Nourinezhad *et al.*, 2012). Results of the present study support these studies. In the study by Peters (1989) it was highlighted that phalanx proximalis was thinner in the forelimb of gazella. However, this was not found in

the present study. In contrast to Gündemir *et al.* (2020) and Ocal *et al.* (2004). GLpe measurement of phalanx proximalis was higher in forelimbs than hindlimbs. It might be thought that this situation developed in order to spend less energy and escape from predators (Taylor *et al.*, 1974; Sorkin 2008). In the study conducted by Nourinezhad *et al.* (2012) on buffalos, the breadth of the distal end (Bd) of phalanx proximalis was reported to have a statistically significant difference. In the present study, the same measurement in females and males was found to be statistically significant ($P < 0.05$). Length (GLpe) and breadth (Bp) of phalanx media were indicated to be 1.88 ± 0.03 cm and 0.94 ± 0.05 cm, respectively, in the measurements on Black Bengal goats carried out by Siddiqui *et al.* (2008). The same parameters were found to be 1.95 ± 5.59 cm and 10.82 ± 4.38 cm, respectively in the present study. GL, SD, and Bp values of phalanx media were reported to be statistically significant in the studies on water buffaloes by Nourinezhad *et al.* (2012) and on domestic cattle by Gündemir *et al.* (2020). It was found in the present study that only SD value was statistically significant regardless of sex (Nourinezhad *et al.* 2012., Nourinezhad *et al.*, 2015). GLpe parameter was significant for all limbs other than the left hindlimb phalanx media based on sexual dimorphism ($P < 0.05$). Gündemir *et al.* (2020) calculated that LD and DLS measurements of phalanx distalis were higher in forelimbs and reported no statistical difference. The present study revealed that LD value was significant ($P < 0.05$) in all bones in terms of sexual dimorphism. DLS parameter was statistically significant between the left hindlimb and the left forelimb external bones in terms of sexual dimorphism ($P < 0.05$). In the present study, digit bones of gazella that are under the risk of extinction were analyzed via classical morphometric methods using 3D images. Besides, data obtained based on sex and direction criteria were compared statistically.

Conclusions: Consequently, the results of the study are considered to be useful for Ruminantia taxonomy and zooarcheological surveys of the species. Besides, it is also thought that these results obtained in the study can be used for comparison in degenerations and regeneration that may occur in the digit bones. As a result of the study, it was observed that mean values of the bones had a statistically significant difference in terms of both sexes and direction. Considering the compact texture of ossa phalanges, it can be predicted that it cannot be consumed easily by carnivore animals. Also, it is likely to assert that these bones are highly limited for human consumption. Therefore, it would be correct to state that ossa phalanges has a structure allowing the maintenance of these characteristics under the earth for long years due to its strong structure indicating characteristics of the species. This study made a morphometric analysis of the finger bones of gazelle with 3D models created using two-dimensional images of computed tomography and it is thought to contribute to studies in this field and it is thought that it will contribute to the studies in the field.

Author contribution: MOD and SA designed this study objectives. İD and AK prepared three-dimensional models and obtained measurements from anatomical points. BY

analyzed the data and NGİ and YD wrote the manuscript. All authors accomplished critical corrections to the final version of the article.

REFERENCES

- Al-Sharoot HA, 2013. Anatomical Study of the Digits of Fore limbs in goat. QIVMS 12:28-35.
- Bahadır A and Yıldız H, 2008. Veteriner Anatomi: Hareket Sistemi & İç Organlar. Ezgi Bookselling, Bursa, Turkey. pp:14-180.
- Bahar S, Bolat D, Dayan MO, *et al.*, 2013. Two-and three-dimensional anatomy of paranasal sinuses in Arabian foals. J Vet Med Sci 76:37-44.
- Bharti SK and Singh I, 2018. Morphological and Morphometrical studies on the phalanges and sesamoid bones of blue bull (*Boselaphus tragocamelus*). In, International Conference on Food Security and Sustainable Agriculture, Thailand. pp:81-5.
- Birlik İ, 2015. Medical imaging methods and photo relationship. Dokuz Eylül University, Institute of Fine Arts, MSc Thesis İzmir, Turkey.
- Bulut B, 2019. Computed tomographic examination of the upper respiratory tract and trachea in brahiocephalic dogs. Aydın Adnan Menderes University, Institute of Health Sciences, MSc Thesis Aydın, Turkey.
- Castelló JR, 2016. Bovids of the world: antelopes, gazelles, cattle, goats, sheep, and relatives (Vol. 104). Princeton University Press, New Jersey, USA.
- Choudhary OP and Singh I, 2016. Gross and Morphometrical Studies on Phalanges and Sesamoid Bones of Indian Blackbuck (*Antelope cervicapra*). J Wildlife Res 4:01-05.
- Dayan MO, Beşoluk K, Eken E, *et al.*, 2019. Three-dimensional modelling of the femur and humerus in adult male guinea pigs (guinea pig) with computed tomography and some biometric measurement values. Folia Morphol 78:588-94.
- Dugelay JL, Baskurt A and Daoudi M, 2008. 3D object processing: compression, indexing and watermarking. John Wiley & Sons, England.
- Gündemir O, Özkan E, and Mutuş R, 2020. Morphometric study on the digital bones in the domestic cattle. Kafkas Univ Vet Fak Derg 26:75-82.
- IUCN, 2008. IUCN Red List of Threatened Species 2008. www.iucnredlist.org (Last accessed on 18 July 2020).
- IUCN, 2017. IUCN SSC Antelope Specialist Group. *Gazella subgutturosa*. The IUCN Red List of Threatened Species. <http://dx.doi.org/10.2305/IUCN.UK.2017-2.RLTS.T8976A50187422.en> (Last accessed on 27 August 2020).
- IUCN, 1996. Red List of threatened animals. IUCN, Gland, Switzerland and Cambridge, UK.
- Jung J, Cho Y, Jung Y, *et al.* 2015. Diagnosis and treatment of an aberrant right subclavian artery with persistent right ligamentum arteriosum in a kitten. Pak Vet J 35:119-22.
- Kalender WA, 2006. X-ray computed tomography. Phys Med Biol 51:29-43.
- Kalra MK, Maher MM, Toth TL, *et al.* 2004. Strategies for CT radiation dose optimization. Radiology 230:619-28.
- Khosravi R, Hemami MR, Malekian M, *et al.*, 2018. Effect of landscape features on genetic structure of the goitered gazelle (*Gazella subgutturosa*) in Central Iran. Conserv Genet 19:323-36.
- Kılıç N, 2008. Colonic polyp detection using three-dimensional templates in computed tomography images. İstanbul University, Institute of Health Sciences, PhD Thesis İstanbul, Turkey.
- Kier EL, Conlogue GJ and Zhuang Z, 2019. High-Resolution Computed Tomography Imaging of the Cranial Arterial System and Rete Mirabile of the Cat (*Felis catus*). Anat Rec 302:1958-67.
- König HE and Liebich HG, 2020. Veterinary anatomy of domestic animals: Textbook and colour atlas. Georg Thieme Verlag, New York, USA.
- Makungu M and Merere B, 2017. Morphology of the thoracic limb of goat as evidenced by gross osteology and radiology. Anat Histol Embryol 46:509-18.
- Mallon D and Kingwood SC, 2001. Antelope Part 4: North Africa, the Middle East, and Asia. Global Survey and Regional Action Plans. SSC Antelope Specialist Group. IUCN, Gland, Switzerland and Cambridge, UK.
- Mitteroecker P and Gunz P, 2009. Advances in geometric morphometrics. Evol Biol 36:235-47.

- Nomina Anatomica Veterinaria, 2017. Nomina Anatomica Veterinaria. 6th ed. World Association of Veterinary Anatomist, New York pp:1-178.
- Nourinezhad J and Mazaheri Y, Pourmahdi BM, et al., 2012. Morphometric study on digital bones in native Khuzestan Water Buffaloes (*Bubalus bubalis*). Bulg J Vet Med 15:228-35.
- Nourinezhad J, Mazaheri Y and Ahi MR, 2015. Metrical analysis of dromedary digital bones. Anat Sci Int 90:113-22.
- Ocal MK, Sevil F and Parin, 2004. A quantitative study on the digital bones of cattle. Ann Anat 186: 165-168.
- Ohlerth S and Scharf. 2007. Computed tomography in small animals– Basic principles and state of the art applications. Vet J 173:254-71.
- Peters J, 1989. Osteomorphological features of the appendicular skeleton of gazelles, genus *Gazella Blainville* 1816, bohor reedbuck, *redunca redunca* (Pallas, 1767) and bushbuck. *Tragelaphus scriptus* (Pallas, 1766). Anat Histol Embryol 18:97-113.
- Prokop M, 2003. General principles of MDCT. Eur J Radiol 45:4-10.
- Rohlf FJ and Marcus LF, 1993. A revolution morphometrics. Trends ecol evol 8:129-32.
- Salvagno L and Albarella U, 2017. A morphometric system to distinguish sheep and goat postcranial bones. PLoS One 12:1-37.
- Siddiqui MSI, Khan MZI, Moonmoon S, et al., 2008. Macro-anatomy of the bones of the forelimb of Black Bengal goat (*Capra hircus*). Bangladesh J Vet Med 6:59-66.
- Sorkin B, 2008. Limb bone stresses during fast locomotion in the African lion and its bovid prey. J Zool 276:213-8.
- Taylor C, Shkolnik A, Dmi'el R, et al., 1974. Running in cheetahs, gazelles, and goats: energy cost and limb configuration. Am J Physiol 247:848-50.
- Villarraga-Gómez H, Herazo EL and Smith ST, 2019. X-ray computed tomography: from medical imaging to dimensional metrology. Precis Eng 60:544-69.
- Von den Driesch A, 1976. A guide to the measurement of animal bones from archaeological sites. Peabody Museum of Archaeology and Ethnology, Harvard University, Cambridge, Mass, USA.