



RESEARCH ARTICLE

Effect of Low-dose Indole-3-Butyric Acid on Hematological and Serum Biochemical Parameters against Thioacetamide-Induced Acute Hepatotoxicity in Rats

Maab Ahmed Abdalrhman Ahmed^{1#}, Gareeballah Osman Adam^{1,2#}, Dong Kwon Yang¹, Tsendsuren Tungalag¹, Sei-Jin Lee³, Hyung-Sub Kang¹, Jin-Shang Kim^{1*} and Shang-Jin Kim^{1*}

¹Department of Veterinary Pharmacology & Toxicology, College of Veterinary Medicine, Jeonbuk National University, Specialized Campus, 79 Gobong-ro, Iksan-si, Jeollabuk-do 54596, Republic of Korea

²Department of Veterinary Medicine and Surgery, College of Veterinary Medicine, Sudan University of Science and Technology, P.O. Box No. 204, Hilat Kuku, Khartoum, Sudan

³Korea Basic Science Institute Jeonju Center, Jeonju 54896, Republic of Korea.

*Corresponding author: kimjs@jbnu.ac.kr (JS Kim), abbasj@jbnu.ac.kr (SJ Kim)

ARTICLE HISTORY (22-016)

Received: March 2, 2022
Revised: October 11, 2022
Accepted: October 16, 2022
Published online: November 10, 2022

Key words:

Indole-3-Butyric Acid
Acute Hepatotoxicity
Thioacetamide
Oxidative damage

ABSTRACT

Although indole-3-butyric acid (IBA) is an efficient growth regulator in plant and its toxicity of high-dose (500 mg/kg) have been repeatedly demonstrated against non-targeting organisms including human and animals, there have been not previously published very low-dose study on animals. So, we designed this study to uncover the effects of very low-dose (15-60 µg/kg) of IBA on the thioacetamide (TAA)-induced acute hepatotoxicity in rat models. The pretreatment of IBA (60 µg/kg) was found to prevent the TAA-induced body weight loss and dehydration as well as histopathological injuries. The administration of TAA induced metabolic acidosis (decreases in blood pH, bicarbonate, base excess in blood and base excess in extracellular fluid), respiratory acidosis (decreases in saturated oxygen and partial pressure of oxygen; increase in partial pressure of carbon dioxide), fluctuations in blood energy-related enzymes (increases in ALT, AST and LDH) and metabolites (decreases in albumin, glucose, total protein, but increases in triglycerides and total cholesterol) and changes in blood ions (decreased calcium but increased magnesium). Also, the pretreatment of IBA prevented the TAA-induced changes gradually in a dose-dependent manner, especially inhibited the changes at 60 µg/kg. In conclusion, this study demonstrated that the low-dose IBA treatment may have the therapeutic effect against acute hepatic injuries via protective pathways against metabolic disorders, acidosis, membrane permeability fluctuations, ionic imbalance and tissue damage caused by oxidative damage caused by TAA.

To Cite This Article: Ahmed MAA, Adam GO, Yang DK, Tungalag T, Lee S-J, Kang H-S, Kim J-S and Kim S-J, 2022. Effect of low-dose indole-3-butyric acid on hematological and serum biochemical parameters against thioacetamide-induced acute hepatotoxicity in rats. Pak Vet J. <http://dx.doi.org/10.29261/pakvetj/2022.079>

INTRODUCTION

The liver acts as the main metabolic organ while maintaining homeostasis, the liver is the first line to deal with xenobiotics, which cause serious disorders and the development of several pathological conditions (Iorga and Dara, 2019). Liver injury is the main cause of morbidity and mortality with significant economic and social costs (Moon *et al.*, 2020). Liver injury following the intake of such agents may be subclinical and reversible but may also cause death because of acute hepatotoxicity (Dong *et al.*, 2020). Thioacetamide (TAA) is widely used to induce acute liver toxicity in rats (Akhtar and Sheikh, 2013), metabolically activated to sulfine and further to sulfene,

which covalently bind to hepatic macromolecules, leading to cellular damage and hepatocyte necrosis (Sepehrinezhad *et al.*, 2021). In rats, administration of TAA results to acute or chronic hepatotoxicity, depending on dose and duration of administration (Sepehrinezhad *et al.*, 2021).

Indole-3-butyric acid (IBA) as one of the indole derivatives and auxin is a phytohormone for plant growth and developmental processes (Chinapolaiah *et al.*, 2019; Zhang *et al.*, 2000) and has been used as an exogenous plant growth regulator (Small and Degenhardt, 2018). IBA's toxicities of high-dose (500 mg/kg) have been repeatedly demonstrated against non-targeting organisms including human and animals (Tudi *et al.*, 2022). Butyric acid, *per se*, stimulates rumen mucosa development in the

calf mainly by a reduction of apoptosis and an increased mitotic rate (Mentschel *et al.*, 2001). Interestingly, there are some studies about beneficial effects like as enhancement of antioxidant defense systems after sub-acute and sub-chronic low-dose (4-5 mg/kg) exposure in rat (Topalca *et al.*, 2009). So, we designed this study to uncover the effects of very low-dose (15-60 µg/kg) of IBA on the TAA-induced acute hepatotoxicity in rat models.

MATERIALS AND METHODS

Chemicals: TAA and IBA were purchased from Sigma (St. Louis,). TAA was suspended in distilled water. IBA was dissolved in 1 mL NaOH and then was diluted with distilled water (Topalca *et al.*, 2009).

Animal Experiments: All experimental protocols were approved by the Committee on the Care of Laboratory Animal Resources, Jeonbuk National University. Total 36 male Sprague-Dawley rats (185–210 g; Koatech, Gyeonggi, Korea) were employed in this study. The rats were provided with standard commercial rat chow and were allowed to access tap water freely during the experiment period. The rats were kept in an environment maintained at 23±2 °C with a relative humidity of 50±2 % and a 12-h light/dark and allowed to acclimatize at least one week before starting (Lee *et al.*, 2017). Animals were randomly divided into six groups (n = 6) as follow: Control group, received distilled water only for 17 consecutive days; IBA-only group, received orally IBA (60 µg/kg BW) for 17 consecutive days; TAA group, single intraperitoneally injection (350 mg/kg) on the 14th day; IBA 15 group, received orally IBA (15 µg/kg BW) for 17 days consecutively + TAA (350 mg/kg BW) on the 14th day; IBA 30 group, received IBA (30 µg/kg BW) orally for 17 days consecutively + TAA (350 mg/kg BW) on the 14th day; IBA 60 group, received IBA (60 µg/kg BW) orally for 17 days consecutively + TAA (350 mg/kg BW) on the 14th day. After 3 days of TAA treatment, all animals were sacrificed under general anesthesia by inhalant isoflurane (Deckardt *et al.*, 2007).

Determination of Plasma and Blood Parameters: Blood sampling and measurement of parameters were modified from previously methods (Lee *et al.*, 2017). Blood samples from the caudal vena cava were collected in lithium heparin-containing tubes. Plasma samples were collected by centrifugation of whole blood samples at 3000 rpm for 10 min and stored at -20 °C for further studies. Blood glucose, triglyceride (TG), total cholesterol (T-CHO), albumin (Alb), total protein (T-PRO), ALT, AST, LDH, total magnesium (tMg) and total calcium concentrations (tCa) were analyzed using Hitachi 7020 auto-analyzer (Hitachi, Tokyo, Japan). Blood concentrations of hemoglobin (Hb), hematocrit (Hct), saturated oxygen (SO₂), partial pressure of oxygen (pO₂), partial pressure of carbon dioxide (pCO₂), free-ionized magnesium (Mg²⁺), free-ionized calcium (Ca²⁺), pH, bicarbonate (HCO₃⁻), base excess in blood (BE-b) and base excess in extracellular fluid (BE-ecf) were measured by Nova Stat Profile® pHox Ultra (Nova Biomedical, Waltham, MA, USA).

Histopathological Examination: The sections of liver tissues was prepared as described previously (Shen *et al.*,

2018). Liver tissue specimens for the histopathological evaluation were processed in a 10% formalin solution for 48 h. For histological staining, sections with 4 µm of thickness were taken from each paraffin block. The sections placed onto the normal slide were stained with hematoxylin-eosin (H&E). The necro-inflammatory score (0–4) was assessed according to Scheuer's classification: Score 0, no necroinflammation; score 1, inflammation without necrosis; score 2, mild necroinflammation; score 3, moderate necroinflammation; score 4, severe necroinflammation (Shen *et al.*, 2018).

Statistical Analysis: All results were analyzed by using Student's *t*-test, Kruskal-Wallis test, one-way analysis of variance (ANOVA) with Bonferroni *post-hoc* analysis or two-way ANOVA, as appropriate, using Prism 8.02 (GraphPad Software Inc., San Diego, CA, USA). Data are expressed as mean±standard error of the mean (SEM). P<0.05 was considered statistically significant.

RESULTS

IBA Prevents the TAA-induced Changes in Body Weight: IBA only group (60 µg/kg) led to no significant change in body weight throughout all period of experiment compared with control group, as shown in Table 1. TAA led to significant reduction in body weight at 3 days after treatment compared with control group, but the TAA-induced weight loss tend to decrease with the pretreatment of IBA (0, 15, 30 and 60 µg/kg) in a dose-dependent manner.

IBA Prevents the TAA-induced Histopathological Injury of Hepatic Parenchyma: As shown in Fig. 1A, liver sections in control and IBA only group exhibited normal architecture of liver lobules and hepatocytes around the central veins. Regarding the examined liver section of TAA-treated rat, it revealed marked centrilobular and periportal necrosis as well as congestion of the hepatic blood vessels, inflammatory cell infiltration and hydropic degeneration. However, the pretreatment of IBA prevented the TAA-induced histopathological injury gradually in a dose-dependent manner. In Fig. 1B, necro-inflammatory score (0–4) was assessed according to Scheuer's classification (Shen *et al.*, 2018): Score 0, no necroinflammation; score 1, inflammation without necrosis; score 2, mild necroinflammation; score 3, moderate necroinflammation; score 4, severe necroinflammation.

IBA Attenuates the TAA-induced blood enzymes related to Hepatic Toxicities: The results of enzymatic activities related to hepatic toxicities are shown in Fig. 2. After the administration of TAA, there were significantly (p<0.001) increases in ALT, AST and LDH, but a significant reduction in Alb compared to those of control. However, the pretreatment of IBA attenuated the TAA-induced changes in ALT, AST, LDH and Alb in a dose-dependent manner.

IBA Preserves the TAA-induced Changes in Hematological Parameter and Blood Gases: In IBA only group, there were no significant changes in Hb, Hct, SO₂, pO₂, tCO₂ and pCO₂ (Table 2). The levels of Hb, Hct and pCO₂

Table 1: Effects of TAA and/or IBA treatment on body weight

	Cont	IBA 60 μ g	TAA 350 mg/kg			
			IBA 0	IBA 15	IBA 30	IBA 60
Day 1	198.3 \pm 2.8	197.5 \pm 2.8	193.5 \pm 2.1	196.7 \pm 1.8	192.5 \pm 1.8	194.2 \pm 1.2
Day 14 (TAA inj.)	288.0 \pm 1.0	289.5 \pm 1.1	284.6 \pm 3.3	289.2 \pm 3.6	293.5 \pm 4.5	297.8 \pm 5.7
Day 17 (Sacrifice)	300.0 \pm 1.7	302.3 \pm 2.0	255.0 \pm 4.7 ^{***}	252.8 \pm 4.8	273.3 \pm 5.3 ^{##}	285.3 \pm 5.1 ^{####}

Cont indicates control. Data are represented as the mean \pm SEM (n=6). ^{***}: P<0.001, two-way ANOVA for TAA treatment vs. control group. #: P<0.05 and ^{###}: P<0.001, two-way ANOVA for IBA treatment vs. TAA group (IBA 0).

Table 2: Effects of TAA and/or IBA on hemodynamic parameters and blood gases.

	Cont	IBA 60 μ g	TAA 350 mg/kg			
			IBA 0	IBA 15	IBA 30	IBA 60
Hb (g/dl)	13.7 \pm 0.3	13.8 \pm 0.1	15.1 \pm 0.3 [*]	14.6 \pm 0.3	15.0 \pm 0.1	13.5 \pm 0.3 ^{##}
Hct (%)	39 \pm 1	41 \pm 0	45 \pm 1 ^{***}	44 \pm 1	45 \pm 0	43 \pm 1 [#]
SO ₂ (mmHg)	83.8 \pm 1.6	81.9 \pm 4.2	61.4 \pm 2.1 ^{***}	71.7 \pm 3.9	73.4 \pm 1.9	79.0 \pm 2.3 ^{##}
pO ₂ (mmHg)	64.6 \pm 2.7	57.6 \pm 2.7	40.6 \pm 2.0 ^{***}	40.6 \pm 0.77	46.8 \pm 0.80	52.0 \pm 0.63 ^{##}
pCO ₂ (mmHg)	45.3 \pm 1.2	45.8 \pm 1.0	54.4 \pm 2.6 [*]	51.7 \pm 1.9	49.8 \pm 1.6	46.3 \pm 1.5 [#]

SO₂, saturated oxygen; pO₂, partial pressure of oxygen; pCO₂, partial pressure of carbon dioxide. Data are reported as the mean \pm SEM (n=6). ^{*}: P<0.05 and ^{***}: P<0.001, Student's t-test vs. control group. #: P<0.05 and ^{###}: P<0.001, one-way ANOVA with Bonferroni's *post hoc* test vs. TAA group (IBA 0).

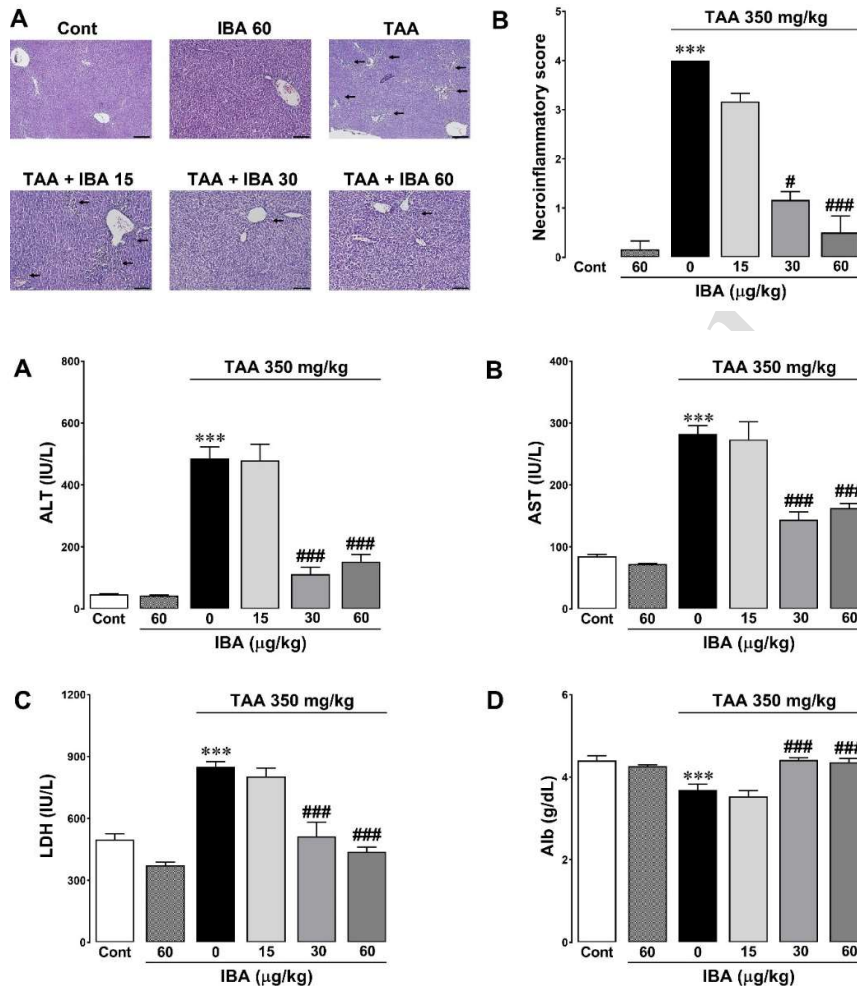


Fig. 1: Effect of IBA on TAA-induced histopathological injury. (A) H&E-stained liver sections, black arrow indicate the necroinflammatory area. Scale bars (black line) indicate 50 μ m. (B) Necroinflammatory score according to Scheuer's classification. The data are reported as the mean \pm SEM (n=6). ^{***}: P<0.001, Kruskal-Wallis's test vs control (Cont); #: P<0.05 and ^{###}: P<0.001, Kruskal-Wallis's test vs. TAA group (IBA 0).

Fig. 2: Effects of TAA and/or IBA on blood enzymes and albumin. (A) ALT, (B) AST, (C) LDH and (D) Alb: albumin. Data are reported as the mean \pm SEM (n=6). ^{***}: P<0.001, Student's t-test vs. control group. ^{###}: P<0.001, one-way ANOVA with Bonferroni's *post hoc* test vs. TAA group (IBA 0).

were significantly higher after TAA treatment. In contrast, the levels of SO₂ and pO₂ were significantly lower after TAA treatment. The pretreatment of IBA inhibited the TAA-induced changes in a dose-dependent manner.

IBA Suppress the TAA-induced Blood Acidosis: To explore the effect of IBA on blood acidosis after TAA administration, the levels of pH, HCO₃⁻, BE-b and BE-ecf were measured. As represented in Fig. 3, the levels of pH and HCO₃⁻ were significantly decreased in the TAA group.

In contrast, TAA significantly increased the levels of BE-b and BE-ecf, compared to those of the control. However, the pretreatment of IBA suppressed the TAA-induced blood acidosis in a dose-dependent manner.

IBA Attenuates the TAA-induced Changes in Plasma Biomarkers Related to Energy metabolism: To estimate the effect of IBA and/or TAA on energy metabolism, glucose, TG, T-CHO and T-PRO were measured (Fig. 4). TAA significantly decrease glucose and T-PRO,

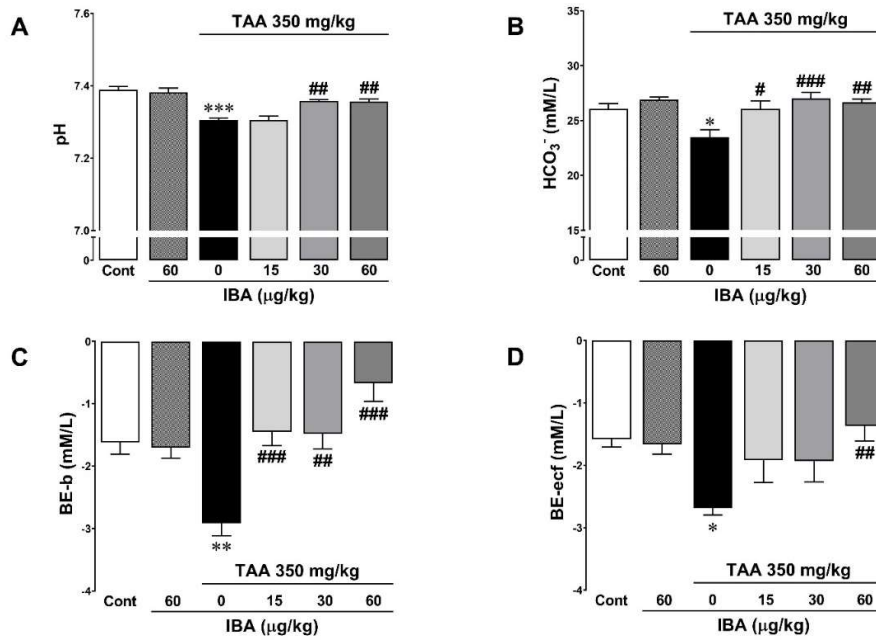


Fig. 3: Effects of TAA and/or IBA on blood pH. (A) pH, (B) HCO₃⁻: bicarbonate, (C) BE-b: base excess in blood and (D) BE-ecf: base excess in extracellular fluid. Data are reported as the mean±SEM (n=6). ***: P<0.001, Student's t-test vs. control group. ##: P<0.01 and ###: P<0.001, one-way ANOVA with Bonferroni's post hoc test vs. TAA group (IBA 0).

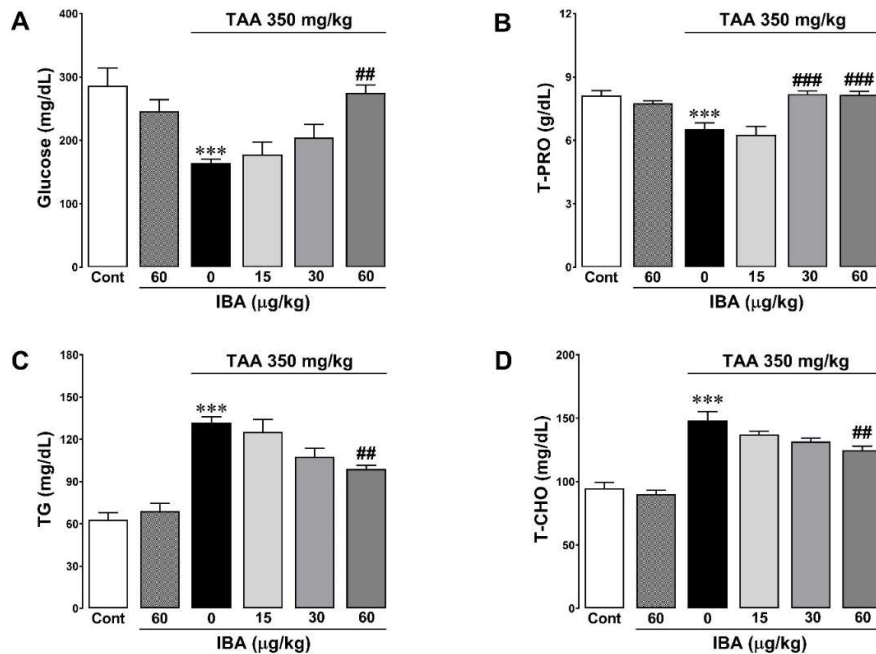


Fig. 4: Effects of TAA and/or IBA on blood metabolites related to energy metabolism. (A) glucose, (B) T-PRO: total protein, (C) TG: triglycerides and (D) T-CHO: total cholesterol. Data are reported as the mean±SEM (n=6). ***: P<0.001, Student's t-test vs. control group. ##: P<0.01 and ###: P<0.001, one-way ANOVA with Bonferroni's post hoc test vs. TAA group (IBA 0).

compared with the control group (from 286.6 to 164.1 mg/dL and 8.1 to 6.5 g/dL, respectively). The levels of TG and T-CHO (from 62.8 to 131.8 mg/dL and 94.8 to 148.3 mg/dL, respectively). The TAA-induced changes in energy metabolism-related plasma biomarkers were attenuated after the pretreatment of IBA in a dose-dependent manner.

IBA Ameliorates the TAA-induced Changes in Blood Mg²⁺ and Ca²⁺: As shown in Fig. 5, blood Mg²⁺ and Ca²⁺ were not changes after treatment of IBA, *per se*. After treatment of TAA, the values of blood Mg²⁺ and *t*Mg tended to increase while the values of blood Ca²⁺ and *t*Ca were decreased significantly, compared with those of control. The pretreatment of IBA ameliorated the TAA-induced hypermagnesemia and hypocalcemia in a dose-dependent manner.

DISCUSSION

Acute liver failure can very rapidly cause various organ failure and death (Dong *et al.*, 2020). Despite advances in new treatment modalities and intensive care, the mortality rate of acute liver injury is still high, and liver transplantation is the only effective method (Brown *et al.*, 2018). The most common cause of acute liver failure is chemical (including medicine)-induced liver injury in western region such as Australia, the United Kingdom, and the United States, while viral hepatitis is the predominant cause in Asia and Africa (Brown *et al.*, 2018). TAA is one of hepatotoxicant used to induce the chemical-induced acute or chronic liver failure in animal model (Akhtar and Sheikh, 2013). The hepatotoxicity of TAA used as an antifungal agent in plants was first reported in 1948 in rats.

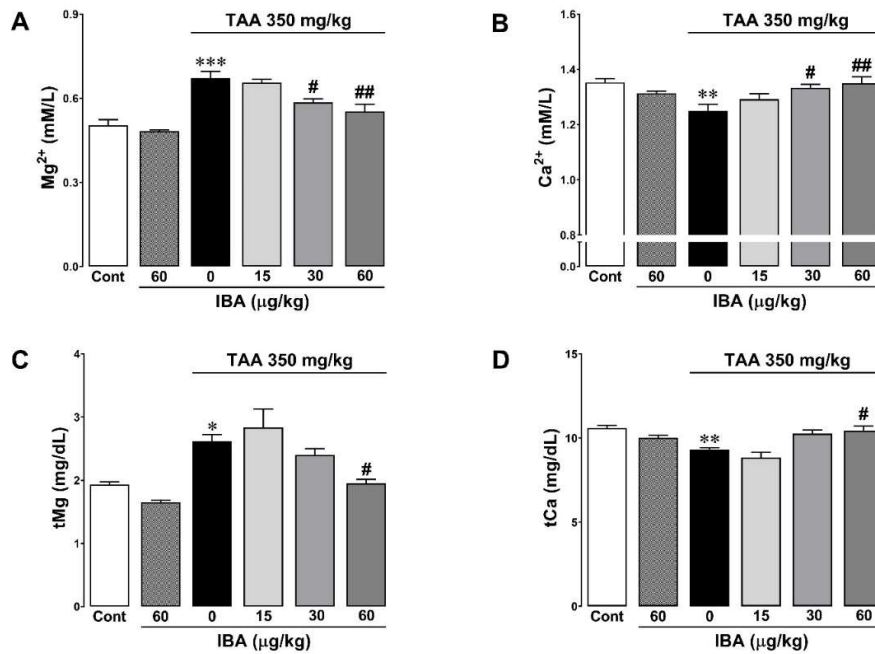


Fig. 5: Effects of TAA and/or IBA on blood magnesium and calcium. (A) iMg^{2+} : Free-ionized magnesium, (B) iCa^{2+} : free-ionized calcium, (C) tMg: total magnesium and (D) tCa: total calcium concentrations. Data are reported as the mean \pm SEM (n=6). *: P<0.05, **: P<0.01 and ***: P<0.001, Student's t-test vs. control group. #: P<0.05 and ##: P<0.01, one-way ANOVA with Bonferroni's *post hoc* test vs. TAA group (IBA 0).

(Fitzhugh and Nelson, 1948). TAA as an intrinsic hepatotoxicant, induces a dose- and time-dependent liver failure pattern, reliably and predictably (Sepehrinezhad *et al.*, 2021). To induce acute liver failure, high doses single injection of TAA must be administrated according to guideline of the International Society for Hepatic Encephalopathy and Nitrogen Metabolism as a well-characterized model of acute liver failure, while low dose repeated chronic administration causes cirrhosis and hepatic tumor (Sepehrinezhad *et al.*, 2021). In this study, we demonstrated that the high dose of TAA administration induced the acute liver failure with inflammatory infiltration, hydropic degeneration, coagulative necrosis, and hyperemia in liver sections of rat, similar to the results of previously published papers (Dong *et al.*, 2020; Sepehrinezhad *et al.*, 2021).

Interestingly, we found that the pretreatment of IBA prevented the TAA-induced acute histopathological injuries gradually in a dose-dependent manner, especially inhibited the injuries at 60 µg/kg. IBA is an efficient growth regulator in plant and its toxicity of high-dose (100-500 mg/kg) have been repeatedly demonstrated against non-targeting organisms including human and animals (Tudi *et al.*, 2022). In addition, the exposure of IBA, even at nonlethal dose (4-5 mg/kg during 25 or 45 days), had neurotoxic and immune-toxic effects resulted from the decreased activity of adenosine deaminase and increased activity of myeloperoxidase (Yilmaz and Celik, 2009). In contrast, the subacute and subchronic long-term exposure with IBA in rat leads to increase of antioxidative defense systems served as protective responses to eliminate the toxicant (Topalca *et al.*, 2009). To date, there have been no studies on the effects of very low-dose of IBA, and no studies suggesting that it protects against hepatotoxicity. For this reason, it is very difficult to compare the exact mechanisms for hepatoprotective effect of very low

concentrations of IBA found in this experiment with previous results investigating toxic profiles of rat injected with IBA, for safe use the plant growth regulator for agricultural purposes. Nevertheless, the beneficial effects, as well as harmful effects, of indole-3-acetic acid (IAA) in human and animals have been reported (Krishnan *et al.*, 2018; Ji *et al.*, 2019). In fact, IBA and IAA are intermediate metabolites in the synthesis of the amino acid tryptophan, which occurs widely in plant, fungi, bacteria, animals and other species (McLaughlin *et al.*, 2021). Indeed, animals can obtain small amounts of IAA and IBA as metabolites of intestinal microorganisms, absorption from plant feed into the intestine, or can produce directly through tryptophan synthesis in several tissues (Chen *et al.*, 2018). Because IBA, an endogenous phytohormone, is converted to IAA in a peroxisomal β -oxidation process, it has similar chemical structure and physiological activity to IAA (Damodaran and Strader, 2019), which promotes plant growth. In human and animal studies, it has been reported the anti-cancer activity (Rossiter *et al.*, 2002) as well as antioxidant activity (Kim *et al.*, 2017) and anti-inflammatory activities (Ji *et al.*, 2019; Krishnan *et al.*, 2018) of IAA and its analogues. Such experiments were carried out in µg units in cells and they detected the agents as ng/mL units in blood when administered in mg units *in vivo*. Plant hormones as high-dose (500 mg/kg) pesticides or plant growth promoters can cause oxidative damage, causing toxicity to the human body and animals through free radicals and lipid peroxidation (Ismail, 2022), but small amounts of plant hormones could have beneficial effect (Kim *et al.*, 2017).

TAA is an indirect/non-destructive hepatotoxin that causes pathophysiological changes such as metabolic disorders first and then secondarily disrupts the cell structure (Dong *et al.*, 2020; Sepehrinezhad *et al.*, 2021). In this study, we showed that the administration of high

concentrations of TAA causes weight loss, dehydration, metabolic acidosis (alteration of pH, HCO_3^- , BE-b and BE-ecf), respiratory acidosis (alteration of SO_2 , $p\text{O}_2$ and $p\text{CO}_2$), fluctuations in blood energy-related enzymes (ALT, AST and LDH) and metabolites (Alb, Glucose, T-PRO, TG and T-CHO), and changes in blood ions (particularly Mg^{2+} and Ca^{2+}), along with histopathological damages. The respiratory and metabolic acidosis is thought to be caused by thioacetamide S-oxide and free radicals, which are peroxides formed by flavin-containing monooxygenase and cytochrome P4502E1 (Akhtar and Sheikh, 2013). In addition, it is believed that the peroxide caused inhibition of mitochondria's activity and fluctuation in cell membrane permeability, resulting in leakage of ALT, AST, and LDH in the blood, and fluctuation of carbohydrate, protein, and fat metabolism (Sepehrinezhad *et al.*, 2021). When mitochondria membrane pores or ion channels open, rapid changes in mitochondria membrane permeability transition pores cause membrane potential loss, increase production of free radicals, decrease ATP production, release toxic substances into cytoplasm, change of cytoskeleton, cause ion imbalance, and cause inflammatory organelles (Galluzzi and Vitale, 2018). In that situation, it is known that apoptosis occurs when ATP is sufficient and necrosis occurs when ATP is insufficient (Sepehrinezhad *et al.*, 2021). Our results show that TAA decreased Ca^{2+} in the blood and conversely increased Mg^{2+} in the blood. The increase in blood Ca^{2+} by TAA is consistent with the results reported by TAA in isolated hepatocytes that inhibiting Ca^{2+} pump (Ca^{2+} -ATPase) increases intracellular Ca^{2+} inflow and inhibits extracellular outflow (Diez-Fernandez and Cascales, 1996; Oliva-Vilarnau *et al.*, 2018.). In chronic administration (1 month), the outflow of Ca^{2+} due to tissue damage reduced the total Ca^{2+} of rats, including bones and blood (Jin *et al.*, 2022.). Since most ATPs in cells exist in a binding form with Mg^{2+} , when ATP in cells decreases due to acidosis and energy metabolism, Mg^{2+} in cells increases and membrane permeability increases, resulting in an increase in Mg^{2+} in blood (Lee *et al.*, 2017). A decrease in intracellular Mg^{2+} accelerates immediate metabolic disturbance, which promotes necrosis (Liu *et al.*, 2019). Also, we demonstrated that the pretreatment of IBA prevented the TAA-induced acute injuries gradually in a dose-dependent manner, especially inhibited the injuries at 60 $\mu\text{g}/\text{kg}$, suggesting the protective pathways against metabolic disorders, acidosis, membrane permeability fluctuations, ionic imbalance and tissue damage caused by oxidative damage caused by TAA. It has recently been suggested that IBA can accelerate the growth of barley roots through anti-oxidation in cadmium intoxication (Valentovičová and Tamás, 2020) and that IAA can defend against oxidative damage caused by H_2O_2 in human dental pulp stem cells (Kim *et al.*, 2017).

In this study, the weight loss together with dehydration (as an increase in Hct and Hb resulted from a consequence of a decrease in plasma volume (Popkin *et al.*, 2010) caused by TAA was due to a significant decrease in feed intake (from 30.8 ± 0.6 to 7.4 ± 1.4 mg/g/day after TAA treatment, $p < 0.001$) with the no significant increase in water intake (from 6.3 ± 0.5 to 7.7 ± 0.7 mL/g/day, $P = 0.45$) or the debilitation by TTA due to multiple organ toxicity including liver, lungs, kidney, spleen, pancreas and brain etc. (Akhtar and Sheikh, 2013). Our findings, in which

weight loss and dehydration by TTA are suppressed by low-dose IBA pretreatment, are supported by other studies: the stimulating effect of butyric acid on calf rumen mucosa (Mentschel *et al.*, 2001) and the beneficial effect of IAA as potentially effective feed additive for laying performance and egg quality in hens (Chen *et al.*, 2001).

Conclusions: In view of our observation, we strongly propose that the low-dose IBA treatment may have the therapeutic effect against acute hepatic injury via protective pathways against metabolic disorders, acidosis, membrane permeability fluctuations, ionic imbalance and tissue damage caused by oxidative damage caused by TAA. However, further studies are needed to verify therapeutic possibilities in pets, farm animals and humans.

Acknowledgments: The Ministry of Science and Technology supported this work, the Republic of Korea (NRF-2018R1A2B6003332 and NRF-2021R111A3043876). Also, this work was supported by Korea Institute of Planning and Evaluation for Technology in Food, Agriculture and Forestry (IPET) through Agriculture, Food and Rural Affairs Convergence Technologies Program for Educating Creative Global Leader, funded by Ministry of Agriculture, Food and Rural Affairs (MAFRA) (716002-7).

Authors contribution: Maab Ahmed Abdalrhman Ahmed and Gareeballah Osman Adam collected and analyzed the blood data. Dong Kwon Yang and Tsendsuren Tungalag collected and analyzed the histopathological data. Sei-Jin Lee and Hyung-Sub Kang provided research funds and experimental equipment. Jin-Shang Kim and Shang-Jin Kim conceptualized the study and wrote the manuscript.

REFERENCES

- Akhtar T and Sheikh N, 2013. An overview of thioacetamide-induced hepatotoxicity. *Toxin Rev* 32:43–6.
- Brown SA, Axenfeld E, Stonesifer EG, *et al.*, 2018. Current and prospective therapies for acute liver failure. *Dis Mon* 64:493–522.
- Chen L, Xia J, Wang L, *et al.*, 2021. Effects of dietary indole-3-acetate sodium on laying performance, egg quality, serum hormone levels and biochemical parameters of danzhou chickens. *Animals* 11:619.
- Chinapolaiah A, Damors PR, Gn M, *et al.*, 2019. Vegetative propagation of *Adhatoda vasica* a medicinal plant: effect of indole-3-butyric acid (IBA) on stem cuttings. *J Pharmacogn Phytochem* 8:1176–80.
- Damodaran S and Strader LC, 2019. Indole 3-butyric acid metabolism and transport in *Arabidopsis thaliana*. *Front Plant Sci* 10:851.
- Deckardt K, Weber I, Kaspers U, *et al.*, 2007. The effects of inhalation anaesthetics on common clinical pathology parameters in laboratory rats. *Food Chem Toxicol* 45:1709–18.
- Diez-Fernandez SN and Cascales M, 1996. Intracellular calcium concentration impairment in hepatocytes from thioacetamide-treated rats. Implications for the activity of Ca^{2+} -dependent enzymes. *J Hepatol* 24:460–7.
- Dong V, Nanchal R and Karvellas CJ, 2020. Pathophysiology of acute liver failure. *Nutr Clin Pract* 35:24–9.
- Mentschel J, Leiser R, Mülling C, *et al.*, 2001. Butyric acid stimulates rumen mucosa development in the calf mainly by a reduction of apoptosis. *Arch Anim Nutr* 55:85–102.
- Fitzhugh OG and Nelson AA, 1948. Liver tumors in rats fed thiourea or thioacetamide. *Science* 108:626–8.
- Galluzzi L and Vitale I, 2018. Molecular mechanisms of cell death: recommendations of the Nomenclature Committee on Cell Death 2018. *Cell Death Differ* 25:486–541.
- Iorga A and Dara L, 2019. Cell death in drug-induced liver injury. *Adv Pharmacol* 85:31–74.
- Ismail HTH, 2022. Assessment toxic effects of exposure to 3-indoleacetic acid via hemato-biochemical, hormonal, and histopathological

- screening in rats. *Environ Sci Pollut Res Int*. <https://doi.org/10.1007/s11356-022-22026-8>
- Ji Y, Gao Y, Chen H, et al., 2019. Indole-3-acetic acid alleviates non-alcoholic fatty liver disease in mice via attenuation of hepatic lipogenesis and oxidative and inflammatory stress. *Nutrients* 11:2062.
- Jin X, Li Y, Li J, et al., 2022. Acute bone damage through liver-bone axis induced by thioacetamide in rats. *BMC Pharmacol Toxicol* 23:29.
- Kim D, Kim H, Kim K, et al., 2017. Roh S. The protective effect of indole-3-acetic acid (IAA) on H₂O₂-damaged human dental pulp stem cells is mediated by the AKT pathway and involves increased expression of the transcription factor nuclear factor-erythroid 2-related factor 2 (Nrf2) and its downstream target heme oxygenase 1 (HO-1). *Oxid Med Cell Longev* 2017:8639485.
- Krishnan S, Ding Y, Saedi N, et al., 2018. Gut microbiota-derived tryptophan metabolites modulate inflammatory response in hepatocytes and macrophages. *Cell Rep* 23:1099–11.
- Lee MY, Yang DK, Kim SJ, 2017. Alterations of Mg²⁺ after hemorrhagic shock. *Biol Trace Elem Res* 180:120–6.
- Liu M, Yang H and Mao Y, 2019. Magnesium and liver disease. *Ann Transl Med* 7:578.
- McLaughlin HM, Ang ACH and Østergaard L, 2021. Noncanonical auxin signaling. *Cold Spring Harb Perspect Biol* 13:a039917.
- Moon AM, Singal AG and Tapper EB, 2020. Contemporary epidemiology of chronic liver disease and cirrhosis. *Clin Gastroenterol Hepatol* 18:2650–66.
- Oliva-Vilarnau N, Hankeova S, Vorrink SU, et al., 2018. Calcium signaling in liver injury and regeneration. *Front Med* 5:192.
- Popkin BM, D'Anci KE and Rosenberg IH, 2010. Water, hydration, and health. *Nutr Rev* 68:439–58.
- Rossiter S, Folkes LK and Wardman P, 2002. Halogenated indole-3-acetic acids as oxidatively activated prodrugs with potential for targeted cancer therapy. *Bioorganic Med Chem Lett* 12:2523–6.
- Sepehrinezhad A, Shahbazi A, Sahab Negah S, et al., 2021. Drug-induced-acute liver failure: A critical appraisal of the thioacetamide model for the study of hepatic encephalopathy. *Toxicol Rep* 30:962–70.
- Shen FF, Wang Y, Wang YF, et al., 2018. Prediction of hepatic necroinflammatory activity in patients with chronic hepatitis B by a simple noninvasive model. *J Transl Med* 16:1–11.
- Small CC and Degenhardt D, 2018. Plant growth regulators for enhancing revegetation success in reclamation: A review. *Ecol Eng* 118:43–51.
- Topalca N, Yegin E, Celik I, 2009. Influence of Indole-3-butyric acid on antioxidant defense systems in various tissues of rats at subacute and subchronic exposure. *Food Chem Toxicol* 47:2441–4.
- Tudi M, Li H, Li H, et al., 2022. Exposure routes and health risks associated with pesticide application. *Toxics* 10:335.
- Valentovičová K and Tamás L, 2020. Indole-3-butyric acid priming reduced cadmium toxicity in barley root tip via NO generation and enhanced glutathione peroxidase activity. *Planta* 252:46.
- Yilmaz Z and Celik I, 2009. Neurotoxic and immunotoxic effects of Indole-3-butyric acid on rats at subacute and subchronic exposure. *Neurotoxicol* 30:382–5.
- Zhang Q, Gong M, Xu X, et al., 2022. Roles of auxin in the growth, development, and stress tolerance of horticultural plants. *Cells* 11:2761.