



RESEARCH ARTICLE

Nephroprotective Effects of Delphinidin against Bisphenol A Induced Kidney Damage in Rats

Kaynat Alvi¹, Muhammad Umar Ijaz¹, Ali Hamza¹, Asma Ashraf², Jessica Arooj² and Nazia Ehsan^{1*}

¹Department of Zoology, Wildlife and Fisheries, University of Agriculture, Faisalabad, Pakistan

²Department of Zoology, Government College, University, Faisalabad

*Corresponding author: nazia.ehsan@uaf.edu.pk

ARTICLE HISTORY (22-356)

Received: October 16, 2022
Revised: November 20, 2022
Accepted: November 22, 2022
Published online: December 05, 2022

Key words:

Bisphenol A
Delphinidin
Nephrotoxicity
Inflammation
Oxidative stress

ABSTRACT

Bisphenol A (BPA) is a hazardous industrial pollutant that has the potential to induce renal toxicity. Delphinidin (Del) is an anthocyanidin that displays versatile pharmacological properties. The study was designed to access the ameliorative role of Del on BPA-instigated renal impairment. Twenty-four Sprague-Dawley rats were distributed into four groups and the experiment was conducted in triplicate. Group I was designated as a control group (0.1% DMSO), while group II was orally administrated with 10 mg/kg of BPA. Groups III received BPA + Del (10 mg/kg + 25 mg/kg), whereas group IV was treated with Del (25 mg/kg) orally. After the completion of thirty days' experiment, all the rats were euthanized and various parameters were evaluated. The findings of our research showed that administration of BPA tremendously decreased the activities of catalase, glutathione peroxidase, superoxide dismutase, glutathione reductase, glutathione-S-transferase as well as reduced the level of glutathione, while it increased the malondialdehyde level. The production of reactive oxygen species also increased after BPA exposure. Moreover, BPA exposure caused substantial elevation in urea and creatinine levels, with significantly low creatinine clearance. Furthermore, BPA remarkably escalated the inflammatory markers level (interleukin-1 β , nuclear factor kappa-B, interleukin-6, tumor necrosis factor- α , as well as cyclooxygenase-2 activity) and caused histopathological damage. Del + BPA co-treatment showed renoprotective effects against BPA-induced damages by restoring all the parameters. Collectively, the treatment of Del showed a remedial role against the nephrotoxic effects of BPA that might be linked with its antioxidant and anti-inflammatory properties.

To Cite This Article: Alvi K, Ijaz MU, Hamza A, Ashraf A, Arooj J and Ehsan N, 2022. Nephroprotective effects of delphinidin against bisphenol a induced kidney damage in rats. Pak Vet J. <http://dx.doi.org/10.29261/pakvetj/2022.085>

INTRODUCTION

BPA is a white crystalline polymeric organic compound that is widely used to produce a variety of chemical products such as thermal stabilizers, paints, plasticizers and dental material (Ahmed *et al.*, 2015). It is also used to synthesize polycarbonate and epoxy resins. Owing to its massive use in industrial products, BPA has been detected in different body fluids including neonatal blood and amniotic fluid (Vandenberg *et al.*, 2010). Ingestion is considered as the main route for BPA toxicity (Ribeiro *et al.*, 2017). Aside from dermal absorption, inhalation is regarded as another route of BPA exposure, particularly for the workers who deal with manufacturing of BPA products (Biedermann *et al.*, 2010). Previous reports have confirmed that BPA causes detrimental

effects on the nervous system, metabolic function, reproductive system and immune system. Moreover, BPA exposure can also damage the brain, liver and kidney through reactive oxygen species (ROS) (Faheem and Lone, 2018; Faheem and Bhandari, 2021).

Kidney is a vital organ in the body that is involved in the process of homeostasis. BPA exposure instigates renal damage by the degeneration of the tubular system as well as dysregulation in the biochemical profile of the kidney (Poormoosavi *et al.*, 2018; Aslanturk and Uzunhisarcikli, 2020). Although, kidney eliminates BPA but its accumulation results in a significant decline of the glomerular filtration rate (Kobroob *et al.*, 2018). BPA exposure directly affects the kidney, resulting in mitochondrial damage that is associated with oxidative stress instigated by the inhibition of the electron transport

chain (Shirani *et al.*, 2019). However, a strong link is reported between the high content of BPA in serum and elevation in the level of inflammatory markers in the tubular system of the kidney (Alekhya-Sita *et al.*, 2019).

Anthocyanidins are flavonoids that are naturally present in fruits and vegetables and belongs to the category of polyphenols (Sinopoli *et al.*, 2019). Del is an anthocyanidin and displays several pharmacological properties owing to the presence of a numerous -OH groups (Jing *et al.*, 2015). Del exhibits antimutagenic, antioxidant, antiangiogenic and anti-inflammatory properties (Kang *et al.*, 2018). By considering the remedial properties of Del, the current experiment was performed to access the defensive role of Del on BPA-promoting renal impairment.

MATERIALS AND METHODS

Chemicals: Both BPA (CAS no. 80-05-7) and Del (CAS no. 528-53-0) were bought from Sigma-Aldrich (Germany).

Experimental animals: Sprague-Dawley rats (n=24) were used for the experiment. The animals were (200 ± 30 g) kept in separate cages (n=6) in the animal care center of University of Agriculture, Faisalabad under controlled temperature (25±2°C). Adequate amount of humidity and 12 hours day/night cycle were also maintained. Food and tap water were given to the experimental animals as per requirement. European Union of Animal Care and Experimentation techniques (CEE Council 86/ 609) were followed during the experiment for the care and treatment of animals.

Experimental protocol: Twenty-four rats were distributed into 4 groups (n=6) and the experiment was conducted in triplicates. Group I was designated as a control group (0.1% DMSO). Group II was treated with 10 mg/kg of BPA by dissolving it into 0.1% DMSO and provided by oral gavage. The 10 mg/kg dose of BPA was used in accordance with the earlier investigation of Olukole *et al.* (2018). Group III was co-administrated with BPA + Del (both 10 mg/kg of BPA and 25 mg/kg of Del were dissolved in 0.1% DMSO and administered by oral gavage), whereas group IV was supplemented with Del (Del 25 mg/kg was dissolved in 0.1% DMSO and administered orally). The 25 mg/kg dose of Del was used in accordance with the previous investigation of Heysieattalab and Sadeghi, (2020). After thirty days of the trial, animals were euthanized and samples of blood were filled in sterile tubes for the evaluation of serum parameters. Both kidneys were excised and the right kidney was used to evaluate biological parameters. For this purpose, the right kidney was preserved in zipper bags and kept at -80°C. 3 mL of phosphate buffer saline (PBS) was used to homogenize the 0.5 mg renal tissues and centrifuged for fifteen minutes at 12000 rpm. Left kidney was preserved in 10% formalin for histological observation.

Antioxidant enzyme accessment: Catalase (CAT) activity was measured by adopting the technique of

Chance and Maehly (1955). While, superoxide dismutase activity (SOD) was evaluated by using the procedure of Nishikimi *et al.* (1972). Rotruck *et al.* (1973) methodology was adopted to evaluate the activity of glutathione peroxidase (GPx). However, Carlberg and Mannervik's (1975) procedure was followed to evaluate the glutathione reductase activity (GSR). While, glutathione-S-transferase (GST) activity and glutathione (GSH) level were determined by using the protocol stated by Habig *et al.* (1974) and Jollow *et al.* (1974) respectively. Total protein kit (Cat no: TP0100-1KT) was purchased from Merck to estimate total protein.

Evaluation of oxidative stress markers: Reactive oxygen species level (ROS) was accessed by the procedure stated by Hayashi *et al.* (2007), whereas malondialdehyde level (MDA) was detected by the technique explained by Zhang *et al.* (2014).

Renal markers estimation: Creatinine, urea as well as creatinine clearance was estimated in accordance with the laboratory procedure given with standard Randox lab kits Crumlin, Co. Antrim, UK.

Renal inflammatory markers estimation: Inflammatory markers of kidneys were evaluated with the help of commercially available kits. The level of interleukin-1β (IL-1β), nuclear factor kappa-B (NF-κB), interleukin-6 (IL-6), tumor necrosis factor-α (TNF-α) and cyclooxygenase-2 (COX-2) activity was assessed with rats ELISA kit (Shanghai-YL-Biotech. Co. Ltd., China) and analysis was performed in accordance with manufacturer's instructions using ELISA Plate Reader (MarkTM microplate absorbance reader1681130).

Histological examination: Renal samples were fixed in formalin buffer (about 10%) solution. Samples were dehydrated in different ascending (80 %, 90 % and 100 %) grades of ethyl alcohol followed by embedding in paraffin wax. By using microtome, thin slices were cut (4-5 μm) and then stained with hematoxylin-eosin (H&E). Analysis of renal tissues were performed with a compound microscope (Nikon, 187842, Japan). To capture images as well as for observation of renal tissues, Leica-LB and image-J2x software were used.

Statistical Analysis: Results were represented as Mean ± SEM. One-way analysis of variance (ANOVA) followed by Tukey's test was used to compare different groups. Significance level was set as $P < 0.05$.

RESULTS

Effects of Del and BPA on antioxidant activities of enzymes: BPA administration showed a remarkable decline ($P < 0.05$) in the antioxidant activities of GPx, SOD, CAT, GSR, GST as well as GSH level. In addition, co-administration of BPA and Del substantially improved ($P < 0.05$) the antioxidant activities in BPA + Del group in contrast to BPA-intoxicated rats. However, Del alone supplementation retained the normal activity of enzymes as in control group (Table 1).

Table 1: Role of Del and BPA on the antioxidant enzymatic activity

Parameters	Groups			
	Control	BPA	BPA + Del	Del
CAT (U/mg protein)	9.06±0.47 ^a	4.41±0.19 ^b	7.65±0.30 ^a	9.21±0.47 ^a
GPx (U/mg protein)	17.72±0.32 ^a	7.78±0.23 ^c	16.36±0.16 ^b	17.75±0.40 ^a
SOD (U/mg protein)	5.86±0.28 ^a	3.09±0.15 ^b	4.93±0.20 ^a	5.89±0.35 ^a
GSR (nM NADPH oxidized/min/mg tissue)	4.03±0.13 ^a	1.36±0.05 ^c	3.02±0.22 ^b	4.07±0.13 ^a
GST (nM/min/mg protein)	24.39±1.32 ^a	11.11±0.21 ^b	20.80±0.64 ^a	24.10±2.05 ^a
GSH (µM/g tissue)	16.70±0.63 ^a	7.91±0.20 ^c	14.24±0.28 ^b	16.25±0.54 ^{ab}

Means that contain different superscripts in the same row are significantly different

Table 2: Role of Del and BPA on oxidative stress markers of kidney

Parameters	Groups			
	Control	BPA	BPA + Del	Del
MDA (nmol/g)	0.68±0.09 ^b	2.62±0.14 ^a	1.05±0.09 ^b	0.66±0.05 ^b
ROS (µmol/g)	1.59±0.06 ^c	7.42±0.18 ^a	2.35±0.11 ^b	1.57±0.06 ^c

Means that contain different superscripts in the same row are significantly different.

Table 3: Role of Del and BPA on renal function markers

Parameters	Groups			
	Control	BPA	BPA + Del	Del
Urea (mg/dL)	16.52±0.68 ^c	43.60±1.24 ^a	24.96±1.02 ^b	16.40±0.63 ^c
Creatinine (mg/dL)	1.58±0.04 ^c	6.63±0.06 ^a	2.14±0.06 ^b	1.53±0.04 ^c
Creatinine clearance (mL/min)	1.90±0.03 ^a	0.32±0.04 ^c	1.36±0.04 ^b	1.93±0.02 ^a

Means that contain different superscripts in the same row are significantly different

Table 4: Role of Del and BPA on inflammatory markers of renal tissues

Parameters	Groups			
	Control	BPA	BPA + Del	Del
NF-κB (ng/g tissue)	14.72±0.97 ^c	65.38±2.22 ^a	25.34±1.27 ^b	14.47±0.93 ^c
TNF-α (ng/g tissue)	8.22±0.27 ^b	19.73±1.18 ^a	10.66±0.63 ^b	8.13±0.30 ^b
IL-1β (ng/g tissue)	26.29±0.52 ^c	87.69±1.20 ^a	33.53±1.68 ^b	26.18±0.40 ^c
IL-6 (ng/g tissue)	6.33±0.55 ^c	24.63±0.99 ^a	10.57±0.58 ^b	6.31±0.49 ^c
COX-2 (ng/g tissue)	27.43±0.70 ^c	72.06±2.67 ^a	34.75±1.06 ^b	27.55±0.48 ^c

Means that contain different superscripts in the same row are significantly different.

Effects of Del and BPA on oxidative stress markers:

BPA exposure elevated the ($P<0.05$) MDA and ROS level in BPA treated group than in control group. Nevertheless, MDA and ROS level were considerably depleted, ($P<0.05$) after the co-treatment of Del + BPA in co-treated group in contrast to the BPA group. Moreover, Del alone supplementation maintained the level of MDA and ROS as in the control group (Table 2).

Effects of Del and BPA on renal markers:

Urea and creatinine content were augmented ($P<0.05$) in the BPA-intoxicated group than in control group. While, creatinine clearance was remarkably reduced ($P<0.05$) after administration of BPA. The findings of our study depict that Del co-treatment along with BPA improved urea, creatinine and creatinine clearance level in Del + BPA group in contrast to the BPA-intoxicated group. However, Del only treated group normalized the levels of renal markers near to control (Table 3).

Effects of Del and BPA on renal inflammatory mediators:

BPA exposure remarkably elevated ($P<0.05$) the inflammatory markers level (IL-1β, NF-κB, IL-6, TNF-α, as well as COX-2 activity) in BPA exposed group than in control group. While, BPA + Del co-administration reduced ($P<0.05$) the level of IL-1β, NF-κB, IL-6, TNF-α as well as COX-2 activity in co-treated group in contrast to BPA treated group. Del alone administration maintained the normal level of these parameters (Table 4).

Effects of BPA and Del on renal histology:

The histopathology of the control and Del groups revealed the normal structure of glomerulus, Bowman's capsule and convoluted tubules (Fig. 1 A and D). Whereas, the glomeruli of BPA-treated rats were significantly congested with increased damage in Bowman's capsule and alternation in the tubular system of the kidney (Fig. 1 B). Instead, the histopathology of the co-treated group (BPA + Del) showed improved morphology of glomerular and the lining of the tubular renal epithelium (Fig. 1 C).

DISCUSSION

The level of toxic substances increases in the environment due to pollution, which can cause adverse effects on humans and animals. BPA is a ubiquitous chemical pollutant that contaminates the environment (Poormoosavi *et al.*, 2018). Previous study has confirmed that BPA induces oxidative damage as well as several disorders in the kidney and other body organs (Ma *et al.*, 2019). The purpose of the recent research was to evaluate the alleviating role of Del on nephrotoxicity caused by BPA. According to our findings, a remarkable decline in CAT, GPx, SOD, GSR, GST activities and the level of GSH was detected after BPA exposure. However, there was a remarkable augmentation in MDA level which indicates lipid peroxidation. Furthermore, BPA administration induced oxidative stress by the production of ROS. The imbalance between oxidative stress markers and antioxidant enzymes activity leads to the deterioration

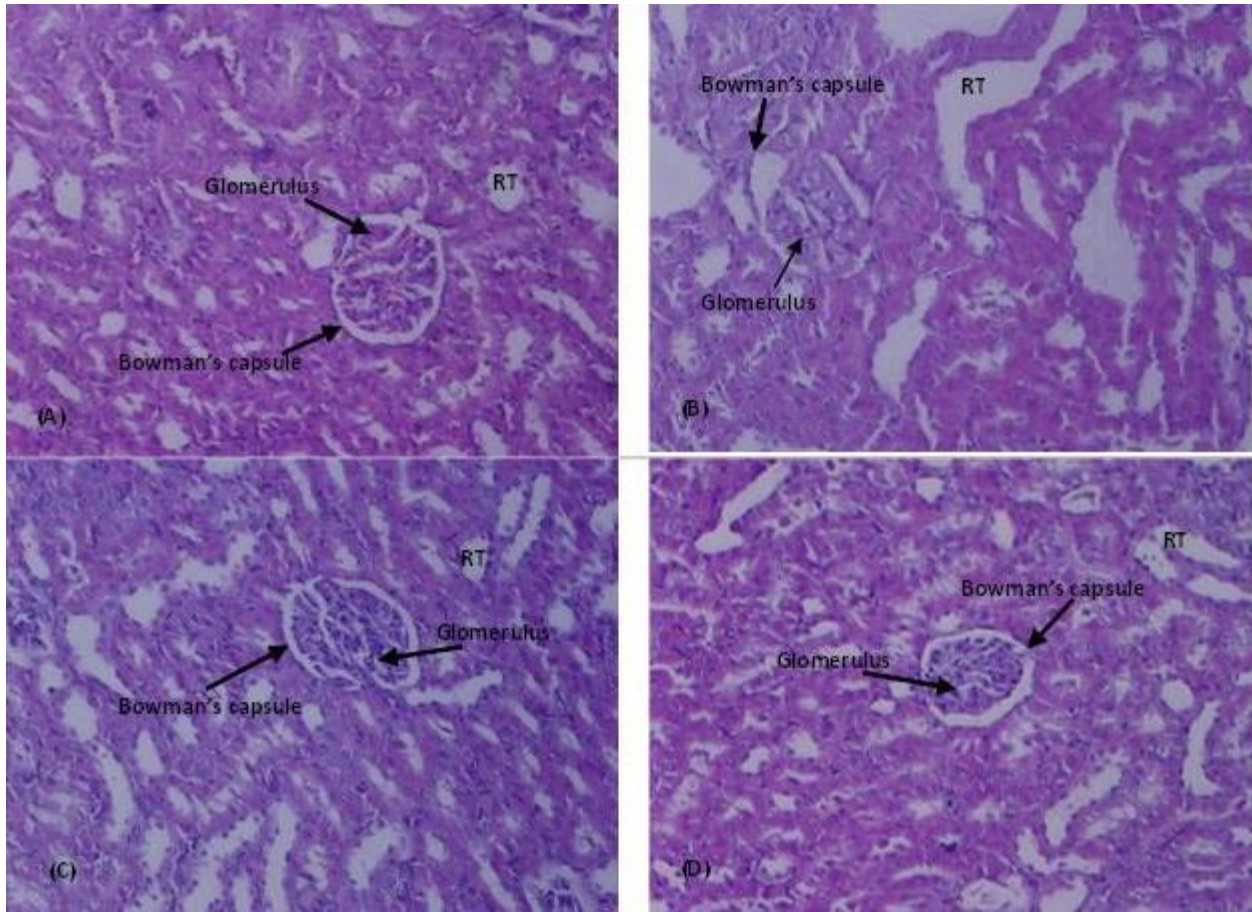


Fig. 1: Ameliorative impact of Del on BPA promoted histological impairments in kidney tissues (H & E/ 400X). (A) Control group (B) BPA administrated group (10 mg/kg) (C) Del + BPA co-administrated group (25 mg/kg + 10 mg/kg) (D) Del supplemented group (25 mg/kg). RT: Renal tubules

of renal functions (Liu *et al.*, 2021). SOD and CAT play a protective role by eradicating the free radicals from the kidney. CAT catalyzes the conversion of H_2O_2 into oxygen and water and defends from cellular oxidative stress induced by H_2O_2 and hydroxyl radicals (Nieskens *et al.*, 2018). Jing *et al.* (2015) stated that the antioxidant activity of Del is linked with the presence of numerous OH groups in its structure.

The current analysis showed that Del supplementation alone, remarkably reduced the level of ROS and MDA as well as maintained the normal activity of antioxidant enzymes.

According to the current study, BPA exposure indicated a considerable escalation in the urea and creatinine level, while a substantial decrease in creatinine clearance. Both urea and creatinine are clinically used as an indicator to evaluate normal kidney function as well as any renal impairment (Ramsey *et al.*, 2018). Edres *et al.* (2018) illustrated that kidneys are unable to eliminate the BPA completely from the body and its accumulation results in nephrotoxicity. Furthermore, BPA exposure reduced the rate of glomerular filtration (Kobroob *et al.*, 2018). Del + BPA co-treatment lowered the urea and creatinine level by enhancing the rate of glomerular filtration, which is indicated by increased creatinine clearance.

Our results indicated that BPA administration elevated the level of IL-1 β , NF- κ B, IL-6, TNF- α as well

as COX-2 activity as compared with control group. NF- κ B activation plays a major role to augment the pro-inflammatory cytokines expression such as IL-1 β , NF- κ B, IL-6, TNF- α and COX-2, which induced acute inflammation and ROS-associated damages (Khan *et al.*, 2020). Moreover, COX-2 is another significant inflammatory mediator that plays a key role to induce inflammation in the kidneys (Gandhi *et al.*, 2017). The recent findings of our investigation indicated that the COX-2 activity was increased in BPA administrated group which reflects the state of inflammation. However, Del treatment suppressed the activation of NF- κ B, which is the main indicator to induce inflammation in tissues. Therefore, it is concluded that Del might be used to reduce the level of inflammatory markers due to its anti-inflammatory property.

Histopathological analysis of the control group and Del group depicted the normal morphology of the kidney. Both groups displayed normal glomeruli, Bowman's capsule, and distal and convoluted tubules. BPA treatment caused the destruction of Bowman capsule, congestion of glomerulus, increased vacuolization, distortion of tubular renal epithelial lining and degeneration of renal tubules. Co-administration of BPA and Del ameliorated the kidney damage induced by BPA treatment. Poormoosavi *et al.* (2018) investigated tubular necrosis, glomerulus congestion, cellular swelling and alternation in the histopathology of the tubular system of the kidney after

BPA treatment. So, it was found that Del supplementation successfully reduced renal impairment, oxidative stress and inflammation, which depicts its anti-inflammatory and antioxidant potential.

Conclusions: In conclusion, BPA exposure caused nephrotoxicity in rats by increasing the levels of inflammatory mediators as well as oxidative stress markers. However, Del supplementation reversed all the elevated levels of markers that were induced by BPA exposure. Besides, the renoprotective effects of Del improved the histopathological changes induced by BPA exposure. Collectively, the antioxidant and anti-inflammatory properties of Del can be used to ameliorate BPA-instigated renal damage.

Authors contribution: KA, MUI and NE Conceived the idea of study, KA and AH performed the experiments. AA and JA helped in statistical analysis. KA and MUI wrote the manuscript. All the authors approved the manuscript prior to submission.

REFERENCES

- Ahmed WS, Moselhy WA and Nabil TM, 2015. Bisphenol A toxicity in adult male rats: hematological, biochemical and histopathological approach. *Glob Vet* 14:228-38.
- Alekhyia-Sita GI, Gowthami M, Srikanth G, et al., 2019. Protective role of luteolin against bisphenol A-induced renal toxicity through suppressing oxidative stress, inflammation, and upregulating Nrf2/ARE/HO-1 pathway. *IUBMB Life* 71:1041-47.
- Aslanturk A and Uzunhisarcikli M, 2020. Protective potential of curcumin or taurine on nephrotoxicity caused by bisphenol A. *Environ Sci Pollut Res* 27:23994-24003.
- Biedermann S, Tschudin P and Grob K, 2010. Transfer of bisphenol A from thermal printer paper to the skin. *Anal Bioanal Chem* 398:571-76.
- Carlberg I and Mannervik B, 1975. Purification and characterization of the flavoenzyme glutathione reductase from rat liver. *J Biol Chem* 250:5475-80.
- Chance B and Maehly AC, 1955. Assay of catalases and peroxidases. *Methods Enzymol* 11:764-75.
- Edres HA, Taha NM, Mandour AEWA, et al., 2018. Impact of L-Carnitine on Bisphenol A-Induced Kidney Damage in Rats. *Alex J Vet Sci* 56:11-17.
- Faheem M and Bhandari RK, 2021. Detrimental effects of bisphenol compounds on physiology and reproduction in fish: a literature review. *Environ Toxicol Pharmacol* 81: p.103497.
- Faheem M and Lone KP, 2018. Oxidative stress and histopathologic biomarkers of exposure to bisphenol-A in the freshwater fish, *Ctenopharyngodon idella*. *Braz J Pharm Sci* 53: 17003.
- Gandhi J, Khera L, Gaur N, et al., 2017. Role of modulator of inflammation cyclooxygenase-2 in gammaherpesvirus mediated tumorigenesis. *Frontiers in Microbiol* 8:538.
- Habig WH, Pabst MJ and Jokoby VVB, 1974. Glutathione S-transferase: the first enzymatic step in mercapturic acid formation. *J Biol Chem* 249:7130-39.
- Hayashi I, Morishita Y, Imai K, et al., 2007. High-throughput spectrophotometric assay of reactive oxygen species in serum. *Mutat Res Genet Toxicol Environ Mutagen* 613:55-61.
- Heysieattalab S and Sadeghi L, 2020. Effects of delphinidin on pathophysiological signs of nucleus basalis of Meynert lesioned rats as animal model of Alzheimer disease. *Neurochem Res* 45:1636-46.
- Jing P, Qian B, Zhao S, et al., 2015. Effect of glycosylation patterns of Chinese eggplant anthocyanins and other derivatives on antioxidant effectiveness in human colon cell lines. *Food Chem* 172:183-89.
- Jollow D, Mitchell J, Zampaglione NA, et al., 1974. Bromobenzene-induced liver necrosis. Protective role of glutathione and evidence for 3, 4- bromobenzene oxide as the hepatotoxic metabolite. *Pharmacology* 11:151-69.
- Kang HM, Park BS, Kang HK, et al., 2018. Delphinidin induces apoptosis and inhibits epithelial-to-mesenchymal transition via the ERK/p38 MAPK-signaling pathway in human osteosarcoma cell lines. *Environmental toxicology* 33:640-49.
- Khan TH, Ganaie MA, Alharthy KM, et al., 2020. Naringenin prevents doxorubicin-induced toxicity in kidney tissues by regulating the oxidative and inflammatory insult in Wistar rats. *Arch Physiol Biochem* 126:300-07.
- Kobroob A, Peerapanyasut W, Chattipakorn N, et al., 2018. Damaging effects of bisphenol A on the kidney and the protection by melatonin: Emerging evidence from in vivo and in vitro studies. *Oxid Med Cell Longev* 2018:1-15.
- Liu B, Li Y, Mehmood K, et al., 2021. Role of Oxidative Stress and Antioxidants in Thiram-induced Tibial Dyschondroplasia. *Pak Vet J* 41:1-6.
- Ma Y, Liu H, Wu J, et al., 2019. The adverse health effects of bisphenol A and related toxicity mechanisms. *Environmental research* 176:108575.
- Nishikimi M, Rao NA and Yagi K, 1972. The occurrence of superoxide anion in the reaction of reduced phenazine methosulfate and molecular oxygen. *Biochem Biophys Res Commun* 46:849-54.
- Nieskens TT, Peters JG, Dabaghie D, et al., 2018. Expression of organic anion transporter 1 or 3 in human kidney proximal tubule cells reduces cisplatin sensitivity. *Drug Metab Dispos* 46:592-99.
- Olukole SG, Ajani SO, Ola-Davies EO, et al., 2018. Melatonin ameliorates bisphenol A-induced perturbations of the prostate gland of adult Wistar rats. *Biomed Pharmacother* 105:73-82.
- Poormoosavi SM, Najafzadehvarzi H, Behmanesh MA, et al., 2018. Protective effects of Asparagus officinalis extract against Bisphenol A-induced toxicity in Wistar rats. *Toxicol Rep* 5:427-33.
- Ramsey LB, Balis FM, O'Brien MM, et al., 2018. Consensus guideline for use of glucarpidase in patients with high-dose methotrexate induced acute kidney injury and delayed methotrexate clearance. *The Oncologist* 23:52-61.
- Ribeiro E, Ladeira C and Viegas S, 2017. Occupational exposure to bisphenol A (BPA): a reality that still needs to be unveiled. *Toxics* 5:22.
- Rotruck JT, Pope AL, Ganther HE, et al., 1973. Selenium: biochemical role as a component of glutathione peroxidase. *Science* 179:588-90.
- Shirani M, Alizadeh S, Mahdavinia M, et al., 2019. The ameliorative effect of quercetin on bisphenol A-induced toxicity in mitochondria isolated from rats. *Environ Sci Pollut Res* 26:7688-96.
- Sinopoli A, Calogero G and Bartolotta A, 2019. Computational aspects of anthocyanidins and anthocyanins: A review. *Food chemistry* 297:124898.
- Vandenberg LN, Chahoud I, Heindel JJ, et al., 2010. Urinary, circulating, and tissue biomonitoring studies indicate widespread exposure to bisphenol A. *Environ Health Perspect* 118:1055-70.
- Zhang L, Peng J, Chen TT, et al., 2014. Effect of drought stress on lipid peroxidation and proline content in cotton roots. *J Anim Plant Sci* 24:1729-36.