

EVALUATION OF TWO SUTURING TECHNIQUES FOR END -TO-END ANASTOMOSIS OF COLON IN DOGS

A.B. Kachiwal and A.B Kalhoro
*Department of Surgery and Obstetrics,
Sindh Agricultural University, Tandojam, Pakistan*

ABSTRACT

An experimental study was conducted on 12 healthy adult dogs to determine the best method for anastomosis of colon. An appositional 2 layer (APP-2) suture pattern was compared with the inverting 2 layer (INV-2) suture pattern for end-to-end anastomosis. Vicryl^R (size 3-0) was used for anastomosis. The mean number of stitches and time taken for anastomosis were significantly higher ($P<0.05$) with APP-2 than INV-2. Adhesions at the incision site were also significantly higher ($P<0.05$) with APP-2 than INV-2. Lumen diameters for all anastomoses were smaller than control at 10th, 20th and 30th day after surgery with both patterns. The differences between the values of APP-2 and INV-2 were not statistically different at 10th and 20th day after surgery. The lumen diameter with APP-2 was significantly larger ($P<0.05$) than INV-2 at 30th day after surgery. The current study showed the supremacy of the APP-2 layer suture pattern for colonic end-to-end anastomosis over the INV-2 layer suture pattern.

Keywords: End-to-end anastomosis, colon, dogs

INTRODUCTION

Diseases of gastrointestinal tract requiring surgical intervention are fairly common in dogs (Tangner, 1982). Resection and anastomosis are usually required in cases of intussusception, megacolon, neoplasia, obstruction or trauma etc. Complications associated with intestinal resection and anastomosis are major cause of death in animals requiring abdominal surgery (White, 1985). Complications occur mainly due to lack of strict asepsis, poor surgical technique, improper suture material and poor suturing methods (Armistead, 1959). Commonly encountered problems for intestinal anastomosis are the frequency of breakdown and leakage of intestinal contents in the terminal colon as compared to other intestinal segments (Nichols *et al.*, 1973). Passage of solid faeces through a lumen as well as problems in the bowel wall (increased bacterial concentrations, poor blood supply, strong muscular activity) have been cited as reasons for poor healing (Hawely, 1973; Jiborn *et al.*, 1980, Keller and Horney, 1985). An end-to-end intestinal anastomosis is a simple and physiologically compatible method for intestinal repair as compared with side-to-side intestinal anastomosis (Annis and Allen, 1961). Controversies have continued, however, with regard to the preferred technique for intestinal closure. In order to devise and evaluate a technique which is simple and promise to cover any situation, an experimental model was deigned to compare 2 layer appositional technique with 2 layer inversion technique for anastomosis of colon in dogs.

MATERIALS AND METHODS

Animals

Twelve healthy mongrel dogs of both sexes, various ages (10 ± 2 months) and weights (mean 20 ± 5 k.g) were randomly allotted to group-A and group-B, placing 6 animals in each group. The dogs were kept in quarantine and allowed to adapt to and the surroundings (14 days) prior to experimentation to rule out possibility of any latent infection. During this period they were dewormed with Anthalmin^R (Levamisole hydrochloride 7.5% w/v, Reveex, Spain)@ 5 mg/kg body weight administered intramuscularly. They were vaccinated against rabies, contagious canine hepatitis, leptospirosis and canine distemper with Pentadog^R (1 ml/dog) at least 14 days prior to operation.

One day before surgery each dog was medicated with 10-20 ml of liquid paraffin, 2 to 5 tablets of dulcolax^R (Bisacodyl B.P 5mg/Tab), Merk Marker (Pvt.) Limited, Quetta. Meat and bread were with-held for 24 hours before surgery but continuous access to water was allowed.

Anaesthesia

The dogs were premedicated with acetylpromazine 0.04 mg/kg body weight intramuscularly, 10-20 minutes before induction of anaesthesia. The dogs were anaesthetized with 5 per cent solution of Thiopental sodium to effect. Anaesthesia was maintained with incremental doses of thiopentone, when required.

Surgical procedure

The standard caudal celiotomy and resection procedures were performed (Griener and Christie, 1975). Appositional two layer (APP-2) suture pattern was used in group-A. The first layer comprised of simple interrupted sutures (Plate 1) and 2nd layer of cushioning suture pattern (Plate 2) (Hanson *et al.*, 1988; Griener and Christie, 1975).

Inverted two layer (INV-2) pattern was used in group-B. The first layer was a continuous Connell and second layer was continuous Cushing pattern, using 3/0 vicryl suture (Hanson *et al.*, 1988; Larsen and Bllelenger, 1974).

Post-operative care

Water and milk were provided *ad libitum* on post-operative day 1 and a soft diet on post operative day 3.

Observations and necropsy findings

Monitoring of the animals consisted of recording the physiological parameters daily up to post operative day 7. Number of stitches and duration required for end-to-end anastomosis of colon were recorded during surgery.

Postmortem examination of the anastomotic sites and abdominal viscera were performed at 10th, 20th, and 30th day after surgery. Dehiscence, leakage from anastomotic site, break down/loss of suture line, adhesion formation between anastomotic site and visceral organs or peritoneum, if any were recorded as described by Hanson *et al.* 1988. Decrease in lumen diameter of the intestinal anastomosis was determined as described by Hanson *et al.* (1988) and Levine *et al.* (1988). Twenty four segments of colon (6 of both patterns and 12 controls) were evaluated for bursting pressure. The segment of colon 20 cm in length was removed and contents were flushed out, using dextro-saline solution. The intestine was divided into approximately 10 cm segments, one containing anastomotic site and other was normal intestinal segment which was designated as control. The intestinal segments were immersed in dextro-saline solution until testing. The bursting pressure was evaluated on the technique as described by Levine *et al.* (1988).

RESULTS AND DISCUSSION

In the present study, all the anastomotic techniques were clinically successful. None of the dogs died and returned to normal defaecation, urination, pulse, respiration within 24 hours after surgery.

The mean number of stitches for first layer were 13.00 ± 0.57 and 16.33 ± 0.49 and for 2nd layer 13.17 ± 0.47 and 15.66 ± 0.49 and time taken for first layer of anastomosis were 14.83 ± 0.16 and 19.66 ± 0.33 and for

2nd layer 14.83 ± 0.167 and 14.5 ± 0.34 with INV-2 and APP-2 respectively. The number of stitches and time required for first layer of anastomosis with APP-2 was significantly higher ($P < 0.05$) than INV-2. The mean number of stitches required for closure of second layer with APP-2 was significantly higher ($P < 0.05$) than INV-2 but there was no significant difference in the time required for the closure of second layer. The mean number of stitches and duration to complete the anastomosis were significantly higher ($P < 0.05$) with APP-2 than INV-2 (Table 1).

The first passage of faeces was observed in APP-2 and INV-2 at a mean of 9.00 ± 4.57 hours and 6 ± 2.75 hours, with a return to normal consistency at a mean of 28.41 ± 2.56 hours and 28.16 ± 2.76 hours after surgery respectively. Statistically these findings were not significantly different in both patterns. This is in agreement with the findings of Mausya *et al.* (1984). Blood was evident in first faeces of dogs of group-B. The first urination was observed in APP-2 and INV-2 after a mean period of 3.5 ± 1.06 hours and 4 ± 0.86 hours respectively after surgery (Table 1). There was no significant difference between the mean period and volume of first urine with APP-2 and INV-2 patterns.

Post operative changes in temperature, pulse rate, respiration rate, duration for the passage of first faeces and urine, normal intake of food and defaecation were recorded from day 1 to day 10. However, these were not significantly different among groups.

Hanson *et al.* (1988) had also observed similar observation while comparing appositional single layer, inverting two layer and appositional two layer intestinal end-to-end intestinal anastomotic techniques for colon in horses.

There was no clinical evidence of peritonitis, dehiscence, leakage from anastomotic site, break down/loss of suture line in any dog. This is in agreement with the findings of Scott-Corner and Scher (1968).

Average adhesions were 35 percent at 10th day after surgery with APP-2, where as INV-2 had zero percent adhesions. Adhesions were significantly higher ($P < 0.01$) in APP-2 than INV-2 at 10th day after surgery (Table 1). Most of the adhesions of the INV-2 anastomoses were between the anastomotic line and the adjacent mesentery, where as the APP-2 adhesions were between adjacent loops of colon. Most adhesions were observed within the first 20th days after surgery, had average adhesions 55 and 40 percent with APP-2 and INV-2 respectively (Plate 3). Adhesions were minimal with both pattern evaluated at 30th day after surgery. Average adhesions of 7.5 and 6 percent with APP-2 and INV-2 respectively were observed at 30th day. Adhesions were significantly higher ($P < 0.05$) with APP-2 than INV-2 at 20th and 30th day after surgery (Table 1).

Table 1: Means of parameters recorded with APP-2 and INV-2.

	APP-2	INV-2
	Mean \pm SEM	Mean \pm SEM
No. of stitches (first layer)	16.33 \pm 0.494 **	13.00 \pm 0.578
Duration (min.) for first layer	19.66 \pm 0.333 ++	14.83 \pm 0.478
No. of stitches (second layer)	15.66 \pm 0.494 *	13.17 \pm 0.478
Duration (min.) for second layer	14.50 \pm 0.341	14.83 \pm 0.167
Total duration for anastomosis (min.)	34.16 \pm 0.543 **	29.67 \pm 0.33
Total duration for surgery (min.)	58.66 \pm 0.333 **	53.50 \pm 0.562
First defaecation after surgery (Hrs.)	9.00 \pm 4.57	6.00 \pm 2.75
Normal defaecation after surgery (Hrs.)	28.66 \pm 4.62	28.16 \pm 2.76
Duration to first urination (Hrs.)	03.56 \pm 1.06	4.00 \pm 0.86
Volume of first urination (ml)	13.33 \pm 1.60	16.66 \pm 1.56
Adhesion to the anastomotic site (%)	32.50 \pm 9.104 *	15.33 \pm 8.026
Control lumen diameter (mm)	34.57 \pm 3.57	36.65 \pm 4.94
Anastomotic lumen diameter (mm)	25.70 \pm 1.74 ^	22.35 \pm 1.55
Normal bursting pressure (mm Hg)	206.67 \pm 6.15	205.83 \pm 3.00
Anastomotic colon bursting pressure (mm Hg)	205.83 \pm 31.37	187.50 \pm 33.3

*= significant difference between APP-2 and INV-2 at (P<0.05); **= Significant difference between APP-2 and INV-2 at (P<0.05);

^= significant different from control at (P<0.05).

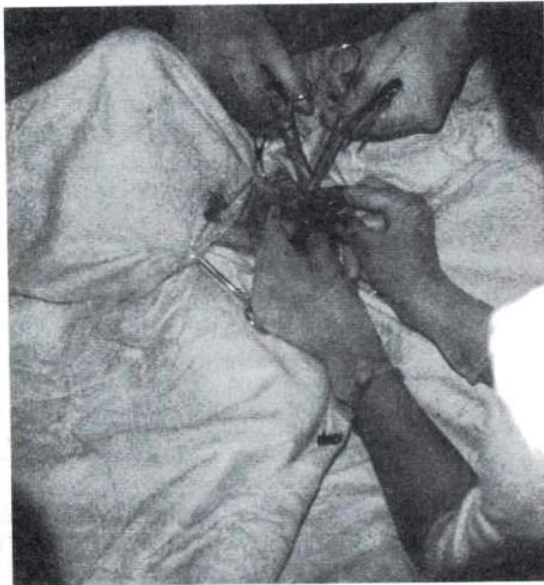

Plate 1: Showing closure of the first layer of Appositional two layer pattern for anastomosis of colon in dog.

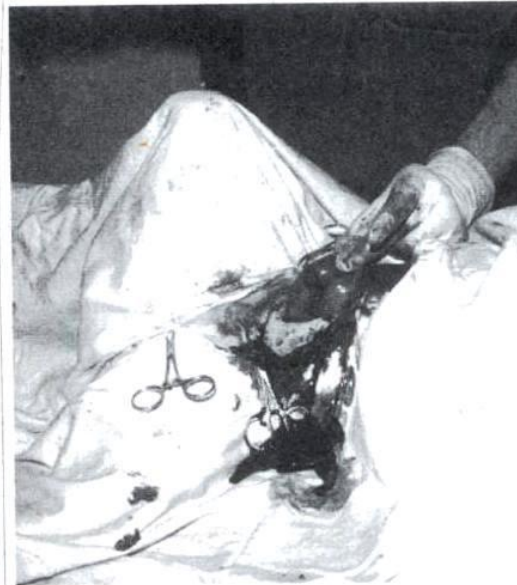

Plate 2: Showing completion of Appositional two layer pattern performed for anastomosis of colon in dog.

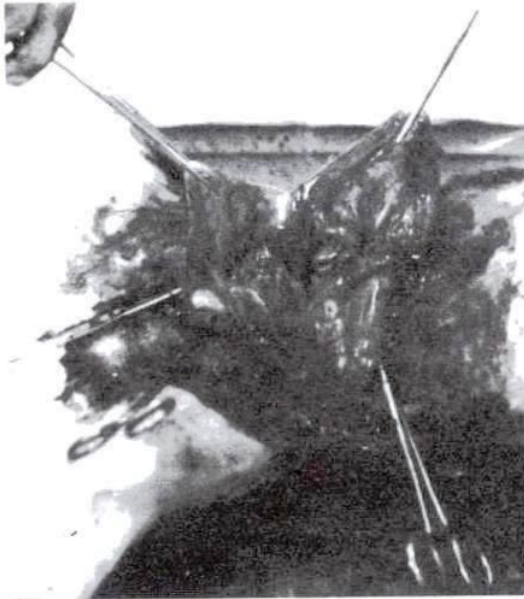


Plate 3: Showing adhesions in dog with APP-2 at 20 days after surgery. Notice adhesions between anastomotic site. Urinary bladder and small intestine

Hanson *et al.* (1988) had also observed similar observation while comparing appositional two layer, inverting two layer and appositional single layer intestinal end-to-end intestinal anastomotic techniques for colon in horses.

Lumen diameters for all anastomosis were smaller than control on 10th, 20th and 30th day in both groups. However, the differences were statistically significant ($P < 0.05$) only on 30th day after surgery as compared to control. The differences between lumen diameter values of APP-2 and INV-2 were not statistically significant on 10th and 20th day after surgery. The lumen diameter of APP-2 was however significantly larger (0.05) than INV-2 on 30th day after surgery (Plate 4).

Hanson *et al.* (1988) had also demonstrated similar observation while comparing INV-2, APP-2 and APP-1 suture techniques for end-to-end intestinal anastomosis of colon in horses.

This study reveals that both techniques are not completely free from complications. Although inverting two layer technique had some advantages like minimal adhesions between anastomotic site and other structures,




Plate 4: Two layer inverting pattern (INV-2) in dog at day 30. Tissue inversion in colon wall is considerable causes lumen narrowing.

less number of stitches and less time required for the closure of anastomosis but appositional two layer technique was superior in the sense that it caused less narrowing of the anastomotic lumen diameter.

REFERENCES

- Annis, J.R. and A.R. Allen, 1961. An Atlas of Canine Surgery. 4th Ed., Lea and Febiger, Philadelphia, U.S.A. pp: 42.
- Armistead, W.W., 1959. Canine Surgery. 4th Ed., Am. Vet. Publ. INC., Santa Barbara, California, U.S.A. pp: 58, 132.
- Griener, T. and T. Christie, 1975. The cecum, colon, rectum and anus. In: Current Technique of Small Animal Surgery. Bojarab, M.J. (Ed.), Lea and Febiger, Philadelphia, U.S.A. pp: 126-133.
- Hanson, R.R., A.J. Nixon, M. Calderwood-Mays, and R. Gronwall, 1988. Evaluation of three suture techniques for end-to-end anastomosis of the small colon in horses. Am. J. Vet. Res. 49: 1613-1620.

- Hawely, P.R., 1973. Causes and prevention of colonic anastomotic breakdown. *Dis Colon Rectum*. 16: 272-277.
- Jiborn, H.J., Ahonen and B. Zederfeldt, 1980. Healing of experimental colon anastomosis. III collagen metabolism in the colon after left colon resection. *Am.J.Surg.* 139: 398-405.
- Keller, H.H. and F.D. Horney, 1985. Diseases of the equine small colon. *Compend. Contin. Educ. Pract. Vet.* 7:5113-5120.
- Larsen, L.H. and C.R. Bllelenger, 1974. Stomach and small intestine. In *Canine Surgery*, 2nd Archibald ed., P-214. ed. Archibald, J., Am. Vet. Publ. INC., Santa Barbara, California, U.S.A.
- Mausya, S.D., H.C. Gupta, A. Tiwari, S.S Khan and B. Sharma, 1984. Double layer versus single layer intestinal anastomosis: Clinical trial. *Int. Surg.* 68: 339-340.
- Nichols, R.I., P. Oroido, R.E. Condon, S.I. Gorbach, and I.M. Nyhus, 1973. Effect of pre-operative neomycin-erythromycin intestinal preparation on the incidence of infectious complications following colon surgery. *Ann. Surg.* 178: 453-462.
- Scott-Corner, C. E. H. and K.S. Scher, 1968. Implications of emergency operations on the colon. *Am. J. Surg.* 153: 535-540.
- Tangner, C.H., 1982. A review of canine intestinal intussusception. *Southwestern Vet.* 34: 203-207.
- White, N. A., 1985. Risk and prognosis of the equine patient with colic. *Proc. Equine Acute Abdomin Seminar. 2nd Equine Colic Symp.* 50-51.