

## COMPARATIVE GROSS ANATOMY OF THE APPENDICULAR SKELETON OF BUFFALOES AND COWS

Faqir Muhammad and Rehmatullah Shahid  
*Department of Veterinary Anatomy, Faculty of Veterinary Science,  
 University of Agriculture, Faisalabad-38040, Pakistan.*

### ABSTRACT

The scapula of the buffalo was more regularly triangular in outline and was relatively wider at vertebral end. The supraspinous fossa was wider than cow. The proximal one-third of the spine of scapula had a distinct tuber. The humerus had a shallow musculo-spiral groove. The groove between two interosseous spaces of radius was deeper. On the ilium the gluteal lines were more prominent. The tuber sacrale was separated from the opposite angle by a wider interval than in the cow. The dorsal border of ilium was almost straight in the buffalo which was undulating in the cow. On the ventral surface of symphysis pubis there were cranial and caudal tuberosities.

**Key words:** Appendicular skeleton, comparative anatomy, buffaloes, cows.

### INTRODUCTION

Skeleton is the frame work of hard structures which protects the soft tissues of animals and provides space for attachment of muscles and ligaments. The literature on anatomical aspects of buffalo is limited therefore, the present study was undertaken to observe the comparative gross anatomical features in the appendicular skeleton of the buffalo and cow.

### MATERIALS AND METHODS

Ten adult buffaloes and cows were slaughtered in the Gross Anatomy Laboratory, Department of Veterinary Anatomy, Faculty of Veterinary Science, University of Agriculture, Faisalabad. After skinning the bones were cleaned, macerated, processed (Young, 1980) and prepared for study.

### RESULTS AND DISCUSSION

#### Bones of Thoracic limb

##### Scapula

The scapula was more regularly triangular in outline and was relatively wider at vertebral end in buffalo (Plate 1) than in the cow. The supraspinous fossa was wider than in cow. The proximal one-third of the spine of scapula had a distinct tuber which was absent in the cow. The areas for the attachment of serratus muscles were distinct in the buffalo and not prominent in the cow. The coracoid process which projected from the medial side of the tuber scapulae was more prominent in the buffalo while it was short and rounded in the cow (Getty, 1975).

##### Humerus

The humerus had a shallow musculo-spiral groove. The deltoid tuberosity was more prominent than in the cow, and the curved line running from the deltoid tuberosity to the neck was very much prominent in buffalo.

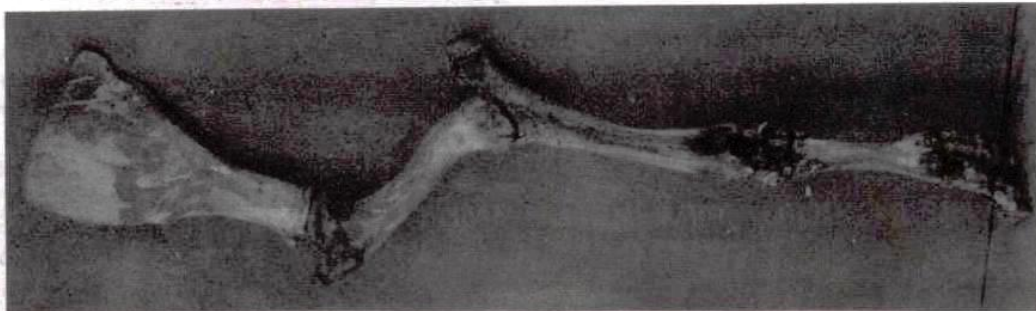


Plate 1: Right forelimb of buffalo (medial view)



Plate 2: Ossa coxarum of buffalo (ventral view).

#### Radius

The groove between two interosseous spaces of radius was deeper (Plate 1). The grooves for the extensor tendons were shallower than in the cow.

#### Ulna

The olecranon was quadrangular and bore a large rounded tuberosity in buffalo than in the cow (Bone, 1988).

No significant differences were observed in the carpus of the buffalo and cow. The shaft of large metacarpal was wider and flatter. The phalanges of the buffalo and cow were almost similar.

#### Bones of Hind Limb

##### Os-Coxae

On the ilium the gluteal lines were more prominent in the buffalo than in the cow. The tuber sacrale was separated from the opposite angle by a wider interval than in the cow. In buffalo, the tuber coxae had rounded tuberosity in the middle (cranially) while in the cow, there was a tuber which was wide in the middle and smaller at either ends.

The dorsal border of ilium was almost straight in buffalo which was undulating in cow. The wings of ilium were wider than in the cow (Plate 2).

On the tuber-ischii, the ventral tuberosity was farther away from the dorsal and lateral tuberosities in the buffalo while in the cow all three tuberosities were located at equal distance. The ischial arch was deeper than in the cow (Getty, 1975). On the ventral surface of symphysis pubis, there were cranial and caudal tuberosities. Both internal and external pelvic diameters were found to be larger in the studied buffaloes than in the cow as reported by (Dhaliwal *et al.*, 1981). No significant differences were observed in rest of the bones of hind limb.

#### REFERENCES

- Bone, F., 1988. Animal Anatomy and Physiology, 3rd Ed. Engle wood cliffs. New Jersey, USA.
- Dhaliwal, A.S., Y.G. Sekar and R.D. Sharma, 1981. In vivo pelvimetry in buffaloes. *Theriogenology*, 15(5): 501-504.
- Getty, R., 1975. The anatomy of the domestic animals. Vol. 1, 5th Ed. W.B. Saunders Company, Philadelphia, London.
- Young, J.H., 1980. Preparation of a skeletal specimen. *Equine Practice*, 2: 29.