

## CLINICO-THERAPEUTIC STUDIES ON CANINE TRANSMISSIBLE VENEREAL TUMOUR

M. Athar, A. Suhail, G. Muhammad, A. Shakoor and F. Azim

Faculty of Veterinary Science, University of Agriculture, Faisalabad 38040, Pakistan

### ABSTRACT

Ten-bitches and 8-male dogs afflicted with transmissible venereal tumour (TVT) randomly divided into 3 groups viz. Group-I, Group-II and Group-III comprising 6 dogs each, were subjected to three different protocols. Group-I was treated surgically. A complete regression of the tumour mass was observed in 4 (66.67%) dogs, while 2 (33.34%) had incomplete regression at the end of first 5 weeks. A 16.67% recurrence rate was also observed at the end of 6 months study period. In Group-II, chemotherapy with intravenous injection of vincristine sulphate @ 0.025 mg/kg b.wt. affected 80.33% (n=5) complete regression whereas incomplete regression was recorded in only one (16.67%) subject at the end of 5<sup>th</sup> week. Vomiting and inappetance as side-effects were also noticed. Group-III was subjected to a combination of surgery and chemotherapy where vincristine sulphate was used after surgical debulking of tumour mass. A 100% regression even after 2-3 injections with no recurrence was achieved till 6 months post-treatment. There was a significant increase ( $P \leq 0.01$ ) in erythrocyte sedimentation rate and total leukocyte count (TLC) in TVT-afflicted dogs which returned to normal after 2-5 weeks of treatment. Vincristine sulphate had a significant decreasing effect on TLC in both Group-II and Group-III, which was transient.

**Key words:** Transmissible venereal tumour; Vincristine; Oncology; Cancer therapy.

### INTRODUCTION

Among the commonly encountered afflictions of dogs, transmissible venereal tumour (TVT) is a naturally occurring, coitally-transmitted neoplastic disorder that affects the external genitalia of both sexes, vulva and vagina in females; penis and prepuce in male dogs (Vermooten, 1987). Metastasis to other tissues (skin, nasal passage, oral cavity, etc.) has been seen in about 5-6.9 percent of the cases (Oduye *et al.*, 1973; Das *et al.*, 1990). A recent report from Portugal has indicated brain and ocular metastases in a dog afflicted with TVT (Ferreira *et al.*, 2000) Although, this tumour can be treated surgically, frequent recurrence following surgery (Catinelli *et al.*, 1978) due to the growth of the residual tumour warrants the use of some alternative method which could be curative even when the tumour has infiltrated to adjacent tissues or metastasized to other organs. Furthermore, surgery is a difficult proposition in field situations where facilities even for minor surgical manipulations are lacking. Chemotherapy with anticancer drugs like vincristine sulphate holds the promise of a suitable alternative to surgery (Brown *et al.*, 1980; Singh *et al.*, 1996). Present study was thus planned to evaluate the comparative recovery rates of surgery and vincristine sulphate, alone and in combination in the therapy of TVT.

### MATERIALS AND METHODS

#### Patients and Diagnosis of TVT

Eighteen dogs (10 females and 8 males) brought to the outdoor clinics of the Department of Veterinary Clinical Medicine and Surgery, University of Agriculture, Faisalabad with a history of serosanguineous discharge and presence of granulomatous (tumorous) lesion(s) in and around their genitalia were selected and included in this study. The diagnosis of the condition rested on pathognomonic signs and histopathology (Sandritter & Wartman, 1969). To this end,  $1 \times 1 \text{ cm}^2$  biopsy specimens from granulomatous lesions were collected from each dog under study and preserved in 10 per cent neutral buffered formalin. Each specimen was then processed for histopathologic examination to see any change both at tissue ( $\times 100$ ) and cellular levels ( $\times 400$ ).

#### Treatment Protocols

The patients were divided randomly into three groups viz. Group-I, Group-II and Group-III, each comprising 6 subjects. The dogs in Group-I were treated surgically by debulking (removal) of the tumorous mass (Bojrab, 1997). Dogs in Group-II were treated with a chemotherapeutic agent viz. vincristine sulphate, whereas dogs in Group-III were subjected to a combination protocol of surgery and chemotherapy.



Vincristine sulphate was used after the surgical debulking of the tumourous mass. In the later two groups, vincristine sulphate (Oncovin - Lilly, France) was used as 0.01% solution @ 0.025 mg/kg b.wt. by slow intravenous injection (Ganesh *et al.*, 1993; Barragry, 1994). Vincristine sulphate therapy was repeated at weekly intervals for 5 consecutive weeks.

#### Haematologic Examination

Blood samples from all subjects were collected for complete haematologic examination including total erythrocyte (TEC) and leukocyte (TLC) counts, haemoglobin concentration (Hb), packed cell volume (PCV), and erythrocyte sedimentation rate (ESR) both in pre-treatment and post-treatment time points (Benjamin, 1978). Pre-treatment values were compared with those of post-treatment values recorded at day 15, 29, and day 43.

#### Response to the treatment

Response of a treatment protocol was evaluated on the basis of the regression of tumour size, effect on various haematologic parameters (TEC, TLC, PCV, Hb, ESR), and recurrence during first 6 months post-treatment. The data, thus collected, were subjected to statistical analysis (Steel and Torrie, 1980). Side-effects and any untoward sequelae of surgery and/or chemotherapy, if any, were also recorded. A final examination of the subjects was conducted 6 months after the treatments for evaluating the recurrence rate.

## RESULTS

#### Pre-treatment clinical findings

Transmissible venereal tumours (TVT) were rounded to diffused swellings and appeared to be lobulated, cauliflower-like red to grayish-pink mass. In females (n=10), the tumour was located in the vestibule (n=1; 10%), in both vulva and vagina (n=5; 50%) and in the vagina (n=4; 40%) (Plate 1). Whereas in males (n=8), tumours were located on the posterior portion of the penis (n=4; 50%) on the preputial mucosa (n=1; 12.5%) and in both prepuce and penis (n=3; 37.5%) (Plate 2). Metastasis to the regional (inguinal) lymph nodes was recorded in only one (5.56%) subject whereas two subjects (11.12%) were found to have metastasis in the nasal chamber. Bleeding and sneezing was evident from nostrils in these two dogs. On histopathological examination, haematoxylin-eosin stained biopsy samples revealed sheets of cells appearing uniformly in size, fibrous stroma distributed unevenly, plenty of newly formed blood vessels, and pleomorphic nuclei (Plate 3). At high magnification, prominent nuclei, frequent mitotic figures and cellular

infiltration mainly of lymphocytes were also seen (Plate 4).

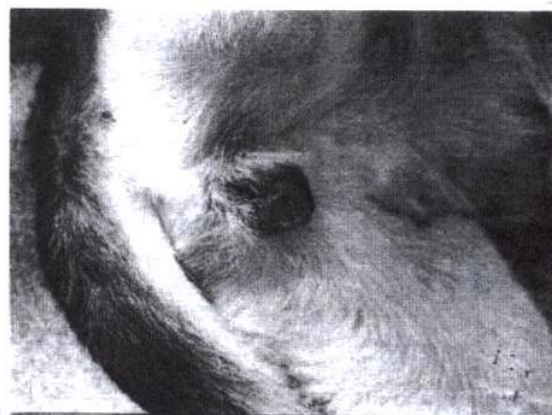

Plate 1: Transmissible venereal tumour in a female dog. A cauliflower-like granulated mass protruding out of the vulva.

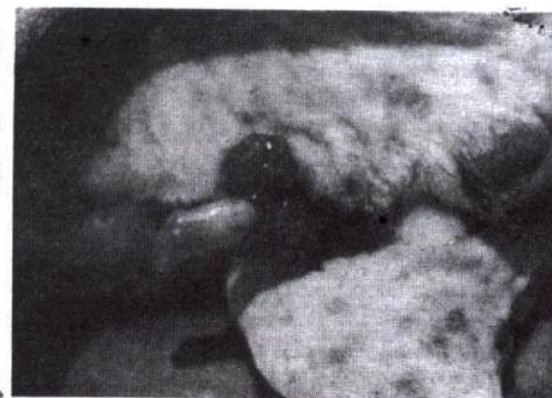

Plate 2: Transmissible venereal tumour in male dog. Note the involvement of shaft of penis and prepuce.

#### Treatment response

In Group-I, complete surgical excision of tumour mass could be performed in 4 (66.67%) of 6 subjects, whereas in the remaining two subjects, extensive involvement of the surrounding tissues and inaccessible sites made complete surgical excision not achievable. When re-examined 6 months later, 5 had complete regression while recurrence was observed in one (16.67%) subject only (Table 1).

Of the six subjects treated with vincristine sulphate (Group-II), 5 had complete regression of the lesion following 3-5 injections at weekly intervals (Table 1). Majority of dogs (n=3) recovered completely with 4 injections whereas in one dog, complete recovery was



achieved after 3 and in the 5<sup>th</sup> dog after completing 5 injections. In the remaining one case, although the regression was incomplete, but a significant regression ( $P \leq 0.05$ ) in the tumour size was observed after the completion of 5 injections course. In none of the dogs vincristine was administered beyond 5<sup>th</sup> week. No recurrence was observed in any of the dog till 6 months post-vincristine sulphate therapy. Vomiting and inappetence were recorded in one dog each during first 48 hours.

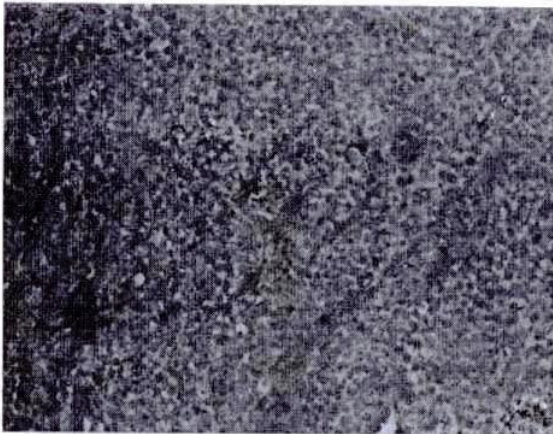


Plate 3: TVT-sheets of uniform cells with unevenly distributed fibrous stroma, angiogenesis and pleomorphic nuclei (x100)

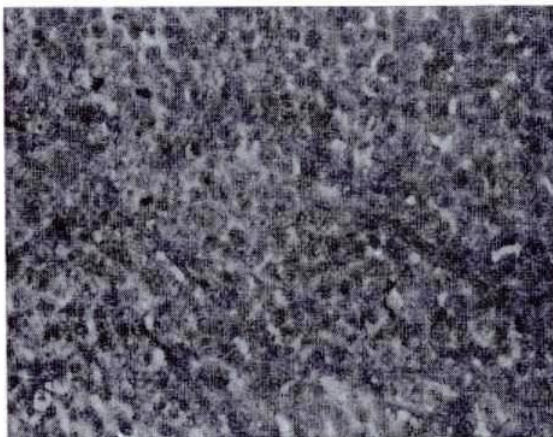


Plate 4: TVT-prominent nuclei, frequent mitotic figures and cellular infiltration mainly of lymphocytes (x400)

In Group-III, a maximum of 3 injections of vincristine sulphate were used following surgical debulking of the tumour mass in two of the afflicted

dogs. In the remaining four dogs, chemotherapy was discontinued after only two injections as the lesions had completely regressed. None of the animals showed any untoward response. At the end of 6 months study period, final clinical examination did not reveal any tumourous growth in and around their genitalia (Table 1).

#### Haematological values

No significant change in the TEC from normal as well as difference among groups was observed when haematologic examination carried out before the initiation of any treatment protocol. A significant ( $P \leq 0.05$ ) rise in TLC was noticed in all 3 groups before the initiation of any treatment protocol (Table 2). When observed during the post-therapy period of 6 weeks, a significant fall ( $P \leq 0.05$ ) in TLC was recorded in all three groups, especially in Groups-II and III where it reduced to  $6.97 \pm 5.12$  and  $6.78 \pm 1.26$  thousands per microlitre, respectively ( $P \leq 0.01$ ). No significant change from normal and difference among all three groups was observed in PCV before and after the initiation of treatment. A similar non-significant change from normal and difference among all three groups was observed in haemoglobin concentration before and after the initiation of treatment. A significant rise ( $P \leq 0.01$ ) in ESR values ranging from  $38.00 \pm 9.30$  to  $42.20 \pm 18.00$  was observed in all three groups when proceeded before treatment. After two weeks of the initiation of therapy, a significant ( $P \leq 0.05$ ) fall in ESR values was observed in all three groups which did not differ significantly amongst them (Table 2). At the end of 6 weeks period, all the groups had a significantly low, almost normal ( $P \leq 0.01$ ) ESR values which differed non-significantly amongst the groups.

#### DISCUSSION

In the present study, the lesions of transmissible venereal tumours (TVT) in male dogs were confined to penis and prepuce whereas in bitches, vagina, vestibule, and vulva were commonly involved sites. These findings are in line with those of Sbernadori *et al.* (1973), Spence *et al.* (1978), and Gordon and Bruce (1979). Metastasis occasionally occurs to the inguinal lymph nodes, skin, spleen, liver, and lungs, and appears to be mainly by lymphatic pathway or by oral implantation (McLeod and Lewis, 1972; Oduye *et al.*, 1973; Das *et al.*, 1991; Ayyappan *et al.*, 1994). Das *et al.* (1991) reported a metastasis of 6.9% developed elsewhere in the body. In the present study, metastasis could be detected in 2 (11.12%) of the 18 subjects which is lower than that of Das *et al.* (1991).



Table 1: Comparison of different treatment protocols of TVT in dogs

Group No.	Total No. of Dogs	Regression in tumour mass at 5 weeks				Recurrence after 6 months	
		Complete		Incomplete			
		No. of dogs	%	No. of dogs	%	No. of dogs	%
I	6	4	66.67 <sup>c</sup>	2	33.33	1	16.67 <sup>a</sup>
II	6	5	80.33 <sup>b</sup>	1	16.67	0	0.00 <sup>b</sup>
III	6	6	100.00 <sup>a</sup>	0	0.00	0	0.00 <sup>b</sup>

Group-I = Surgery only Group-II = Vincristine sulphate Group-III = Surgery + vincristine sulphate

Table 2: Effect of surgery and vincristine sulphate alone and in combination on total leukocyte counts and erythrocyte sedimentation rates

Total Leukocyte Count ( $\times 10^3/\text{mm}^3$ )			
Weeks	Group-I	Group-II	Group-III
0 (Pre-treatment)	10.06 <sup>a</sup> $\pm$ 3.11	10.81 <sup>a</sup> $\pm$ 3.21	9.97 <sup>a</sup> $\pm$ 2.60
2 (Post-treatment)	9.65 <sup>a</sup> $\pm$ 2.11	6.65 <sup>c</sup> $\pm$ 5.34	6.89 <sup>c</sup> $\pm$ 3.42
4 (Post-treatment)	8.50 <sup>ab</sup> $\pm$ 1.51	6.89 <sup>c</sup> $\pm$ 4.62	6.54 <sup>c</sup> $\pm$ 1.92
6 (Post-treatment)	8.10 <sup>b</sup> $\pm$ 0.98	6.97 <sup>c</sup> $\pm$ 5.12	6.78 <sup>c</sup> $\pm$ 1.26
Erythrocyte Sedimentation Rate (mm / 1 <sup>st</sup> hour)			
Weeks	Group-I	Group-II	Group-III
0 (Pre-treatment)	42.20 <sup>a</sup> $\pm$ 18.00	47.80 <sup>a</sup> $\pm$ 13.50	38.00 <sup>a</sup> $\pm$ 9.30
2 (Post-treatment)	20.10 <sup>b</sup> $\pm$ 11.00	13.00 <sup>b</sup> $\pm$ 8.90	15.00 <sup>b</sup> $\pm$ 4.30
4 (Post-treatment)	2.80 <sup>c</sup> $\pm$ 1.70	2.70 <sup>c</sup> $\pm$ 3.60	4.70 <sup>c</sup> $\pm$ 2.90
6 (Post-treatment)	2.40 <sup>c</sup> $\pm$ 1.10	2.20 <sup>c</sup> $\pm$ 2.70	3.60 <sup>c</sup> $\pm$ 2.10

Group-I = Surgery only Group-II = Vincristine sulphate Group-III = Surgery + vincristine sulphate

On histopathologic examination, cells were found present in the form of uniform sheets with prominent pleomorphic nuclei and mitotic activities. Cytoplasmic vacuolation and fibrous stroma was distributed unevenly. These findings which formed the basis of confirmatory diagnosis of TVT in the present study are congruous with the description given by previous workers (Hill *et al.*, 1984; Morgan, 1992; Dinesh *et al.*, 1993; Ayyapan *et al.*, 1994).

Although surgery is the most widely used method in the treatment of TVT, inaccessibility of the site, incomplete excision, and metastasis may explain the recurrence of the TVT following surgery (Catinelli *et al.*, 1978). In the present study, of the six dogs treated surgically (Group-I), the tumour mass could not be completely excised in two bitches where the lesion was inaccessible due to its spread to the surrounding tissues as well as the cervix. Even complete episiotomy incision could not help. Of these two cases, at the end of 6 months study period, one had completely regressed lesion whereas the other had the regeneration. This post-operative self-regression may be due to the provocation of the body's own immune system with the release of tumour cells in the circulation and ensuing lymphoblastogenesis as well as humoral response. The recurrence could be due to a weak lymphoblastogenic response (Morgan, 1992).

Owing to the minor side-effects, vincristine sulphate, an alkaloid isolated from *Vinca rosea*, has also been widely used anticancerous drug in veterinary

practice. It is an antimitotic agent which prevents mitosis by abolishing spindle formation (Barragry, 1994). When using vincristine sulphate @ 0.025 mg/kg b.wt, in the dogs of Group-II, complete regression was observed in 5 (80.33%) of six dogs and in one dog (16.67%) incomplete but significant regression was observed after the completion of 5 injections course. Majority of dogs (n=3) recovered completely with 4 injections where as in the remaining two cases, complete recovery was achieved after 3 and 5 injections, respectively. No recurrence was observed in any of dog treated with vincristine sulphate till 6 months post-treatment. Vomiting and inappetance was observed in one dog each during first 48 hours. In the combination protocol (Group-III) where injections of vincristine sulphate were used following surgical excision of tumour mass, 100% regression was observed. In none of the dogs of this group, vincristine was used for more than 3 times. This would not only lead to a hastened recovery in the affected dogs but also would try to minimize the potential risks involved in the anticancer drug therapy i.e., severe leukopenia, thrombocytopenia, etc. to name a few (Barragry, 1994). No such report regarding the combination mode of therapy could be found from the available literature.

The increase in ESR and TLC is due to some inflammatory or pathological process going on in the body (Benjamin, 1978). Vincristine sulphate has a significant decreasing effect on TLC which is usually transient (Ganesh *et al.*, 1993). This is also consistent



with the findings of the present study where in Group-II and Group-III, TLC was significantly lower following the injections of vincristine sulphate. A non-significant decrease in TEC and haemoglobin before treatment might be due to chronic loss of blood from the ulcerating surfaces of tumour mass (Maiti *et al.*, 1995).

In conclusion, surgery plus vincristine sulphate (a combination therapy) seems most suitable and practical protocol for the therapy of transmissible venereal tumours in dogs. In the field situations, where surgical facilities are almost non-existent, chemotherapy with vincristine sulphate (as in Group-II) seems to be a more promising way of treatment than surgical intervention. Although we used Oncovin (an expensive French brand), Chinese (Vincristine) and/or Hungarian (Vincritin) brands, which are cheaper, could possibly have been substituted.

## REFERENCES

- Ayyappan, S., R.S. Kumar, T.N. Ganesh, and W.P.A. David, 1994. Metastatic transmissible venereal tumour in a dog—a case report. *Indian Vet. J.*, 71:265–266.
- Barragry, T.B., 1994. *Veterinary Drug Therapy*. Lea and Febiger, Philadelphia. pp. 919–939.
- Benjamin, M.M., 1978. *Outline of Veterinary Clinical Pathology*. 3<sup>rd</sup> Ed., The Iowa State University Press, Ames, Iowa, USA.
- Bojrab, I.M., 1997. *Current Techniques in Small Animal Surgery*, 2<sup>nd</sup> Ed., Lea & Febiger, Philadelphia.
- Brown, N.O., C. Calvert, and E.G. MacEwen, 1980. Chemotherapeutic management of transmissible venereal tumours in 30 dogs. *J. Am. Vet. Med. Assoc.*, 176:983–986.
- Catinelli, M., M. Herceg, and Z. Bacetic-Kovac, 1978. Transmissible venereal tumour of dogs and the possibility of its surgical treatment in bitches. *Veterinarski Arhiv.*, 48:157–162.
- Das, A.K., D. Utpal, and D. Deb Kumar, 1991. A clinical report on the efficacy of vincristine on canine transmissible venereal sarcoma. *Indian Vet. J.*, 68:575–556.
- Das, A.K., U. Das, D. Das, and J. Sengupta, 1990. Histopathological study of canine transmissible venereal tumour. *Indian Vet. J.*, 67:473–474.
- Dinesh, N.M., B.N. Ranganath, S.M. Jayadevappa, and C.L. Srinivas, 1993. Gross and microscopic changes in transmissible venereal tumour following vincristine sulphate therapy. *Indian Vet. J.*, 70:609–611.
- Ferreira, A.J., A. Jaggy, A.P. Varejae, M.L. Ferreira, J.M. Correia, J.M. Mulas, O. Almeida, P. Oliveira, and J. Prada, 2000. Brain and ocular metastases from a transmissible venereal tumour in a dog. *J. Small Anim. Pract.*, 41(4):165–168.
- Ganesh, T.N., B.R. Kumar, W.P.A. David, N.N. Balasubramanian, S.R. Pattabiraman, and M.S.D.M. Mohammed, 1993. Clinical trial on the effect of vincristine on transmissible venereal tumours in dogs. *Indian Vet. J.*, 70:559–561.
- Gordon, T.H., and R.M. Bruce, 1979. *Veterinary Cancer Medicine*. Lea & Febiger, Philadelphia. pp: 171–177.
- Hill, D.L., T.J. Yang, and A. Wachtel, 1984. Canine transmissible venereal sarcoma: tumour cells and infiltrating leukocyte ultrastructure at different growth stages. *Vet. Pathol.*, 21:39–45.
- Maiti, S.K., S. Roy, S.L. Ali, and R.C. Ghosh, 1995. Therapeutic management of transmissible venereal tumour with vincristine in a dog—a case report. *Indian Vet. J.*, 72:614–615.
- Morgan, R.V., 1992. *A Handbook of Small Animal Practice*. 2<sup>nd</sup> Ed., Chirchill Livingstone, London. pp: 672–673.
- Oduye, O.O., B.O. Ikede, G.O. Esuruoso, and J.U. Akpokodje, 1973. Metastatic transmissible venereal tumour in dogs. *J. Small Anim. Pract.*, 14:625–637.
- Sandritter, W., and W.B. Wartman, 1969. *Atlas and Textbook of Tissue and Cellular Pathology*. 3<sup>rd</sup> Ed., Edi Yearbook Med. Pub. Inc., Chicago. pp: 2–4.
- Sbernordori, U., 1973. [Frequenza di determinate localizzazioni del tumore venereodel cane in relazione all' eta del soggetto]. *Nouova Vet.*, 19: 315.
- Singh, J., J.S. Rana, N. Sood, G.R. Pangawkar, and P.P. Gupta, 1996. Clinico-pathological studies on the effect of different anti-neoplastic chemotherapy regimens on transmissible venereal tumours in dogs. *Vet. Res. Commun.*, 20(1):71–81.
- Spence, J.A., P.E. Holt, P.D. Sayer, D. Her, and J.E. Cooper, 1978. Metastasis of a transmissible venereal tumour to the pituitary. *J. Small Anim. Pract.*, 19:175–184.
- Steel, R.G.D., and J.H. Torrie, 1980. *Principles and Procedures of Statistics*. 2<sup>nd</sup> Ed., McGraw Hill Book Co. Inc., New York, USA.
- Vermooten, M.I., 1987. Canine transmissible venereal tumour (TVT): A review. *J. S. Afr. Vet. Assoc.*, 58:147–150.