

## SURGICAL RECTIFICATION OF THREAD-ASSOCIATED GLOSSOPTOSIS IN PEAFOWLS

M. Athar, A. Shakoor, G. Muhammad, M.N. Asi, and M. Saqib

Department of Clinical Medicine and Surgery, University of Agriculture, Faisalabad-38040, Pakistan

### ABSTRACT

Domesticated and/or caged peafowls (*Pavo cristatus*) and other fancy birds suffer from a variety of disease conditions due to unnatural habitat and suboptimal managerial practices. The present article describes glossoptosis (downward displacement of tongue) in four juvenile peafowls caused by kite-flying thread wrapped around the base of tongue and terminating somewhere in the lower gastrointestinal tract. The condition was characterized by difficulty in swallowing, chronic inappetance, gasping and a fading body condition. Severing of the proximal part of thread through crop and then unwinding it from the base of the tongue affected an instant relief. As far as could be ascertained, the condition under reference has not been reported heretofore in birds especially in peafowls.

**Key Words:** Peafowls; *Pavo cristatus*; glossoptosis; tongue diseases; ingluviotomy.

### INTRODUCTION

Four juvenile peafowls, aged 2½ to 6 months, were brought to the outdoor clinics of the Department of Clinical Medicine and Surgery for the treatment of a bizarre ailment i.e., downward displacement of tongue in the oral cavity. According to the owners, the birds had been suffering from this problem for periods varying from 1 to 2 months. Owing to the 'retraction of the tongue', the birds would experience difficulty in swallowing accompanied by gasping respiration and a fading body condition.

### CLINICAL EXAMINATION

All the four peafowls were found to have cachectic and despondent appearance with ruffled feathers. On preliminary assessment, the tongues of the birds were not found located in the oral cavities. However, on a closer examination, the tongue along with laryngeal apparatus was found present in the lower pharyngeal region. On further exploration in two birds, tongues could hardly be seen through the open beaks (Plate I), but it was not possible to bring the tongues back to their normal anatomical location. It seemed as if the tongues had been retracted back in the lower pharyngeal regions by something pulling on it. Further examination revealed a tense thread-like material traversing along the trachea/oesophagus. The distress of the birds would accentuate when the thread was pulled or touched. Palpation of the crop revealed the same thread-like structure present not only in it but also extending on to

the distal digestive tract chambers (proventriculus, etc). However, the exact termination point of the thread could not be ascertained. As the birds remained off-feed most of the time, the crop was either empty or had only scanty contents which were sloppy.

### DIAGNOSIS

On the basis of the clinical assessment described above, a presumptive diagnosis of glossoptosis (retraction of the tongue back in the pharynx due to a piece of thread wrapped around the base of the tongue) was reached. It was further assumed that when free end of this thread reached in the proventriculus or gizzard, the peristaltic movements started causing further pulling effect on the tongue hence leading to more agony of the birds (Fig. 1 and 2).

### CONFIRMATORY DIAGNOSIS AND SURGICAL RECTIFICATION

A 1-1½ inch longitudinal incision was given on skin over the crop region, following which the crop was opened by a similar longitudinal incision ingluviotomy and explored (Venugopalan, 1986). Thread was found passing from oesophagus through to the next chambers. Association of thread with retraction of the tongue was confirmed by pulling the thread *per crop* and feeling the movement of the tongue and laryngeal apparatus. Two of the peafowls revealed the distally traversing segments of thread transformed into a trichobozoar-like mass when pulled from either proventriculus or gizzard

whereas in the other two, it was not possible to see the distal end of the threads as it might have been trapped in the lower gastrointestinal tract.

The thread was then cut as high as possible through the crop. As soon as it was cut, the tongue relaxed and gradually restored back to its anatomical location in the oral cavity. The birds started respiring normally and became significantly relieved. The crop wound was then closed by simple interrupted approximating suture pattern using 3/0 chromic catgut followed by a similar suturing of the skin using a similar gauge surgical silk. Proximal part of the thread was then searched through the opened beak of the birds and removed by unwinding the thread from around the base of tongue. In two of the birds, it was found that a further delay in this relieving operation would easily lead to the sawing through the base of the tongue by these culprit threads and hence leading to the death of the birds.

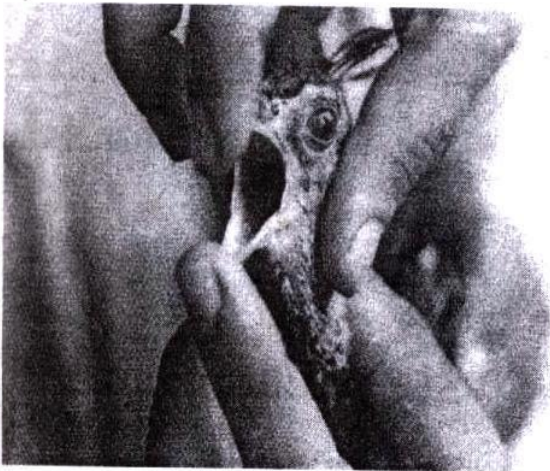

Plate 1: Glossoptosis (downward displacement of tongue) due to a kite-flying thread in a peafowl

### POST-OPERATIVE MANAGEMENT AND OBSERVATIONS

The owners were asked to keep the operated birds on the neat and clean places where such thread-like materials are not accessible to the birds. Daily antiseptic dressing was carried out by povidone-iodine application on cutaneous wounds. The operated birds started taking the normal amount of feed within a period of 12-36 hours. Recovery remained uneventful in all the birds and skin stitches were removed after 7 days. On this day, it was found that tongues were present at their normal anatomical location with significantly improved physique of the birds.

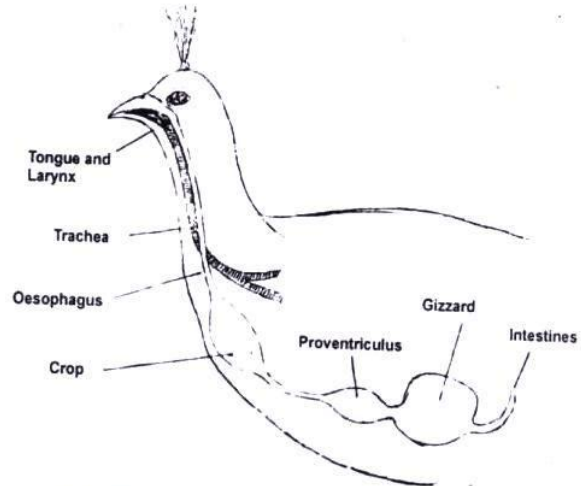


Fig. 1: Schematic representation of the normal anatomical position of tongue/larynx

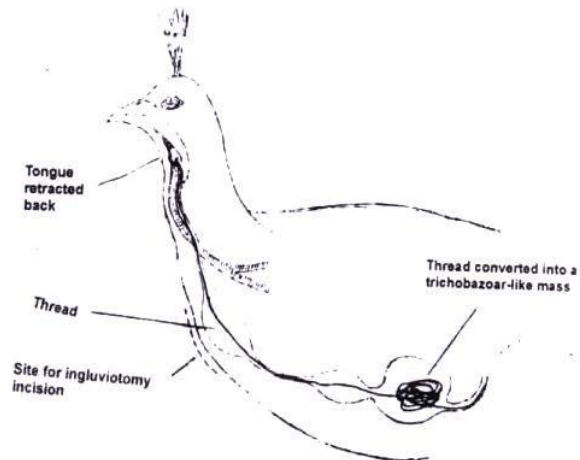


Fig. 2: Schematic representation of the downward displacement of tongue (glossoptosis) by a kite-flying thread in the peafowl (The line in the red ink represents the thread).

## DISCUSSION

Birds are the most commonly kept non-domesticated animals in Pakistan and include mainly species of the orders *Psittaciformes*, *Passeriformes* and *Galliformes*. There are now large collections of different species in zoological parks and private bird gardens throughout Pakistan. Of these species, peafowl (*Pavo cristatus*) is the most liked as fancy and pet bird (Athar *et al.*, 1996). Though people try their level best to keep these birds healthy, yet due to their unnatural habitat and suboptimal management practices, these birds keep on suffering from a variety of medical and surgical maladies (Peckham, 1984). The condition i.e., glossoptosis associated with thread is one of such managemental problems of caged birds which can end up catastrophically, if not rectified. As far as could be ascertained, this condition has not been reported heretofore in birds at the very least in peafowls.

During a span of 3 years, we have rectified this problem in 4 juvenile peafowls ageing between 2½ and 6 months. Adult birds have not been found to suffer from this life-threatening condition. We surmise that an inherent proclivity of birds to pick and/or attack any snake- or earthworm-like object was responsible for picking loose threads from the ground. An interesting feature of these cases was that all birds reached us during the months April-May which closely approximates to kite-flying season ('Basant') in February-March in this part of the world. Therefore, this strong association warrants the management of these birds with more intensive measures during kite-flying season. Any access to kite-flying or other threads littered in the surrounding may easily lead to such a potentially fatal condition.

Owing to the cicatricial sequels of oesophageal surgery, the relieving operation was performed through the dilated portion of the oesophagus i.e., crop. The procedure for opening the crop (ingluviotomy) as described by Venugopalan (1986) was followed which healed up afterwards without any untoward consequence. Anaesthesia was neither required nor used as it might have lead to the worsening of the gasping and despondent demeanour of the afflicted birds.

## REFERENCES

- Athar, M., A. Shakoor, G. Muhammad, M.N. Sarwar, and N.I. Chaudhry, 1996. Clinical perspectives of intravenous ketamine anaesthesia in peafowl (*Pavo cristatus*). *Acta Veterinaria Hungarica*, 44(3):357-61.
- Peckham, M.C., 1984. Vices and miscellaneous diaseses and conditions. In Hofstad, M.S., H.J. Barnes, B.W. Calnek, W.M. Reid, and H.W. Yoder Jr. (eds.): *Diseases of Poultry*, 8<sup>th</sup> Ed. Iowa State Univ. Press, Ames, Iowa. pp.741-82.
- Venugopalan, A., 1986. Surgical conditions affecting birds. Chap. 52. In: *Essentials of Veterinary Surgery*, 5<sup>th</sup> Ed. Oxford & IBH Publishing Co., New Delhi. pp: 418.