



RESEARCH ARTICLE

Protective Effect of Bajakah Tampala (*Spatholobus littoralis* Hassk.) on Dexamethasone-Induced Renal Toxicity in Albino Rats

Tata Anfarul Akmal¹, Cahya Farah Dina¹, Aditya Yudhana¹, Faisal Fikri^{1*}, Agus Purnomo², Salipudin Tasil Maslamama³ and Muhammad Thohawi Elziyad Purnama^{1,3}

¹Department of Veterinary Science, Faculty of Health, Medicine, and Life Sciences, Universitas Airlangga, Banyuwangi, Indonesia

²Department of Veterinary Surgery and Radiology, Faculty of Veterinary Medicine, Universitas Gadjah Mada, Yogyakarta, Indonesia

³Department of Biology, Graduate School of Natural and Applied Sciences, Eskişehir Osmangazi Üniversitesi, Eskişehir, Türkiye

*Corresponding author: faisalfikri@fkh.unair.ac.id

ARTICLE HISTORY (24-111)

Received: February 29, 2024

Revised: April 19, 2024

Accepted: April 24, 2024

Published online:

Key words:

Bajakah tampala

Dexamethasone

Drug safety

Renal toxicity

Spatholobus littoralis Hassk

ABSTRACT

This study aimed to investigate the efficacy of bajakah tampala (*Spatholobus littoralis* Hassk.) extract on IL-1 and IL-6 cytokine expression, renal histopathology, and hematological profile in albino rats suffering from dexamethasone-induced renal toxicity. A total of 25 male rats were divided into five groups, each with five replications i.e. (C-) placebo, (C+) animals were injected subcutaneously with 0.1 mg/kg BW of dexamethasone, (T1; T2; T3 groups) animals were injected subcutaneously with 0.1 mg/kg BW of dexamethasone, and administered orally with 200; 300; 400 mg/kg BW of *S. littoralis* Hassk extract, respectively. A subcutaneous injection of 0.1 mg/kg BW of dexamethasone followed by an oral dose of *S. littoralis* Hassk extract was administered three times a week consecutively for 30 days. IL-1 and IL-6 expressions were evaluated using immunohistochemical staining, renal histopathology using H&E staining, while the hematological profile was quantified using a hematological analyzer. As a result, comparing the T2 and T3 groups to the C+ group, there was a significant decrease in the expression of IL-1 and IL-6. Meanwhile, the T3 group displayed results similar to the C- group. Based on histological findings, the T2 and T3 groups showed significant improvements when compared with C+ group. Furthermore, the T3 group's study of the hematological profile showed a significant improvement in leukocyte, erythrocyte, platelet, BUN, uric acid and creatinine levels when compared with the C+ group. In conclusion, the administration of 300 mg/kg BW of *S. littoralis* Hassk extract has the potential to mitigate renal toxicity caused by dexamethasone, as evidenced by improvements in IL-1 and IL-6, renal histology, and hematological profile.

To Cite This Article: Akmal TA, Dina CF, Yudhana A, Fikri F, Purnomo A, Maslamama ST and Purnama MTE, 2024. Protective effect of bajakah tampala (*Spatholobus littoralis* Hassk.) on dexamethasone-induced renal toxicity in albino rats. Pak Vet J. <http://dx.doi.org/10.29261/pakvetj/2024.173>

INTRODUCTION

Among the most widely used drugs in the world, glucocorticoids are useful for treating a wide range of allergic and immunological disorders (Cain and Cidlowski, 2017). Long-term corticosteroid exposure was linked to several frequently reported adverse events, such as hypertension (prevalence >30%), cataracts (1–3%), bone fractures (21–30%), nausea, vomiting, and other gastrointestinal disorders (1–4%) and metabolic

problems (e.g., obesity, hyperglycemia, and type 2 diabetes) (Rice *et al.*, 2017).

A powerful synthetic glucocorticoid drug used for a variety of inflammatory and immunological conditions is dexamethasone. Just like other glucocorticoids, dexamethasone side effects are linked to high doses and prolonged use (Aljebab *et al.*, 2017). Medicinal plants are gaining popularity in both supplementary and conventional treatment trends for patients. Several medicinal plants, including Fabaceae, Oleaceae,

Hippocastanaceae, Ranunculaceae, and Menispermaceae, may have pharmacological properties that improve the effectiveness of traditional therapies when implemented as supplemental medications (Süntar, 2020).

Bajakah tampala (*Spatholobus littoralis* Hassk.) is an endemic plant on the island of Kalimantan, Indonesia whose efficacy is now being investigated for ethnomedicine-based therapy (Liu *et al.*, 2022). According to previous studies, *S. littoralis* Hassk has potent antioxidant properties (IC 8.25 lg/mL) (Iskandar and Warsidah, 2020). Additionally, this herb demonstrated anti-breast cancer efficacy (Iskandar *et al.*, 2022). Furthermore, the phytochemical composition of *S. littoralis* Hassk has been revealed to contain flavonoids, saponins, steroids, terpenoids, tannins, and phenolic compounds. Similar uses for the flavonoids found in *S. littoralis* Hassk include photoprotective, anti-inflammatory, and antioxidant products as they are also included in anti-aging treatments (Sianipar *et al.*, 2023). Moreover, it prevents the enzymes tyrosinase, elastase, collagenase, and hyaluronidase stimulation (Sianipar *et al.*, 2022).

The abundance of bioactive compounds, immunomodulatory effects, anti-inflammatory activity, safety profile, traditional use, and scientific evidence supporting their efficacy as renal protection were some of the key factors that led to the selection of the plant extracts. Thus, this study aimed to investigate the effects of *S. littoralis* Hassk extracts on IL-1 and IL-6 cytokine expression, renal histopathology, and hematological profile parameters in albino rats suffering dexamethasone-induced renal toxicity.

MATERIALS AND METHODS

Ethical approval: The current study was authorized by The Animal Care and Ethical Use Committee, Faculty of Veterinary Medicine, Universitas Airlangga with reference No.1.KEH.038.03.2023. This ethical approval was considered to avoid animal abuse during the study.

Preparation of *S. littoralis* Hassk extract: *S. littoralis* Hassk was collected, washed, and allowed to dry under direct sunlight exposure for two days. They were then blended and sieved through a strainer with a 80-mesh diameter. After that, 2000 g, 3000 g, and 4000 g of the powder product were kept in containers that were securely closed. After that, it was submerged in a 96% ethanol solution under reflux circumstances for 24 hours at 27°C to continue achieving these properties. The filtrate of the ethanol extract was concentrated using a rotary evaporator (IKA RV-3[®], Germany) until viscous semi-solid masses were the result. The semi-solid mass extract was dissolved in 0.5% CMC Na until homogeneous and then implemented throughout the study.

Phytochemical characterization: A total of 5 mL of semi-solid mass was also evaluated for phytochemical characteristics (Table 1). The flavonoid test involved thoroughly mixing a combination of 2 mL amyl alcohol, magnesium powder, and semi-solid mass, then letting it settle to separate the hydrochloric alcohol. The yellow amyl alcohol layer indicated a positive outcome.

Table 1: Phytochemical characterization of *S. littoralis* Hassk extract

Phytocomponents	Result
Flavonoids*	+
▪ in extract form	5.95 ± 0.33 (mg/g QE)
▪ in powder form	0.20 ± 0.01 (% w/w)
Saponins	+
Tannins	+
Polyphenol	+
Alkaloids	+
Quinone	+
Steroids	-
Terpenoids	+

(+) indicated the content of the substance being analyzed; (-) did not indicate the content of the substance being analyzed; (*) quantified by spectrophotometric methods (Matić *et al.*, 2017).

In the tannin test, a semi-solid mass was heated in a water bath to acquire a pink deposit after being combined with a steady reagent. Following filtration and NaCl saturation, gelatin was added to the by-product. The white deposit indicated a positive outcome. For the alkaloid test, 50 mL of water and a semi-solid mass were heated for five minutes before being filtered. If a white deposit formed in the Mayer test and an orange deposit formed in the Dragendorff test, the test indicated a positive outcome. To test for saponins, a semi-solid mass was introduced to the reaction tube, shaken for ten seconds, and then allowed to stand for ten minutes. Bubbles or foam accumulation indicated a positive outcome. A semi-solid bulk and three drops of FeCl reagent were combined for the polyphenol test. The blue-green color reaction indicated a positive outcome. For the quinone test, 1N NaOH was combined with a semi-solid mass. The red reaction indicated a positive outcome. To test the steroids and terpenoids, the residue was mixed with one drop of H₂SO₄ and two drops of anhydrous acetic acid in a semi-solid mass. The terpenoids indicated a brown tint and the steroids indicated a green color.

Animals: A total of 25 male, healthy, and deformity-free albino rats were included in this study. They were reared in a room with an ambient temperature of 27 ± 2°C and a 12-hour light-dark cycle. The animals were fed a normal diet and water *ad libitum*. Before being administered a dose, rats were allowed a week to get acclimated to the lab environment. After the acclimation period, all albino rats were randomized and divided into five treatment groups with five replications i.e. (C-) placebo, (C+) animals were injected subcutaneously with 0.1 mg/kg BW of dexamethasone, (T1) animals were injected subcutaneously with 0.1 mg/kg BW of dexamethasone and administered orally with 200 mg/kg BW of *S. littoralis* Hassk extract, (T2) animals were injected subcutaneously with 0.1 mg/kg BW of dexamethasone and administered orally with 300 mg/kg BW of *S. littoralis* Hassk extract, (T3) animals were injected subcutaneously with 0.1 mg/kg BW of dexamethasone and administered orally with 400 mg/kg BW of *S. littoralis* Hassk extract, respectively (Liu *et al.*, 2022). An hour after the subcutaneous injection of 0.1 mg/kg BW of dexamethasone, an oral dose of *S. littoralis* Hassk extract was administered. All experimental animals were administered therapy three times a week, on Mondays, Wednesdays, and Fridays at 8 am, for four weeks (Hasona *et al.*, 2017).

Table 2: Immunohistochemistry (IHC) scoring method for IL-1 and IL-6

Score	Interpretation
0	If < 25% of the number of cells in the observation indicated a brownish color intensity
1	If 25–50% of the number of cells in the observation indicated a brownish color intensity
2	If 50–75% of the number of cells in the observation indicated a brownish color intensity
3	If > 75% of the number of cells in the observation indicated a brownish color intensity

Table 3: Haematoxylin and eosin (H&E) scoring method for renal disorder

Score	Interpretation
Glomerulus	
0	Absence of glomerular lesions
1	Presence of thickening of Bowman's gap
2	Presence of glomerular retraction
3	Presence of glomerular fibrosis
Proximal and distal tubules	
0	Absence of proximal and distal tubular lesions
1	Occurrence of 25% degeneration of cuboid cells and brush border
2	Occurrence of degeneration of cuboid cells and thickening of the basement membrane
3	Occurrence of 60% necrosis of cuboid cells
4	Presence of amorphous tubules

Evaluation of IL-1, IL-6, renal histopathology, and hematology profile: Rats were fasted for 12 hours after the 30-day experiment was over, and they were euthanized by cervical decapitation. Blood samples were collected and then evaluated for hematology profile using a hematology analyzer (Hitachi 902[®], Roche Diagnostics, USA). Rats from each group had their kidneys surgically removed during abdominal surgery, washed, and preserved in 15% formalin for immunohistochemistry and H&E staining. The expression of IL-1 and IL-6 was assessed based on the intensity of the brown color in the cells (Table 2) (Arjumand *et al.*, 2019). Meanwhile, renal histopathological evaluation was based on the glomerulus, and the proximal and distal tubules (Table 3) (Obrișcă *et al.*, 2018). Observations were performed in five fields of view using a trinocular microscope (Nikon Eclipse E200[®], Japan).

Statistical analysis: The format for all the data was mean \pm standard deviation. The Kolmogorov-Smirnov normality test was implemented to examine the distribution of the data. Analysis of Variance (one-way ANOVA) was used to investigate continuous variables with parametric distributions. If the findings were significant, a post hoc Duncan's comparison test was carried out. The Kruskal-Wallis and post hoc Mann-Whitney tests were used for multiple comparisons on data having a non-parametric distribution. The statistical program SPSS (IBM, USA) was used for each analysis. P values < 0.05 were considered as significant.

RESULTS

Expression of IL-1 and IL-6: The expression of IL-1 and IL-6 in the T2 and T3 groups was revealed to be significantly decreased compared with the C+ group. Meanwhile, the T3 group showed similar expression to the C- group (Table 4). The expression of IL-1 and IL-6 was indicated by the intensity of the brown color in podocyte cells in the glomerulus, cuboid cells in the proximal and distal tubules (Fig. 1 and Fig. 2). It can be

Table 4: Expression of IL-1 and IL-6 in all treatment groups

Treatment groups	IL-1	IL-6
C-	0.80 \pm 0.37 ^a	1.00 \pm 0.24 ^a
C+	2.36 \pm 0.43 ^c	2.80 \pm 0.51 ^c
T1	2.04 \pm 0.48 ^{bc}	2.32 \pm 0.23 ^{bc}
T2	1.76 \pm 0.17 ^b	2.04 \pm 0.26 ^b
T3	1.20 \pm 0.47 ^a	1.48 \pm 0.52 ^a

Values were expressed in the mean \pm SD. Different superscripts on the same column indicated a significant difference ($p < 0.05$).

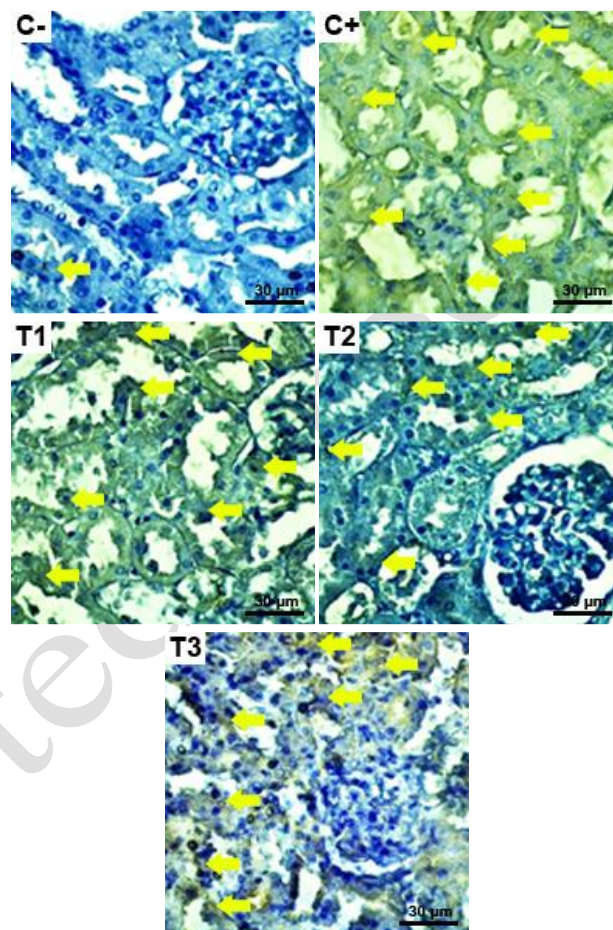


Fig. 1: Expression of IL-1 (\rightarrow) was indicated by the brownish intensity observed in the renal cortex in all treatment groups. (Immunohistochemical staining, 400 \times).

assumed that oral treatment of 300 mg/kg BW *S. littoralis* Hassk extract can, at least, alleviate the cytokine expression of IL-1 and IL-6. Meanwhile, *S. littoralis* Hassk extract can improve to nearly normal with an oral dose of 400 mg/kg BW.

Renal histopathological findings: Based on histopathological findings, the T2 and T3 groups reported significant improvements compared to the C+ group for the variables of glomerular, proximal and distal tubule scores and the amount of inflammatory cell infiltration, respectively (Table 5). These findings were also highlighted by observed glomerular retraction, thickening of Bowman's space, cuboidal cell necrosis in the proximal and distal tubules in groups C+ and T1. In addition, inflammatory cell infiltration in the vascular pole and medullary rays was also observed in the C+ and T1 groups (Fig. 3).

Evaluation of hematological profile: Overall, all *S. littoralis* Hassk extract treatment groups showed improvements in leukocyte, erythrocyte, platelet, BUN,

Table 5: Renal histopathological evaluation observed cell degeneration in the glomerulus, proximal and distal tubules in all treatment groups

Treatment groups	Glomerulus	Proximal tubules	Distal tubules	Inflammatory cell infiltration
C-	0.82 ± 0.17 ^a	1.12 ± 0.42 ^a	1.28 ± 0.23 ^a	41.76 ± 7.18 ^a
C+	2.16 ± 0.73 ^c	2.78 ± 0.15 ^c	3.00 ± 0.24 ^c	77.96 ± 4.02 ^c
T1	1.92 ± 0.37 ^{bc}	2.43 ± 0.19 ^{bc}	2.80 ± 0.37 ^{bc}	69.84 ± 5.28 ^{bc}
T2	1.41 ± 0.28 ^{ab}	2.11 ± 0.28 ^b	2.44 ± 0.26 ^b	61.88 ± 4.96 ^b
T3	1.02 ± 0.31 ^a	1.39 ± 0.47 ^a	1.52 ± 0.41 ^a	49.36 ± 8.98 ^a

Values were expressed in the mean ± SD. Different superscripts on the same column indicated a significant difference ($p < 0.05$).

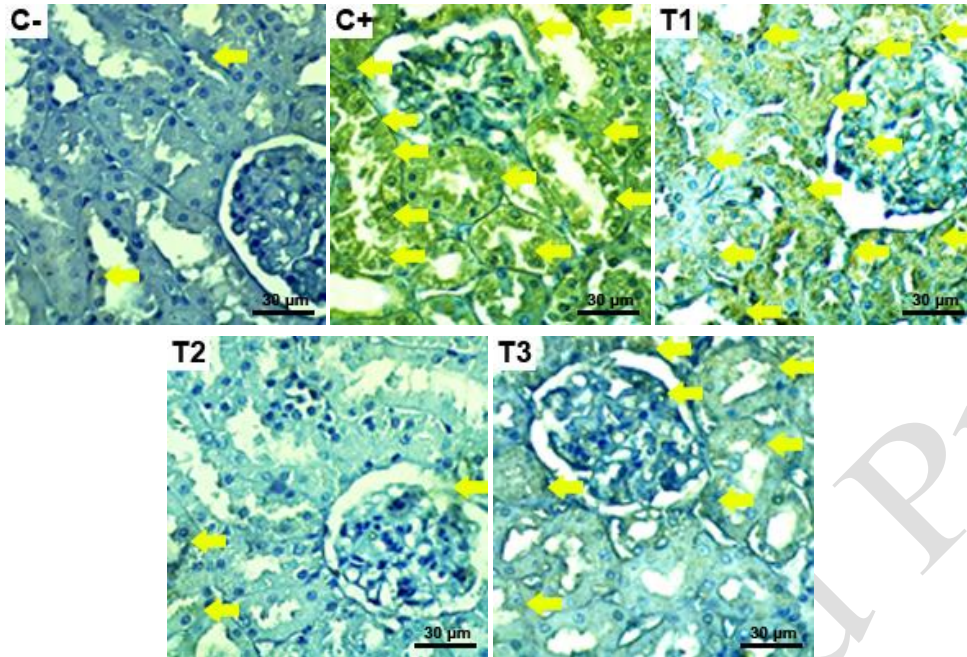


Fig. 2: Expression of IL-6 (→) was indicated by the brownish intensity observed in the renal cortex in all treatment groups. (Immunohistochemical staining, 400×).

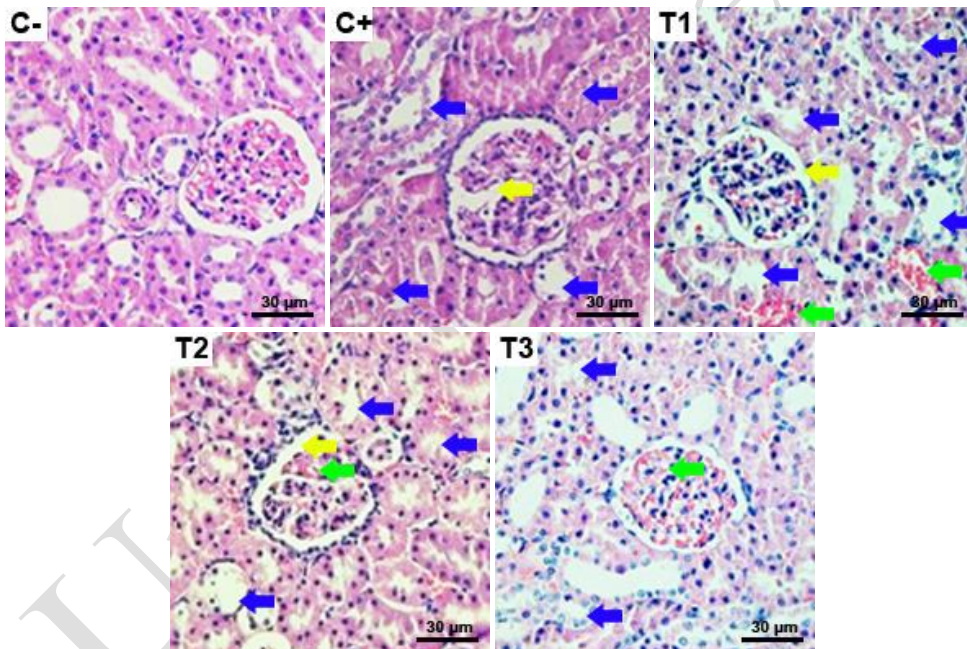


Fig. 3: Histopathological evaluation in all treatment groups revealed findings in the form of glomerular retraction (→), tubular necrosis (→), and inflammatory cell infiltration (→). (H&E staining, 400×).

uric acid, and creatinine parameters during hematological profile examination. However, the T3 group in this study was highlighted as being nearly normal in comparison to the C- group. This hematological profile also indicated that the *S. littoralis* Hassk extract had no effect on total hematocrit and hemoglobin levels (Table 6).

DISCUSSION

A synthetic glucocorticoid called dexamethasone is prescribed to treat autoimmune and inflammatory

disorders (Cain and Cidlowski, 2017). However, lethal infections rise from 0% to 1.37% after extended exposure to dexamethasone (Te Poele *et al.*, 2007). The current investigation shows that *S. littoralis* Hassk extract protects experimental albino rats against dexamethasone-induced kidney damage and has a dose-response effect. Certain flavonoids have been identified as having cosmetic qualities in *S. littoralis* Hassk, including catechin, daidzein, formononetin, glycitein, luteolin, apigenin, hesperetin, naringenin, negletein, and kaempferide (Arsul *et al.*, 2022).

Table 6: Hematological profile in all treatment groups

Parameters	C-	C+	T1	T2	T3
Leukocytes ($10^3/\mu\text{L}$)	13.30 \pm 4.22 ^b	11.26 \pm 2.44 ^b	9.29 \pm 3.10 ^{ab}	7.40 \pm 4.27 ^{ab}	4.01 \pm 2.96 ^a
Erythrocytes ($10^6/\mu\text{L}$)	8.34 \pm 0.68 ^b	6.22 \pm 1.18 ^a	9.17 \pm 1.04 ^b	8.26 \pm 1.08 ^b	7.59 \pm 0.62 ^{ab}
Hemoglobin (g/dL)	146.6 \pm 20.59 ^a	129.4 \pm 19.20 ^a	166.4 \pm 20.59 ^a	206.4 \pm 84.07 ^a	131.8 \pm 45.41 ^a
Hematocrit (%)	42.94 \pm 2.50 ^a	39.85 \pm 7.71 ^a	48.38 \pm 5.74 ^a	44.42 \pm 4.58 ^a	41.80 \pm 2.88 ^a
Platelets ($10^3/\mu\text{L}$)	391.8 \pm 54.57 ^c	340.6 \pm 106.64 ^c	209.2 \pm 74.98 ^a	212.2 \pm 111.80 ^a	112.4 \pm 14.87 ^b
BUN (mg/dL)	22.18 \pm 0.73 ^a	35.61 \pm 1.18 ^c	32.33 \pm 0.56 ^{bc}	27.62 \pm 0.48 ^b	24.58 \pm 0.51 ^{ab}
Uric acid (mg/dL)	0.51 \pm 0.061 ^a	1.74 \pm 0.051 ^c	1.23 \pm 0.093 ^{bc}	1.11 \pm 0.113 ^b	1.02 \pm 0.084 ^{ab}
Creatinine (mg/dL)	0.24 \pm 0.011 ^a	0.39 \pm 0.018 ^c	0.34 \pm 0.013 ^{bc}	0.33 \pm 0.007 ^{bc}	0.31 \pm 0.012 ^b

Values were expressed in the mean \pm SD. Different superscripts on the same row indicated a significant difference ($p < 0.05$)

The expression of IL-1 and IL-6 was reduced to assess the *S. littoralis* Hassk extract's ability to protect against oxidative stress. Furthermore, renal histology and the hematological profile were dramatically improved to levels close to normal by 300 mg/kg BW of *S. littoralis* Hassk extract in a dose-dependent manner. This is so due to the antioxidant and free radical scavenging properties of *S. littoralis* Hassk extract, which guard against oxidative stress and restore the depleted glutathione concentration. Our results are consistent with those of, who found that oral treatment of *S. littoralis* Hassk extract improved and balanced the antioxidant defense against squamous cell carcinoma of the tongue (Yasmin *et al.*, 2023).

According to this study, dexamethasone toxicity can alter the histological appearance of albino rats' kidneys as well as the expression of IL-1 and IL-6. All medications, including dexamethasone, pass via the kidneys' stages of excretion. Because of the increased blood flow to the kidneys, a variety of medications and chemicals from the systemic circulation are transferred to the kidneys in significant amounts, which leads to the buildup of toxic substances in the kidneys (Kwiatkowska *et al.*, 2021).

The degree of inflammation was indicated by the levels of IL-1 and IL-6. Renal resident cells, such as podocytes, mesangial cells, endothelial cells, and tubular epithelial cells, can produce IL-1 and IL-6. All of these cells will actively react to IL-6 via the trans-signaling route in the meantime, as will immune and inflammatory cells. Along with several immunological, metabolic, ischemia, and toxemic-mediated renal disorders, IL-6 has a role in the injury and repair of renal instinct cells (Su *et al.*, 2017). Exposure to hazardous amounts of 0.1 mg/kg BW of dexamethasone can increase reactive oxygen species (ROS), which can then cause oxidative stress reactions and high cytokine levels. An imbalance between ROS and endogenous antioxidants, that collaborate to prevent tissue damage, is known as oxidative stress (Engwa *et al.*, 2022). Cell damage will accelerate as a result of excessive oxidative responses. Tissue cells that have been exposed to harmful substances may become inflamed. The pro-inflammatory cytokines IL-6, IL-1, and TNF- α are released when nuclear factor-kappa B (NF-kB) is activated due to the activation of macrophages brought on by the inflammatory reaction (Liang *et al.*, 2018).

Variations in nephron histology can also be used to diagnose kidney injury. The glomerular bundle is retracted and the Bowman's capsule is thickened, as observed under a microscope. Retraction results from damage to podocyte cells brought on by exposure to lethal levels of dexamethasone. Renal cells in Bowman's capsule called podocyte cells are arranged in a row around the

glomerular bundles or capillaries. The glomerular capillary structure will microscopically dissolve as a result of this lesion causing podocyte cells to atrophy (Djudjaj and Boor, 2019).

Both the distal and proximal tubules lose their brush border structure and develop necrosis. Due to the fact that the renal tubules are the site of both the reabsorption and excretion of poisonous chemicals, they are the organ most frequently affected by exposure to toxic substances (Petejova *et al.*, 2019). Renal degeneration and necrosis of the cells might result from toxins that expose the kidneys repeatedly. Cells that require more energy constantly for metabolic processes are known as tubular epithelial cells. These cells will suffer damage if they run out of energy and oxygen. Necrosis can occur in tubular cells because of their extreme sensitivity to anoxia and hypoxia (Ow *et al.*, 2018). Another study revealed that dexamethasone's short-term effects temporarily reduce ischemia-induced fibrosis (Moonen *et al.*, 2018).

Hematological indicators represent preclinical alterations in the body's internal homeostasis and are crucial for evaluating the health and function of the kidneys (Schnaper, 2017). A blood physiology imbalance results in problems or imbalances in other organs. Blood has a number of purposes, including supplying oxygen to all bodily tissues, preserving the acid-base balance, promoting tissue metabolism, and preventing infections and hypersensitive reactions (Swerdloff *et al.*, 2017). Toxic exposure can cause an increase in leukocytes in response to infection or acute inflammation. A disease known as neutrophilia, which is characterized by a preponderance of neutrophils, can be brought on by corticosteroids like dexamethasone (Garcovich *et al.*, 2017). Reduced immunity may occur from large and prolonged dosages of dexamethasone. The immunosuppressive drug dexamethasone was introduced to group C+, which resulted in an increase in leukocyte counts. Antioxidants that preserve the integrity of cell membranes can be used in attempts to lessen the negative consequences of dexamethasone (Abd El-Hakam *et al.*, 2022).

The immunorestorative and immunostimulant properties of *S. littoralis* Hassk extract can lead to a reduction in leukocyte counts. An inflammatory and/or infectious stimulus causes leukocyte counts to rise. Concurrently, corticosteroid triggers may result in an increase in neutrophils. Supplying antioxidants that can preserve membrane integrity and cell protection can help alleviate the harmful effects of dexamethasone on the kidneys (Gao and Wu, 2023). In cases of renal toxicity brought on by dexamethasone, this study highlighted that *S. littoralis* Hassk extract functions as a radical scavenger.

Important markers to assess kidney function are blood urea nitrogen (BUN), uric acid, and creatinine levels. In earlier studies, elevated levels of uric acid, creatinine, and BUN have been utilized to signify renal failure (Hahn *et al.*, 2017; Hsieh *et al.*, 2017). BUN is a significant metabolic byproduct of protein synthesis and has been used to show glomerular damage. Increased synthesis of the arginase enzyme, which is involved in the manufacture of urea, and/or increased protein catabolism were associated with raised BUN levels (Xie *et al.*, 2018). The kidneys eliminate creatinine, an end metabolic byproduct of muscle catabolism, at a steady rate. The glomerular filtration mechanism is necessary for the excretion of creatinine. The increased level of creatinine indicates tubular and glomerular dysfunction. The primary metabolic byproduct of purine nucleotides is uric acid. One renal prognostic factor is an elevated amount of uric acid (Hsieh *et al.*, 2021). However, since uric acid scavenges reactive oxygen species, elevated serum uric acid quantity might represent the metabolic reaction to increased endogenous oxygen species generation (Gherghina *et al.*, 2022).

It has been previously documented that dexamethasone raised the levels of uric acid, creatinine, and BUN (Hasona *et al.*, 2017). In line with the previous findings, our study revealed elevated levels of uric acid, creatinine, and BUN, which could be caused by tubular and glomerular injury. The restoration of reduced levels of uric acid, creatinine and BUN could be linked to the decrease in lipid peroxidation caused by the *S. littoralis* Hassk extract. The enzymes xanthine oxidase (XOD) and adenosine deaminase (ADA) exhibit reduced activity in response to a decrease in lipid peroxidation. Uric acid production depends primarily on the XOD and ADA enzymes. Adenosine is deaminated by the ADA enzyme and becomes inosine. The XOD enzyme then catalyzes the conversion of inosine into xanthine and uric acid (Liu *et al.*, 2020). Hence, by lowering and affecting the activity of XOD and ADA enzymes, *S. littoralis* Hassk extract might alleviate BUN, uric acid, and creatinine. In order to fully investigate the effectiveness of *S. littoralis* Hassk, future studies using ELISA assays must evaluate inflammatory and autophagy markers of dexamethasone-induced oxidative stress in the liver and kidney tissues.

Conclusions: *S. littoralis* Hassk extract at a dose of 300 mg/kg BW could potentially alleviate renal toxicity induced by dexamethasone. Reduced expression of IL-1 and IL-6 in the renal cortex, as well as improved the glomerulus, proximal and distal tubules, and inflammatory cells, supported these findings. Leukocyte, erythrocyte, platelet, BUN, uric acid, and creatinine improvisation during hematological profile monitoring have also been documented.

Authors contribution: FF contributed to conceptualization, methodology, funding acquisition, and supervision. TAA, CFD, AY, AP, and STM contributed to investigation, prepared extraction, treated animals, and parameters evaluation. STM, FF, AP, and MTEP contributed to project administration, visualization, validation, data curation, writing-original draft, and editing. All authors have read and approved the final manuscript.

Acknowledgments: The authors acknowledge the Dean of the Faculty of Health, Medicine, and Life Sciences, Universitas Airlangga for providing fund support to carry out this study based on scheme Airlangga Research Fund Batch 2 grant number 1532/UN3.LPPM/PT.01.02/2023.

Competing Interests: The authors declare that they have no competing interests.

REFERENCES

- Abd El-Hakam FEZ, Abo Laban G, Badr El-Din S, *et al.*, 2022. Apitherapy combination improvement of blood pressure, cardiovascular protection, and antioxidant and anti-inflammatory responses in dexamethasone model hypertensive rats. *Sci Rep* 12:20765.
- Aljebab F, Choonara I and Conroy S, 2017. Systematic review of the toxicity of long-course oral corticosteroids in children. *PLoS one* 12:e0170259.
- Arjumand S, Shahzad M, Shabbir A, *et al.*, 2019. Thymoquinone attenuates rheumatoid arthritis by downregulating TLR2, TLR4, TNF- α , IL-1, and NF κ B expression levels. *Biomed Pharmacother* 111:958-963.
- Arsul MI, Syamsi N, Putri N, *et al.*, 2022. Total phenolic, flavonoid, and antioxidant capacity of bajakah (*Spatholobus littoralis* Hassk). *Curr Res Biosci Biotechnol* 4:242-245.
- Cain DW and Cidlowski JA, 2017. Immune regulation by glucocorticoids. *Nat Rev Immunol* 17:233-247.
- Djudjaj S and Boor P, 2019. Cellular and molecular mechanisms of kidney fibrosis. *Mol Aspects Med* 65:16-36.
- Engwa GA, Nweke FN and Nkeh-Chungag BN, 2022. Free radicals, oxidative stress-related diseases and antioxidant supplementation. *Altern Ther Health Med* 28:114.
- Gao X and Wu Y, 2023. Perioperative acute kidney injury: The renoprotective effect and mechanism of dexmedetomidine. *Biochem Biophys Res Comm* 149402.
- Garcovich S, De Simone C, Berti E, *et al.*, 2017. Drug management of neutrophilic dermatoses. *Expert Rev Clin Pharmacol* 10:1119-1128.
- Gherghina ME, Peride I, Tiglis M, *et al.*, 2022. Uric acid and oxidative stress—relationship with cardiovascular, metabolic and renal impairment. *Int J Mol Sci* 23:3188.
- Hahn K, Kanbay M, Lanaspas MA, *et al.*, 2017. Serum uric acid and acute kidney injury: a mini review. *J Adv Res* 8:529-536.
- Hasona NA, Alrashidi AA, Aldugiean TZ, *et al.*, 2017. *Vitis vinifera* extract ameliorate hepatic and renal dysfunction induced by dexamethasone in albino rats. *Toxics* 5:11.
- Hsieh YP, Chang CC, Yang Y, *et al.*, 2017. The role of uric acid in chronic kidney disease patients. *Nephrol* 22:441-448.
- Hsieh MW, Chen HY and Tsai CC, 2021. Screening and evaluation of purine-nucleoside-degrading lactic acid bacteria isolated from winemaking byproducts in vitro and their uric acid-lowering effects in vivo. *Ferment* 7:74.
- Iskandar D and Warsidah W, 2020. Qualitative phytochemical screening and antioxidant activity of ethanol root extract of *Spatholobus littoralis* Hassk. *J Food Med Plants* 1:13-15.
- Iskandar D, Widodo N, Warsito M, *et al.*, 2022. Phenolic content, antioxidant, cytotoxic of fractions of *Spatholobus littoralis* Hassk from Kalimantan, Indonesia. *J Hunan Univ Nat Sci* 49:14-23.
- Kwiatkowska E, Domański L, Dziezdziejko V, *et al.*, 2021. The mechanism of drug nephrotoxicity and the methods for preventing kidney damage. *Int J Mol Sci* 22:6109.
- Liang H, Yang X, Liu C, *et al.*, 2018. Effect of NF- κ B signaling pathway on the expression of MIF, TNF- α , IL-6 in the regulation of intervertebral disc degeneration. *J Musculoskelet Neuronal Interact* 18:551.
- Liu G, Chen X, Lu X, *et al.*, 2020. Sunflower head enzymatic hydrolysate relieves hyperuricemia by inhibiting crucial proteins (xanthine oxidase, adenosine deaminase, uric acid transporter1) and restoring gut microbiota in mice. *J Funct Foods* 72:104055.
- Liu Y, Xiang Q, Liang Q, *et al.*, 2022. Genus *Spatholobus*: a comprehensive review on ethnopharmacology, phytochemistry, pharmacology, and toxicology. *Food Function* 13:7448-7472.
- Matić P, Sabljčić M and Jakobek L, 2017. Validation of spectrophotometric methods for the determination of total

- polyphenol and total flavonoid content. *J AOAC Int* 100:1795-1803.
- Moonen L, Geryl H, D'Haese PC, *et al.*, 2018. Short-term dexamethasone treatment transiently, but not permanently, attenuates fibrosis after acute-to-chronic kidney injury. *BMC Nephrol* 19:1-12.
- Obrişcă B, Jurubiţă R, Andronesi A, *et al.*, 2018. Histological predictors of renal outcome in lupus nephritis: the importance of tubulointerstitial lesions and scoring of glomerular lesions. *Lupus* 27:1455-1463.
- Ow CP, Ngo JP, Ullah MM, *et al.*, 2018. Renal hypoxia in kidney disease: cause or consequence?. *Acta Physiol* 222:e12999.
- Petejova N, Martinek A, Zadrazil J, *et al.*, 2019. Acute toxic kidney injury. *Renal Failure* 41:576-594.
- Rice JB, White AG, Scarpati LM, *et al.*, 2017. Long-term systemic corticosteroid exposure: a systematic literature review. *Clin Ther* 39:2216-2229.
- Schnaper HW, 2017. The tubulointerstitial pathophysiology of progressive kidney disease. *Adv Chronic Kidney Dis* 24:107-116.
- Sianipar RNR, Suryanegara L, Fatiasari W, *et al.*, 2023. The role of selected flavonoids from bajakah tampala (*Spatholobus littoralis* Hassk.) stem on cosmetic properties: A review. *Saudi Pharm J* 31:382-400.
- Sianipar RNR, Sutriah K, Iswantini D, *et al.*, 2022. Inhibitory Capacity of Xanthine Oxidase in Antigout Therapy by Indonesian Medicinal Plants. *Pharmacogn J* 14:470-479.
- Su H, Lei CT and Zhang C, 2017. Interleukin-6 signaling pathway and its role in kidney disease: an update. *Front Immunol* 8:405.
- Süntar I, 2020. Importance of ethnopharmacological studies in drug discovery: role of medicinal plants. *Phytochem Rev* 19:1199-1209.
- Swerdloff RS, Dudley RE, Page ST, *et al.*, 2017. Dihydrotestosterone: biochemistry, physiology, and clinical implications of elevated blood levels. *Endocr Rev* 38:220-254.
- Te Poele EM, de Bont ES, Boezen HM, *et al.*, 2007. Dexamethasone in the maintenance phase of acute lymphoblastic leukaemia treatment: is the risk of lethal infections too high?. *Eur J Cancer* 43:2532-2536.
- Xie Y, Bowe B, Li T, *et al.*, 2018. Higher blood urea nitrogen is associated with increased risk of incident diabetes mellitus. *Kidney Int* 93:741-752.
- Yasmin T, Rizkiyani A and Akmalia MF, 2023. Ethanol Extract of Borneo's Bajakah Tampala Root (*Spatholobus littoralis* hassk) Suppresses the Cell Proliferation and Chemotactic Migration and Induces Apoptosis on A Human Oral Tongue Squamous Cell Carcinoma Cell. *J Int Dent Med Res* 16:607.