



RESEARCH ARTICLE

Ameliorative potential of kaempferide to counteract paraquat instigated nephrotoxicity in rats

Muhammad Umar Ijaz^{1,*}, Ayesha Siddiqa¹, Ali Akbar¹, Nazia Ehsan¹, Khalid A. Al-Ghanim² and Mian Nadeem Riaz³

¹Department of Zoology, Wildlife and Fisheries, University of Agriculture, Faisalabad 38040, Pakistan

²Department of Zoology, College of Science, King Saud University, P.O. Box 2455, Riyadh 11451, Riyadh, Saudi Arabia

³Texas A & M University, College Station, TX 2476, USA

*Corresponding author: umar.ijaz@uaf.edu.pk

ARTICLE HISTORY (24-259)

Received: May 11, 2024
Revised: August 2, 2024
Accepted: August 8, 2024
Published online: August 16, 2024

Key words:

Kaempferide
Paraquat
Toxicity
Kidney damage
Oxidative stress

ABSTRACT

Paraquat (PQT) is among the most toxic herbicides that possesses the potential to exert deleterious effects on animal and human health. Kaempferide (KMF) is a natural flavanol that manifests profound therapeutic potential. Rats (n=24) were separated into 4 groups i.e., Control, PQT 5 mgkg⁻¹, PQT 5 mgkg⁻¹ + KMF 20 mgkg⁻¹ and KMF 20 mgkg⁻¹ administered group. After 30 days of treatment, our results revealed that PQT exposure reduced the activities of antioxidant enzymes i.e., glutathione S-transferase (GST), glutathione (GSH), superoxide dismutase (SOD), glutathione reductase (GSR), catalase (CAT), glutathione peroxidase (GPx) and heme oxygenase-1 (HO-1) while increased the levels of malondialdehyde (MDA) and reactive oxygen species (ROS). Furthermore, PQT intoxication reduced the level of renal biomarkers i.e., creatinine clearance, and increased the level of creatinine, urea, neutrophil gelatinase-associated lipocalin (NGAL) and kidney injury molecule-1 (KIM-1). In addition to this, it increased the levels of nuclear factor-kappa B (NF-kB), tumor necrosis factor-alpha (TNF-a), interleukin-1beta (IL-1β) and interleukin-6 (IL-6) as well as increased the activity of cyclooxygenase-2 (COX-2). Furthermore, PQT exposure increased the levels of caspase-9, Bax and caspase-3 while it decreased the levels of Bcl-2. Additionally, histological analysis showed substantial renal tissue damage in PQT intoxicated rats. However, KMF treatment recovered the renal impairments. Therefore, it is proposed that KMF may be used as a nephroprotective agent against PQT-prompted renal toxicity.

To Cite This Article: Ijaz MU, Siddiqa A, Akbar A, Ehsan N, Al-Ghanim K.A, Riaz MN, 2024. Ameliorative potential of kaempferide to counteract paraquat instigated nephrotoxicity in rats. Pak Vet J. <http://dx.doi.org/10.29261/pakvetj/2024.228>

INTRODUCTION

Pesticide contamination is an emerging public health concern in developing as well as developed countries owing to its extremely high rates of mortality. Approximately 2 million cases of pesticide intoxication are being reported every year worldwide (Panis et al., 2022). Paraquat (PQT) is a nitrogenous herbicide that is widely used to eradicate the unwanted herbs in the agriculture sector (Sukumar et al., 2019). However, PQT contamination has severe toxic effects on animals. Moreover, numerous cases of human deaths have been reported due to PQT intoxication (Tsai, 2013). Furthermore, epidemiological evidence suggests that more than 50% of the deaths due to pesticide contamination are associated with PQT contamination (Freire and Koifman, 2012).

PQT possesses the potential to impair the normal physiological function of different organs including liver as well as kidneys (Chen et al., 2021). It is reported that the cytotoxic effects of PQT are associated with its ability to generate excessive free radicals which instigate the process of oxidation in the renal system (Ranjbar, 2014). Furthermore, PQT induced oxidative damage is closely linked with lipid peroxidation of cellular membranes and subcellular components in kidneys (See et al., 2022). Recent studies have revealed that PQT intoxication can induce severe kidney damage via increasing the level of urea and urinary proteins as well as prompting severe histological anomalies (Ijaz et al., 2024).

Plant-based natural compounds are reported as potential agents to mitigate oxidative damage in the body (Mirkov et al., 2020). Kaempferide is a natural flavanol that was initially isolated from *Hippophae rhamnoides* L.,

commonly known as sea buckthorn (Chen et al., 2013). It has been revealed that KMF exhibits antioxidant, neuroprotective, anti-inflammatory as well as cardioprotective properties (Mercader-Ros et al., 2013). However, studies regarding pharmacotherapeutic action of KMF against PQT induced nephrotoxic effects are limited. Therefore, the current study was designed to evaluate the pharmacotherapeutic potential of KMF against PQT prompted biochemical and histopathological impairments in rats.

MATERIALS AND METHODS

Chemicals: PQT (CAS Number: 75365-73-0; Purity: \geq 98%) and KMF (CAS Number: 491-54-3; Purity: \geq 97%) were procured from Sigma-Aldrich®, Germany.

Animals: 24 rats (albino rats) were used for the investigation conducted at the Animal Research Center, University of Agriculture, Faisalabad. These animals were housed in specially designed cages under standard controlled environmental conditions. The rats were given a standard nutritional ration and unrestricted access to water. Prior to initiating the experimental procedures, the rats were acclimatized for one week. All the procedures were performed in line with European Union's regulations for animal welfare and research practices (CEE Council 86/609), ensuring that the ethical standards for the care and handling of the animals were rigorously followed.

Experimental plan: 24 rats were distributed into four separate groups (6/group). The experimental groups included: Control, PQT at a dosage of 5 mg/kg, PQT at 5 mg/kg combined with KMF at 20 mg/kg, and KMF administered alone at 20 mg/kg. Upon completion of the experimental phase, the animals were made unconscious and euthanized via decapitation to enable subsequent investigative procedures. The targeted organs (kidneys) were meticulously excised, separated into 2 halves and rinsed. 1st kidney was kept in formaldehyde mixture (10%) for the evaluation of histological profile on the other hand, the 2nd kidney was homogenized and subjected to centrifugation (12,000 rpm) for fifteen minutes and the prepared supernatant was kept at -20°C for further analysis.

Estimation of renal function markers: The levels of urea, creatinine, creatinine clearance, KIM-1 and NGAL were quantified by using standard ELISA kits (Cloud-clone Corp. USA). The assay was performed according to the guideline of the manufacturer.

Biochemical analysis: SOD & CAT's activity was quantified following Aebi (1974) & Kakkar et al. (1984)'s approaches. Rotruck et al. (1973) and Jollow et al. (1974)'s methodology was applied to quantify GPx & GSH. Carlberg and Mannervik (1975) and Younis et al. (2018)'s technique was used to quantify GSR along with GST. Hayashi et al. (2007) & Ohkawa et al. (1979) quantification approach was undertaken to check the level of Ros & MDA.

Assessment of inflammatory biomarkers: The levels of TNF- α , NF- κ B, IL-6, IL-1 β and COX-2 activity were determined by using standard ELISA kits (R & D,

Minnesota, USA). The assessment was carried out according to the instructions of the manufacturer.

Assessment of apoptotic biomarkers level: The levels of Bcl-2, Bax, Caspase-9 and Caspase-3 were measured by using standard ELISA kits (Cloud-clone Corp. USA). The protocol was carried out in line with the instructions of the manufacturer.

Histological assessment: Renal tissues were preserved in formalin solution (10%) to maintain structural integrity. Then the targeted tissues were subjected to ethanolic dehydration, ensuring the removal of water. The dehydrated tissues were then infiltrated with paraffin wax to create paraffin-embedded blocks. These blocks were segmented into 4 μ m thick slices using a microtome, producing uniform tissue sections for microscopic examination. The sections were subjected to staining with hematoxylin and eosin. For detailed observation, the stained sections were examined under a light microscope. Images were captured by using a MoticTM 5.0-megapixel camera. The extent of renal tissue injuries was quantified by evaluating a range of histological alterations, providing insights into the pathological changes (de Menezes et al., 2019)

Statistical analysis: Data were expressed as Mean \pm SEM. To determine significant differences between groups, ANOVA was employed. Following the ANOVA, Tukey's post hoc test was conducted to perform pairwise comparisons among the groups. A threshold of $p < 0.05$ was set as significance level.

RESULTS

Impact of PQT and KMF on biochemical parameters: Exposure to PQT led to an increase in MDA & ROS, while concurrently causing a reduction in antioxidants levels as compared to the control group. This suggests that PQT induces oxidative stress and disrupts antioxidant defenses. However, the administration of both PQT and KMF together effectively regulated the levels of these biomarkers, indicating a potential therapeutic effect. Nonetheless, the levels of these biomarkers in the KMF-dosed group remained approximately close to the control, as illustrated in Table 1.

Impact of PQT and KMF on renal function markers: Exposure to PQT increased the levels of urea, KIM-1, creatinine, NGAL while concurrently causing a marked reduction in creatinine clearance as compared to the control. This suggests that PQT exposure can disturb the normal function of kidney. However, the administration of both PQT and KMF together significantly regulated the levels of these biomarkers, indicating a potential therapeutic effect. Nonetheless, the levels of the biomarkers in the KMF-dosed group were similar to the control, as shown in Table 2.

Impact of PQT and KMF on inflammatory parameters: Exposure to PQT increased the levels of inflammatory biomarkers as compared to the control. This suggests that PQT can halt the NF- κ B pathway and subsequently

dysregulates other inflammatory biomarker's levels. However, the administration of both PQT and KMF together effectively regulated the levels of these biomarkers, indicating a potential therapeutic effect. Nonetheless, the levels of the biomarkers in the KMF-dosed group remained approximately equal to the negative group, as shown in Table 3.

Impact of PQT and KMF on apoptosis parameters:

Exposure to PQT led to a significant increase in apoptotic biomarkers contrary to the control. However, the administration of both PQT and KMF together effectively regulated the levels of these biomarkers, indicating a potential therapeutic effect. Nonetheless, the levels of

these biomarkers in the KMF-dosed group remained approximately similar to the control, as shown in Table 4.

Impact of PQT and KMF on histopathology: PQT

exposure substantially disturbed the histological configuration of the kidney tissues as evidenced by the presence of tubular dilation, necrosis as well as contraction of glomerular mesangial cells in as compared to the control rats. Nevertheless, combined treatment of PQT and KMF considerably decreased the abovementioned alterations contrary to the control animals. Only KMF supplemented animals showed the renal histology almost similar to the control (Fig. 1).

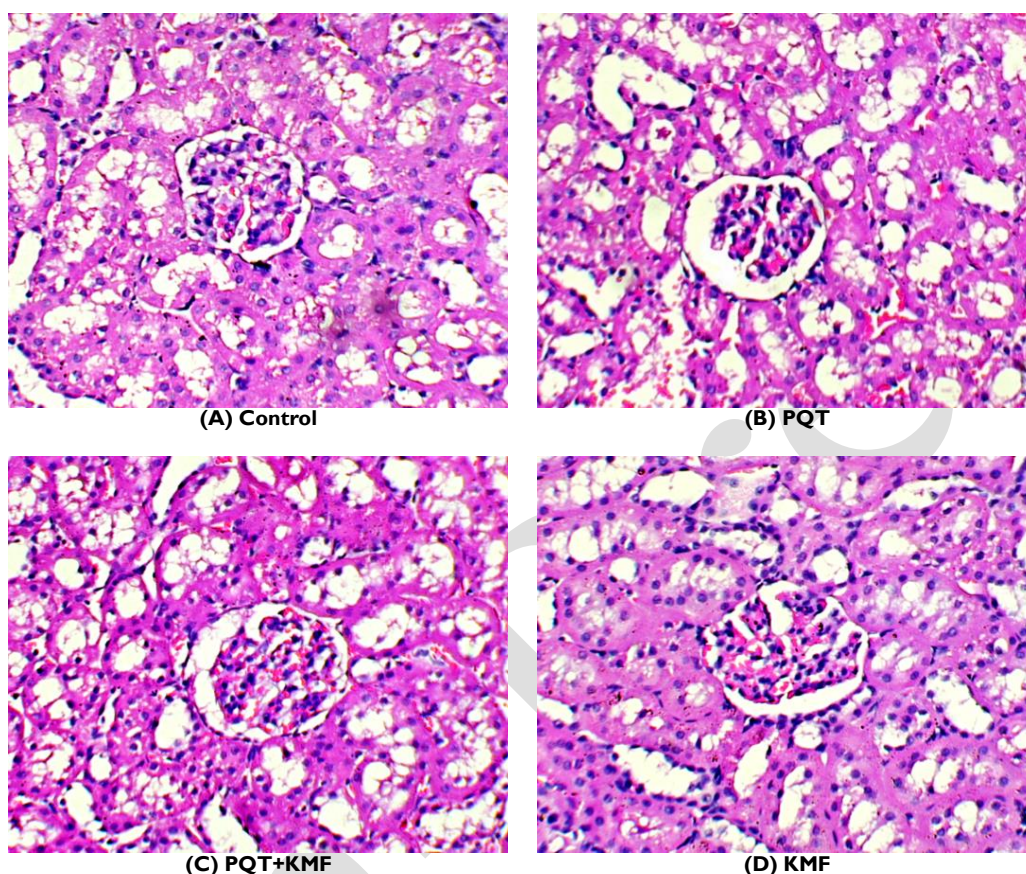


Fig. 1: Renal histology is normal in control group. B) PQT group exhibiting shrinkage of glomerulus, elevated bowman's space and tubular necrosis C) PQT + KMF group is illustrating restoration of renal parenchyma and glomerulus D) KMF group is demonstrating normal glomerulus and renal parenchyma.

Table 1: Effect of PQT and KMF on antioxidant profile and oxidative stress markers.

Parameters	Groups			
	Control	PQT	PQT + KMF	KMF
CAT (U/mg protein)	15.22±1.19 ^a	5.58±0.46 ^c	11.42±0.65 ^b	15.56±1.31 ^a
SOD (U/mg protein)	12.36±0.96 ^a	4.72±0.41 ^c	8.45±1.05 ^b	12.57±1.13 ^a
GSR (nM NADPH oxidized/min/mg tissue)	9.32±0.92 ^a	4.12±0.44 ^b	6.39±1.06 ^b	9.44±1.25 ^a
GPx (U/mg protein)	33.22±1.44 ^a	12.73±1.38 ^c	24.22±1.44 ^b	34.25±0.85 ^a
GSH (U/mg protein)	26.77±1.45 ^a	9.63±2.25 ^c	19.82±1.55 ^b	27.21±1.89 ^a
GST (U/mg protein)	38.03±3.08 ^a	15.98±2.07 ^c	27.44±2.17 ^b	38.44±2.99 ^a
MDA (nmol/g)	0.84±0.24 ^b	4.11±0.50 ^a	1.24±0.17 ^b	0.79±0.24 ^b
ROS (nmol/g)	1.51±0.26 ^b	7.81±0.58 ^a	2.44±0.38 ^b	1.45±0.28 ^b

Note: Values with different superscripts in a row are significantly different from each other.

Table 2: Effect of PQT and KMF on renal function markers

Parameters	Groups			
	Control	PQT	PQT + KMF	KMF
Urea (mg/dl)	14.14±1.28 ^c	61.77±2.56 ^a	24.98±2.46 ^b	14.29±0.83 ^c
Creatinine (mg/dl)	1.12±0.22 ^b	7.67±0.77 ^a	2.22±0.32 ^b	1.08±0.23 ^b
Creatinine Clearance (ml/min)	2.16±0.36 ^a	0.33±0.21 ^b	1.76±0.19 ^a	2.06±0.46 ^a
KIM-1 (mg/ml)	0.47±0.26 ^c	3.81±0.30 ^a	1.55±0.38 ^b	0.39±0.33 ^c
NGAL (ng/day)	0.78±0.40 ^b	5.35±0.60 ^a	1.37±0.15 ^b	0.69±0.49 ^b

Note: Values with different superscripts in a row are significantly different from each other.

Table 3: Effect of PQT and KMF on inflammatory biomarkers.

Parameters	Groups			
	Control	PQT	PQT + KMF	KMF
NF-κB (ng/g tissue)	19.22±1.33 ^c	82.99±2.81 ^a	29.17±2.65 ^b	19.03±1.17 ^c
TNFα (ng/g tissue)	9.49±1.00 ^c	46.44±2.25 ^a	17.05±1.44 ^b	9.11±1.47 ^c
IL-1β (ng/g tissue)	33.57±1.59 ^c	94.41± 3.06 ^a	45.52±2.72 ^b	33.28±1.81 ^c
IL-6 (ng/g tissue)	12.36±1.71 ^c	40.73±1.77 ^a	23.36± 2.27 ^b	12.10±1.58 ^c
COX-2 (ng/g tissue)	21.93±1.55 ^c	75.87±2.79 ^a	34.06±2.41 ^b	21.77±1.44 ^c

Note: Values with different superscripts in a row are significantly different from each other.

Table 4: Effect of PQT and KMF apoptotic biomarkers.

Parameters	Groups			
	Control	PQT	PQT + KMF	KMF
Bax (pg/mL)	1.72±0.29 ^c	8.56±1.12 ^a	3.84±0.40 ^b	1.68±0.31 ^c
Caspase-3 (pg/mL)	23.66±1.50 ^c	7.18±0.49 ^a	15.92±1.38 ^b	23.17±1.04 ^c
Caspase-9 (pg/mL)	1.23±0.23 ^b	18.04±2.15 ^a	3.743±0.72 ^b	1.183±0.27 ^b
Bcl-2 (ng/mL)	2.04±0.41 ^b	15.42±2.03 ^a	4.59±0.94 ^b	1.97±0.45 ^b

Note: Values with different superscripts in a row are significantly different from each other.

DISCUSSION

PQT is noxious herbicide which is recognized as potential health concern on the global scale (Tsai, 2013). Recent studies have elucidated that kidneys are among the primary targets of PQT intoxication. Furthermore, it has been documented that PQT exposure may prompt cytotoxic damage to the renal system via stimulating oxidative injury and dysregulating biochemical profile (Ijaz et al., 2024). Plant based remedial compounds including flavonoids possess the potential to counteract cytotoxic injuries due to their tremendous free radical mitigative properties (Mirkov et al., 2020). KMF is a phytochemical that is reported for its pharmacotherapeutic characteristics (Mercader-Ros et al., 2013). Therefore, this research aims to evaluate the potential therapeutic benefits of KMF in mitigating renal damage caused by PQT exposure.

The cellular antioxidant defense mechanism is recognized as indispensable for safeguarding the cellular membrane as well as subcellular components from various oxidative damages (El-Beltagi and Mohamed, 2013). PQT treatment impaired the cellular antioxidative defense by reducing renal antioxidants and stimulating LPO and particularly OS as evidenced by mounted concentration of MDA and ROS. The reduced activities of antioxidants trigger the onset of peroxide formation. This, in turn, results in the generation of renal OS, which impairs the normal function of the renal system (Daenen et al., 2019). However, KMF supplementation significantly ameliorated the nephrotoxic damage triggered by PQT administration which may be due to its free radicals salvaging potential. Our results are reinforced by the research conducted by Zhou et al. (2015), who elucidated that KMF possesses the potential to counteract myocardial oxidative injuries by modulating the concentration of cellular antioxidative enzymes.

PQT exposure prompted dysregulations in the targeted renal biomarkers. OS-induced increased the levels of nitrogenous end products i.e., creatinine along with urea possess the capability to alter the structural configuration of the glomerulus and impair filtration rate. Our findings are in line with the investigation of (Ijaz et al., 2024) who revealed that PQT can impair the levels of aforementioned renal biomarkers due to generation of excessive ROS. Therefore, OS is widely acknowledged as the primary factor contributing to the disruption of physiological function of the kidneys (Abdel-Reheim et al., 2024).

Additionally, elevated concentrations of KIM-1 and NGAL have been found to correlate positively with vascular damage and dysfunction in the proximal tubules, as reported by Wajda et al. (2020). Nonetheless, supplementation with KMF has been shown to effectively normalize these elevated biomarkers.

In the current study administration of PQT triggered acute inflammation (AIFN) response in the renal system as evidenced by augmented level of inflammatory markers. NF-κB functions as a central regulator that markedly enhances the levels of pro-inflammatory cytokines. This elevation initiates AIFN and causes damage associated with ROS throughout the body. By increasing inflammatory response, NF-κB plays a pivotal role in the development of various pathological conditions related to oxidative stress and cellular damage. (Ahmed et al., 2017). Furthermore, NF-κB has also been reported to mediate COX-2 which in turn initiates inflammatory reactions, leading to impairments in the renal tissues (Khan et al., 2022). However, KMF supplementation recovered the impaired level of aforesaid renal inflammatory parameters. KMF's ability to restore dysregulated inflammatory parameters may be due to inhibition of the NF-κB pathway, thereby reducing the expression of pro-inflammatory cytokines, which subsequently mitigated AIFN and ROS-associated damage in renal tissues.

PQT treatment impaired the apoptotic biomarker's levels. Programmed cell death is among the major factors that considerably contribute to the impairments in the renal tissues (Padanilam, 2003). Bcl-2 and Bax are integral components of the Bcl-2 protein family which possess the capability to significantly modulate the cellular apoptotic response. Apoptosis in renal cells occurs due to imbalance in pro-apoptotic and anti-apoptotic factors, as outlined by Ola et al. (2011). Rise in Bax levels, coupled with a decrease in Bcl-2 levels, play a crucial role in triggering the activation of caspases. This cascade of events ultimately leads to initiation of cell death in renal tissues (Havasi and Borkan, 2011). However, KMF supplementation restored the aforesaid biomarkers levels in the rat kidneys that may be due to its anti-apoptotic properties. KMF's anti-apoptotic properties counteract PQT-induced renal cell death by upregulating Bcl-2, which inhibits the apoptotic pathway, and downregulating Bax, which prevents mitochondrial membrane permeabilization. This balance prevents the activation of caspases, thus protecting renal cells from apoptotic damage.

The histological architecture of renal tissues is indispensable as it facilitates efficient filtration, reabsorption as well as secretion processes that are essential for regulating homeostasis and the normal physiological functions of the body (Rao et al., 2019). In the current investigation PQT exposure substantially disturbed the histological architecture of the renal tissues as evidenced by presence of tubular dilation, necrosis as well as contraction of glomerular mesangial cells. The aforementioned variations in the renal architectural arrangements resulted in dysregulation of blood filtration as well as electrolyte imbalance in the body (Edwards and Kurtcuoglu, 2022). However, KMF supplementation significantly recovered the histological profile in the kidney tissues owing to its nephroprotective properties.

Conclusions: It is concluded that PQT exposure induced oxidative damage, disturbed the activities of antioxidants and escalated the process of LPO in kidney tissues. Furthermore, PQT treatment showed a substantial dysregulation in targeted renal biomarkers. Besides, PQT administration resulted in disturbed levels of inflammatory and apoptotic markers along with considerable alterations in renal histology. However, KMF supplementation remarkably ameliorated all renal disturbances induced by PQT that may be due to its antioxidant, antiapoptotic, anti-inflammatory and nephroprotective properties.

Author's contribution: MUI, AS and AA prepared research design and executed the experiment. AS and NE carried out the experiment. KAG and MNR performed statistical analysis. MUI and AA wrote and proofread the final version of manuscript. All the authors read and approved the final version of the manuscript.

Acknowledgements: The authors express their sincere appreciation to the Researchers Supporting Project Number (RSP2024R48), King Saud University, Riyadh, Saudi Arabia.

REFERENCES

- Abdel-Reheim MA, Ali ME, Gaafar AG, et al., 2024. Quillaja saponin mitigates methotrexate-provoked renal injury; insight into Nrf-2/Keap-1 pathway modulation with suppression of oxidative stress and inflammation. *J Pharm Health Care sci* 10:1-15.
- Aebi H, 1984. Catalase estimation. *Methods Enzymol* 2:673-84.
- Ahmed SM, Luo L, Namani A, et al., 2017. Nrf2 signaling pathway: Pivotal roles in inflammation. *Biochim Biophys Acta Molec Basis of Dis* 1863:585-597.
- Carlberg IN and Mannervik BE, 1975. Purification and characterization of the flavoenzyme glutathione reductase from rat liver. *J Biol Chem* 250:5475-5480.
- Chen C, Xu XM, Chen Y, et al., 2013. Identification, quantification and antioxidant activity of acylated flavonol glycosides from sea buckthorn. *Food Chem* 141:1573-1579.
- Chen J, Su Y, Lin F, et al., 2021. Effect of paraquat on cytotoxicity involved in oxidative stress and inflammatory reaction: A review of mechanisms and ecological implications. *Ecotoxicol Environ Saf* 224:112711.
- Daenen K, Andries A, Mekahli D, et al., 2019. Oxidative stress in chronic kidney disease. *Pediatr Nephrol* 34:975-991.
- de Menezes MN, Salles EM, Vieira F, et al., 2019. IL-1 α promotes liver inflammation and necrosis during blood-stage *Plasmodium chabaudi* malaria. *Sci Rep* 9:7575.
- Edwards A and Kurtcuoglu V, 2022. Renal blood flow and oxygenation. *Pflügers Archiv-European J Physiol* 474:759-770.
- El-Beltagi HS and Mohamed HI, 2013. Reactive oxygen species, lipid peroxidation and antioxidative defense mechanism. *Not Bot Horti Agrobotanici Cluj-Napoca* 41:44-57.
- Freire C and Koifman S, 2012. Pesticide exposure and Parkinson's disease: epidemiological evidence of association. *Neurotoxicology* 33:947-971.
- Havasi A and Borkan SC, 2011. Apoptosis and acute kidney injury. *Kidney Int* 80:29-40.
- Hayashi I, Morishita Y, Imai K, et al., 2007. High-throughput spectrophotometric assay of reactive oxygen species in serum. *Mutat Res Genet Toxicol Environ* 631:55-61.
- Ijaz MU, Aziz S, Hamza A, et al., 2023. Curative effects of kaempferide on cadmium-instigated hepatotoxicity in male albino rats. *J King Saud Univ Sci* 35:102885.
- Ijaz MU, Manzoor A, Hamza A, et al., 2024. Ameliorative potential of sinensetin against paraquat induced renal damage by regulating oxidative, inflammatory, apoptotic and histopathological profile in male albino rats. *Eur J Inflamm* 22:1721727X241233122
- Jollow DJ, Mitchell JR, Zampaglione NA, et al., 1974. Bromobenzene-induced liver necrosis. Protective role of glutathione and evidence for 3, 4-bromobenzene oxide as the hepatotoxic metabolite. *Pharmacol* 11:151-169.
- Kakkar P, Das B, Viswanathan PN, et al., 1984. A modified spectrophotometric assay of superoxide. *Indian J Biochem Biophys* 21:130-2.
- Khan H, Sharma K, Kumar A, et al., 2022. Therapeutic implications of cyclooxygenase (COX) inhibitors in ischemic injury. *Inflamm Res* 71:277-292.
- Mercader-Ros MT, Lucas-Abellán C, Fortea MI, et al., 2013. Biological activities of kaempferol: Effect of cyclodextrins complexation on the properties of kaempferol. *Kaempferol: Chemistry, natural occurrences and health benefits. J Nat Prod* 1-31.
- Mirkov I, Stojković D, Aleksandrov AP, et al., 2020. Plant extracts and isolated compounds reduce parameters of oxidative stress induced by heavy metals: an up-to-date review on animal studies. *Curr Pharm Des* 26:1799-1815.
- Ohkawa H, Ohishi N and Yagi K, 1979. Assay for lipid peroxidation in animal tissues by thiobarbituric acid reaction. *Anal Biochem* 95:351-358.
- Ola MS, Nawaz M and Ahsan H, 2011. Role of Bcl-2 family proteins and caspases in the regulation of apoptosis. *Mol Cell Biochem* 351:41-58.
- Padanilam BJ, 2003. Cell death induced by acute renal injury: a perspective on the contributions of apoptosis and necrosis. *Am J Physiol Renal Physiol* 284:F608-F627.
- Panis C, Kawassaki AC, Crestani AP, et al., 2022. Evidence on human exposure to pesticides and the occurrence of health hazards in the Brazilian population: a systematic review. *Front Public Health* 9:787438.
- Ranjbar A, 2014. Evidence of oxidative damage in paraquat toxicity. *Zahedan J Res Med Sci* 16:1-8.
- Rao R, Bhalla V and Pastor-Soler NM, 2019, July. Intercalated cells of the kidney collecting duct in kidney physiology. In *Seminars in nephrology* 39:353-367.
- Rotruck JT, Pope AL and Ganther HE, 1973. Selenium: biochemical role as a component of glutathione peroxidase. *Sci* 179:588-590.
- See WZ, Naidu R and Tang KS, 2022. Cellular and molecular events leading to paraquat-induced apoptosis: mechanistic insights into Parkinson's disease pathophysiology. *Mol Neurobiol* 59:3353-3369.
- Sukumar CA, Shanbhag V and Shastry AB, 2019. Paraquat: the poison potion. *Indian J Crit Care Med: peer-reviewed, official publication of Indian Society of Critical Care Medicine.* 4:263
- Tsai WT, 2013. A review on environmental exposure and health risks of herbicide paraquat. *Toxicol Environ Chem* 95:197-206.
- Wajda J, Dumnicka P, Kolber W, et al., 2020. The marker of tubular injury, kidney injury molecule-1 (KIM-1), in acute kidney injury complicating acute pancreatitis: a preliminary study. *J Clin Med* 9:1463.
- Younis T, Rasul A, Jabeen F, et al., 2018. Ameliorating role of methanolic leaves extract of *Fraxinus xanthoxyloides* against CCl₄-challenged nephrotoxicity in rats. *Pak J Pharm Sci* 31:1475-1484.
- Zhou, M., Ren, H., Han, J., et al., 2015. Protective effects of kaempferol against myocardial ischemia/reperfusion injury in isolated rat heart via antioxidant activity and inhibition of glycogen synthase kinase-3. *Oxid Med Cell Longev* 2015.