



RESEARCH ARTICLE

Prevalence and Pathology of Marek's Disease in Layers and Layer breeders from Faisalabad Division Punjab

Muhammad Waseem Tahir¹, Muhammad Kashif Saleemi^{1*}, Muhammad Tariq Javed¹ and Muhammad Saqib²

¹Department of Pathology, University of Agriculture Faisalabad, Pakistan

²Department of Clinical Medicine and Surgery, University of Agriculture Faisalabad, Pakistan

*Corresponding author: drkashif313@gmail.com

ARTICLE HISTORY (24-831)

Received: December 20, 2024
Revised: January 15, 2025
Accepted: January 18, 2025
Published online: January 19, 2025

Key words:

Histopathology
Liver
Lymphomas
Nondescript birds
Prevalence
Sciatic nerve

ABSTRACT

The poultry industry is decreasing the gap between demand & supply of meat and eggs in Pakistan. There are many obstacles which interfere with growth and development of poultry sector, especially neoplastic diseases, which leads to heavy economic losses in poultry industry. Marek's disease (MD) falls under the category of major viral neoplastic diseases of poultry with estimated annual losses of about 1-2 billion US \$. Current study was designed to investigate the molecular prevalence and pathology of MD in layers and layer breeders from Faisalabad division. A total of 951 samples were collected from different poultry farms of Faisalabad through simple random sampling technique. PCR was performed by targeting *meq* gene with product size of 314bp and 180 (18.93%) samples were found positive for MD while 20.41, 12.50 and 15.62% prevalence were noted in district Faisalabad, Toba Tek Singh and Jhang respectively. Gross lesions of Marek's disease were diffused and nodular lymphomas found in visceral organs and muscles with discolored, dull and swollen sciatic nerve. Positive samples showed severe T-lymphocytic infiltration in hepatic, splenic, renal and nerve parenchyma. It was concluded that MDV, serotype-1 is frequently present in Faisalabad division and proper vaccination schedule with good quality vaccines should be adopted both in commercial and backyard poultry.

To Cite This Article: Tahir MW, Saleemi MK, Javed MT and Saqib M, 2024. Prevalence and Pathology of Marek's Disease in Layers and Layer breeders from Faisalabad Division Punjab. Pak Vet J. <http://dx.doi.org/10.29261/pakvetj/2024.309>

INTRODUCTION

Pakistan is the 11th largest poultry producer in the world with an overall production of 2362 metric ton meat annually (Anonymous, 2024). Unlike human medicine, neoplastic diseases of poultry are of infectious origin. Marek's disease, avian leukosis and reticuloendotheliosis are three important viral neoplastic diseases affecting poultry (Nair *et al.*, 2020).

Marek's disease (MD) is present around the globe, where poultry is reared. This is caused by Gallid alphaherpesvirus 2 (GaHV-2) (Mescolini *et al.*, 2020). This virus was first isolated in 1907 by Joseph Marek and was found responsible for the infiltration of mononuclear cells into the sciatic nerve (Swayne *et al.*, 2020). Mortality rate commonly accounts 10-30% but it may go high depending upon certain factors (Biggs and Nair, 2012). Marek's disease virus (MDV) belongs to the family herpesviridae, subfamily alpha herpesviridae. The MDV is classified into 3 serotypes named as serotype 1, serotype 2 and serotype 3. Among these, serotype 1 includes the virulent strains of

MDV which infect the T-lymphocytes. Serotype 1 is further categorized into different pathotypes named as mild (mMDV), virulent (vMDV), very virulent (vvMDV) and very virulent plus (vv+MDV) (Oluwayinka *et al.*, 2023). MDV is a cell associated virus having double stranded DNA of 160-180 kbp which is linear in nature (Witter *et al.*, 2005).

As far as the incidence of this disease in Pakistan is concerned, Haq *et al.* (2001), reported 20.77% prevalence of Marek's disease with mortality rate of about 11.6% in tehsil Gojra of Faisalabad (Pakistan). However, in Nigeria, the prevalence of neoplastic diseases was 7.58%, among which 85.90% cases were associated with MD (Sani *et al.*, 2017). Similarly, Azeem *et al.* (2023) reported 18.46% prevalence of Marek's disease in backyard poultry from Rawalpindi division of Pakistan. Horizontal transmission of MD occurs through dander and aerosolized dust while there is no vertical transmission. The virus enters into the body through respiratory tract, multiplies into feather follicle and is being shed through dander (Boodhoo *et al.*, 2016). The birds show variety of clinical symptoms, including diarrhea, anorexia,

progressive weight loss, prominent keel bone and drooping of wings. Upon necropsy, the birds show tumors in liver, spleen and kidney ultimately leading to the enlargement of respective organs (Zhang *et al.*, 2021).

The Marek's disease was very well controlled after the introduction of monovalent HVT vaccine in 1970, however, with the passage of time the efficacy of HVT vaccine was decreased due to interference with homologous maternal antibodies (Reddy *et al.*, 2017). After that, a bivalent vaccine (mixture of HVT and SB-1 strain) was introduced in mid-1980. When the virulence of virus increased, the attenuated strain CVI988 was introduced with the name 'Rispens' (Baigent *et al.*, 2016). Now a days Rispens + HVT is used for the efficient control of Marek's disease in the field.

Marek's disease is diagnosed on the basis of clinical signs and postmortem lesions (Mete *et al.*, 2016) and confirmed by detection of antigen through immunohistochemistry, virus detection through PCR and isolation of virus through cell culture or embryonated eggs (Stamilla *et al.*, 2020). Different lesions like tumors on visceral organ including heart, liver, kidney, spleen, muscles and leg paralysis confirms the clinical disease. (Birhan *et al.*, 2023).

No comprehensive data was found regarding the prevalence and serotypes of MD prevailing in Faisalabad division. Only one case report of 20.77% (43/207) prevalence of MD was observed in Gojra tehsil of district Toba Tek Singh from the accessible literature (Haq *et al.*, 2001) and recently Azeem *et al.* (2023) reported MD in backyard poultry from arid zone of Pakistan. There was a need to identify the prevalent serotypes of MD Faisalabad, Pakistan and to correlate the PCR positive samples with the clinical disease. Keeping in view this, the current study was planned to investigate the molecular prevalence and pathology of Marek's disease in layers and layer breeder in Faisalabad.

MATERIALS AND METHODS

Sampling Area: Samples were collected from Faisalabad division including three district named as Faisalabad, Toba Tek Singh and Jhang. Faisalabad division is situated between the latitude 30° and 31.5° north; and longitude 73° and 74° east. Multistage sampling in each district was made considering tehsils and poultry population in each tehsil.

Sampling Method: All the commercial farms of layer, layer breeder and non-descript layer birds were considered for sampling. Vaccine history was recorded at the time of sampling. A total of 3 birds from each farm (three birds were pooled to make one representative sample) were collected using simple random sampling technique. The sample size was calculated using formula described by Thrusfield (2007) and sample size was 384 considering expected prevalence of 50% because no prevalence data was found in Faisalabad division. However, in this study, 951 samples were collected (details in Table 1) and these samples were categorized according to the age groups, shed types, flock size and season.

Samples both for PCR and histopathology were collected separately. For histopathology liver, sciatic nerve and kidneys were preserved in 10% neutral buffered

formalin (NBF). Second part of sample was kept for PCR (DNA extraction), collected in zip bag and stored at -20°C for further processing.

Table 1: Prevalence of Marek's Disease according to type of birds

Sr. No.	Type of Birds	Total Samples	Positive	Mean (%)	SE (%)	Significance
1	Layer Breeders	30	2	6.67	5.57	a
2	Non-descript Layer	279	95	34.05	2.77	b
3	White Leghorn Layer	642	83	12.93	9.52	b

SE= Standard Error, Mean= Means of Percentage

Gross Lesions: Necropsy was performed and gross lesions (if present for Marek's disease) were noted on skin, breast muscles and visceral organs *i.e.* liver, spleen, kidney, nerve, proventriculus, heart and intestine etc.

Detection of MDV by Polymerase Chain Reaction (PCR):

Conventional polymerase chain reaction (PCR) was used to identify the oncogenic (MDV-1) form of Marek's disease virus. DNA was extracted using GeneJET® genomic DNA purification kit. The extracted DNA was further used for amplification via PCR. Amplification of extracted DNA was carried out by targeting the *Meq* gene. Already reported primers (forward 5'-GAGGTACCTCATGGACGTTCCACA-3' and reverse 5'-ACATTCTTTTCGTTGGCGTGGTAT-3') and for vaccinal strain (forward 5'-ATACCACGCCAACGAAAAGAATGT-3' and reverse 5'-CTATAGTACATATTGCATACCCAT-3') were used (Becker *et al.*, 1992). Steps involved were: initial denaturation at 95 °C for 2 minutes, denaturation at 94 °C for 1 minute, annealing at 55 °C for 1 minute, extension at 72 °C for 3 minutes and final extension at 72 °C for 5 minutes. The product size was 314 bp for the field strain and 686 bp for the vaccinal strain (Becker *et al.*, 1992). PCR product was visualized on 2% agarose gel with the help of Gel Doc apparatus using image lab software (Bio-Rad Gel Doc EZ Imaging System). Results were recorded by comparing the PCR product band with ladder along with positive and negative control.

On the basis of PCR results, prevalence was calculated at tehsil, district and division levels. Prevalence on the basis of different factors like type of birds, age group, housing type, flock size, season and presence of tumor was also calculated.

Histopathological Examination: For histopathological examination, visceral organs including kidney, liver, spleen and sciatic nerve were collected in 10% neutral buffered formalin. Tissue samples were cut into 3-5 mm thick pieces, which were processed through paraffin embedding technique. After that, tissue blocks embedded into paraffin were cut into sections having thickness of 2-3 um. Staining was done with hematoxylin and eosin staining protocol (Suma *et al.*, 2017).

Statistical Analysis: The prevalence percentage was calculated as:

$$\text{Prevalence percentage (\%)} = \frac{\text{No. of PCR +ve samples for MDV in a category}}{\text{Total no. of samples collected in a category}} \times 100$$

The categories analysed were type of birds, season of sampling, shed type, bird type, age of bird and geographical location of sampling (districts and tehsils) of division Faisalabad. Frequency analysis and factors were compared by Chi square test and 95% C.I. Percentage prevalence were calculated as means (%) and standard error (%) through SPSS software package.

RESULTS

Field Strain of Marek's Disease Virus (Serotype-1): PCR product targeting at 314 bp, confirmed the field samples (serotype-1 of MDV) (Fig. 1a) being the causative agent of Marek's disease.

Vaccinal Strain of Marek's Disease Virus (Serotype-3): The PCR product targeting at 686 bp, confirmed the presence of vaccinal strain (Serotype-3) in the collected samples (Fig. 1b).

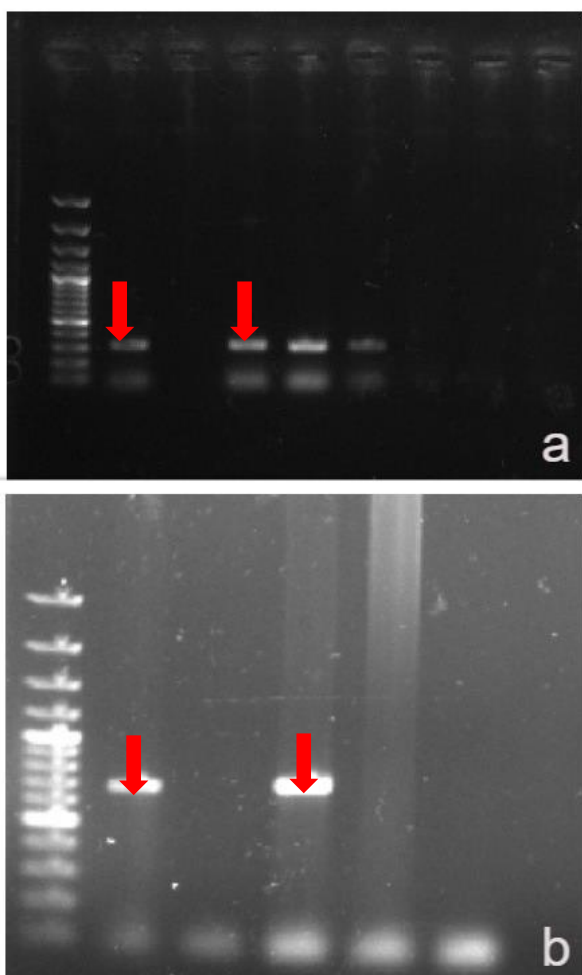


Fig. 1: 1a: Gel electrophoresis stained with ethidium bromide showing MDV-1 positive samples (Product size 314bp shown by red arrows). L = Ladder (100bp), Lane 1 = Positive control for MDV-1, Lane 2 = Negative control, Lane 3-5 = Positive samples and Lane 6-8 = Negative Samples. 1b: showing MDV-3 positive samples (Product size 686bp shown by red arrows) L = Ladder (100bp), Lane 1 = Positive control for MDV-3 Lane 2 = Negative control for MDV-3 Lane 3 = Positive samples for vaccinal strain of MDV-3 Lane 4-5 = Negative sample for vaccinal strain of MDV-3

Prevalence of Marek's disease virus (Serotype-1) infection in Faisalabad division: At the division level, the prevalence percentage of MDV-1 infection in Faisalabad

was 18.93%. A total of 180 samples were positive out of total 951.

Prevalence of Marek's disease virus on the basis of type of birds: The prevalence of MDV-1 was recorded in layer breeders (6.67%), non-descript layer birds (34.05%) and white Leghorn layer birds (12.93%) (Table 1).

District wise prevalence of Marek's disease virus infection: At districts level, the prevalence percentage of MDV-1 infection in Faisalabad division has been presented in Table 2. Prevalence was highest in Faisalabad followed by Jhang and Toba Tek Singh. In white Leghorn layer birds highest prevalence was found in district Toba Tek Singh (13.58%), in non-descript layer birds highest prevalence was found in district Jhang (50%) and in breeders the highest prevalence percentage was found in district Toba Tek Singh which was 13.33%.

Table 2: Prevalence of Marek's Disease in different districts of Faisalabad division

Sr. No	District	Total Samples	Positive	Mean (%)	SE (%)	Significance
1	Faisalabad	735	150	20.41	3.20	a
2	Jhang	96	15	15.62	6.34	ab
3	Toba Tek Singh	120	15	12.50	5.37	b

SE= Standard Error, Mean= Means of Percentage

Tehsil wise prevalence of Marek's disease virus: At the tehsil level, the prevalence percentage of MDV-1 infection has been presented in Table 3. The highest prevalence of Marek's disease was found in Tehsil Chak Jhumra (25%) and lowest in tehsils Kamalia and Gojra (11.11% each). In white Leghorn layer birds, the highest prevalence of MDV-1 infection was found in tehsil Peermahal (25.0%) while in layer breeder, the highest prevalence was observed in tehsil Kamalia (33.33%).

Table 3: Prevalence of Marek's disease virus in tehsils of Faisalabad division.

Sr. No.	Tehsils	Total Samples	Positive	Mean (%)	SE (%)	Significance
1	Ahmad Pur Sial	18	4	22.22	12.60	a
2	Athara Hazari	15	3	20.0	5.64	ab
3	Chak Jhumra	60	15	25.0	7.54	abc
4	Faisalabad	270	66	24.44	25.0	abc
5	Gojra	27	3	11.11	14.06	abc
6	Jaranwala	132	27	20.45	20.0	abc
7	Jhang	51	6	11.76	10.69	abc
8	Kamalia	54	6	11.11	5.26	ac
9	Peermahal	9	2	22.22	16.67	ac
10	Samundri	219	30	13.70	9.08	bc
11	Shorkot	12	2	16.67	7.13	c
12	Tandlianwala	54	12	22.22	12.50	c
13	Toba Tek Singh	30	4	13.33	11.11	c

SE= Standard Error, Mean= Means of Percentage

Prevalence of Marek's disease virus infection according to shed types: The prevalence was 12.36% in control sheds, 23.09% in open sheds and 16.67% in semi-control houses as shown in Fig. 2. In white Leghorn layer birds, the highest prevalence (17.05%) was observed in open shed, in non-descript layer birds the highest prevalence was 42.86% in semi control sheds, while birds 16.67% was found in semi control sheds.

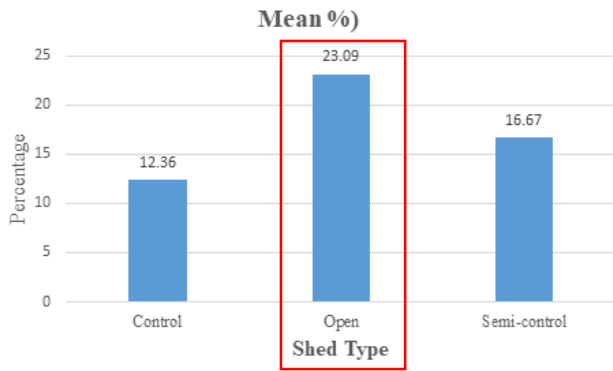


Fig. 2: Prevalence of Marek's disease virus based on Shed Type.

Prevalence of Marek's disease virus infection according to flock size: The prevalence of MDV-1 in flock size ranging was as; 1-10000 (23.01%), 10001-20000 (11.11%), 20001-30000 (26.44%), 30001-40000 (23.08%), 40001-50000 (20.0%), 50001-60000 (16.67%) and 60001-70000 (16.67%). The highest prevalence was recorded in flock size 20001-30000 that was 26.44% (Table. 4). In white leghorn layer birds, the highest prevalence was found in white Leghorn layer birds in flock sizes group 40001-50000 (20.0%). In non-descript layer birds, the highest prevalence was found in flock size groups 30001-40000 (75.0%).

Table 4: Prevalence of Marek's disease based on flock size.

Sr. No	Flock Size	Total Samples	Positive	Mean (%)	SE (%)	Significance
1	1-10000	465	107	23.01	8.66	a
2	10001-20000	243	27	11.11	13.06	ab
3	20001-30000	87	23	26.44	14.01	ab
4	30001-40000	39	9	23.08	16.67	ab
5	40001-50000	30	6	20.0	4.73	ab
6	50001-60000	30	5	16.67	NA	ab
7	60001-70000	18	3	16.67	0	ab

SE= Standard Error, Mean= Means of Percentage

Seasonal prevalence percentage of Marek's disease virus infection: The prevalence percentage of MDV-1 infection in different season was as; autumn (17.41%), spring (20.0%), summer (14.96%) and winter (26.48%) (Table 5). In all type of birds, the highest prevalence was found in winter season *i.e.* white Leghorn layer birds (17.42%), non-descript layer birds (45.83%) and breeder (13.33%).

Table 5: Prevalence of Marek's disease during different seasons.

Sr. No.	Seasons	Total Samples	Positive	Mean (%)	SE (%)	Significance
1	Autumn	201	35	17.41	5.67	a
2	Spring	150	30	20.0	6.43	ab
3	Summer	381	57	14.96	5.65	ab
4	Winter	219	58	26.48	3.85	b

SE= Standard Error, Mean= Means of Percentage

Age wise prevalence of Marek's disease virus infection: The age wise prevalence of MDV-1 infection at different age groups in weeks was as; 1-10 (16.31%), 11-20 (27.03%), 21-30 (20.37%), 31-40 (26.80%), 41-50 (22.22%), 51-60 (13.04%), 61-70 (9.09%) and 81-90 (22.22%) (Table 6). The highest prevalence in white

Leghorn layer birds was found at 11-20 weeks of age (21.74%) while the highest prevalence in breeder birds was found at 81-90 week of age (66.67%).

Table 6: Prevalence of Marek's disease according to different age groups.

Sr. No.	Age (weeks)	Total Samples	Positive	Mean (%)	SE (%)	Significance
1	1-10	282	46	16.31	7.37	a
2	11-20	111	30	27.03	8.76	ab
3	21-30	162	33	20.37	6.56	ab
4	31-40	153	41	26.80	22.22	abc
5	41-50	72	16	22.22	5.01	abc
6	51-60	69	9	13.04	9.53	abc
7	61-70	33	3	9.09	6.25	bc
8	81-90	9	2	22.22	0	c

SE= Standard Error, Mean= Means of Percentage

Prevalence percentage of Marek's disease virus infection on the basis of tumors: The prevalence percentage of MDV-1 infection in those birds having tumors was 72.40%, while in those birds having no tumor was 5.40% (Table 7).

Table 7: Tumor wise prevalence of Marek's disease virus infection.

Sr. No.	Status of tumors	Total Samples	Positive	Mean (%)	SE (%)	Significance
1	No	759	41	5.40	5.52	a
2	Yes	192	139	72.40	1.63	b

SE= Standard Error, Mean= Means of Percentage

Clinical Signs: Birds infected with MD showed different clinical signs like dysfunction of peripheral nerve, paralysis of extremities, stilted gait or incoordination, crop dilation, gasping and paralysis due to involvement of nerves. Birds with chronic lymphomas showed diarrhea, weight loss and birds were pale and depressed. Birds were unable to reach feeders and water drinkers due to leg paralysis. Some birds showed blindness due to ocular involvement.

Gross Lesions: Lymphomatous lesions were found on a variety of organs including heart, ovary, spleen, liver, bursa, heart, intestine, skin, proventriculus and skeletal muscles. Tumors on visceral organs were commonly found in virulent form of MD. These tumors were also present in the absence of nerve lesions. Lungs when palpated were hard and firm in texture. Liver of the birds was pale and granular in appearance due to diffused nodular infiltration shown in Fig. 3(d). Lymphomas appeared as diffused growth (double or more in size than the normal size) as shown in Fig. 3(a) with greyish or white discoloration. These lymphomas were either nodular or focal with different size shown in Fig. 3(c). The floated appearance of ovary became lost due to large tumors. The myocardium of the heart looked pale due to diffused infiltration of nodular tumors with pinpoint hemorrhages on myocardium. Sciatic nerve showed greyish discoloration and was edematous with loss of cross striations. Typically, brachial and sciatic nerves' plexi were larger than their respective trunks. Keel bone was prominent in most of the affected birds as shown in Fig.3(b) due to dehydration and starvation.

Histopathological Examination: The microscopic picture of Marek's disease positive hepatic parenchyma revealed severe cellular infiltration, indicative of the lymphomas. Inflammatory cells were pleomorphic in shape. At some

places giant cells were also present. Small granulomas were seen between hepatic cords. Moderate to severe degree of congestion, necrotic zones and vacuolar degeneration was present. Moderate to severe degree of perivascular cuffing was also present. Mitotic figures, congestion and fibroblast was also present in liver shown in Fig. 4 (a&b). The microscopic picture of renal parenchyma showed severe lymphocytic infiltration. Tubular cells were detached from basal membrane. Necrosis of tubular cells, congestion and hemorrhages were also present in tubular cells as shown in Fig. 5 (a&b). Microphotograph of sciatic nerve was indicating the necrotic changes. Inflammatory cells were found in nerve parenchyma (cellular infiltration). Nerve was distorted at some places as shown in Fig.6 (a&b). Splenic parenchyma showed that both white and red pulp had mixed population of cells, which were pleomorphic lymphocytes. There was no demarcation between red and white pulp. Splenic artery and vein were visible. Moderate to severe degree of necrotic changes was present in splenic parenchyma.

DISCUSSION

Livestock sector is a major part of agriculture-based GDP of Pakistan with a share of 14.63%. Poultry industry is the second largest industry in the country after textile industry. Poultry meat contributes 40.7% of total meat production in the country and every year its share is increasing by replacing mutton and beef (Anonymous, 2024).

Marek's disease (MD) is major neoplastic disease of poultry caused by herpesvirus named as Gallid alphaherpesvirus 2 (Oluwayinka *et al.*, 2023). It leads to heavy losses and mortality may go upto 10-30% (Biggs and Nair, 2012). The objectives of current study were to investigate the molecular prevalence of Marek's disease in layers and layer breeders in Faisalabad. The samples were collected from Faisalabad division to full fill these objectives. In current study a total 951 samples were collected and screened through PCR using specially designed primers specific for serotype-1. Out of these 951 samples, 180 (18.93%) samples were found positive for Marek's disease serotype-1 (MDV-1), which was 34.05% in nondescript birds, 12.93% in WLH and 6.67% in layer breeders. In contrast to our results recently from Rawalpindi division (arid zone) of Pakistan Azeem *et al.* (2023) reported prevalence of MD (13.96%) on basis of gross morphology and 18.46% on PCR basis in backyard poultry. However, in our study prevalence in backyard poultry or nondescript birds was higher i.e. 34.05%. The higher prevalence of MD in our study may be due to heavy population of backyard poultry in Faisalabad division as compared with Rawalpindi division (arid region). The possible reason for high prevalence of MD in nondescript birds in Pakistan may be improper vaccination that include sometimes monovalent vaccine, compromised nutrition and poor management as compared with WLH birds where there was low prevalence and these birds were vaccinated with updated bivalent vaccines of good quality.

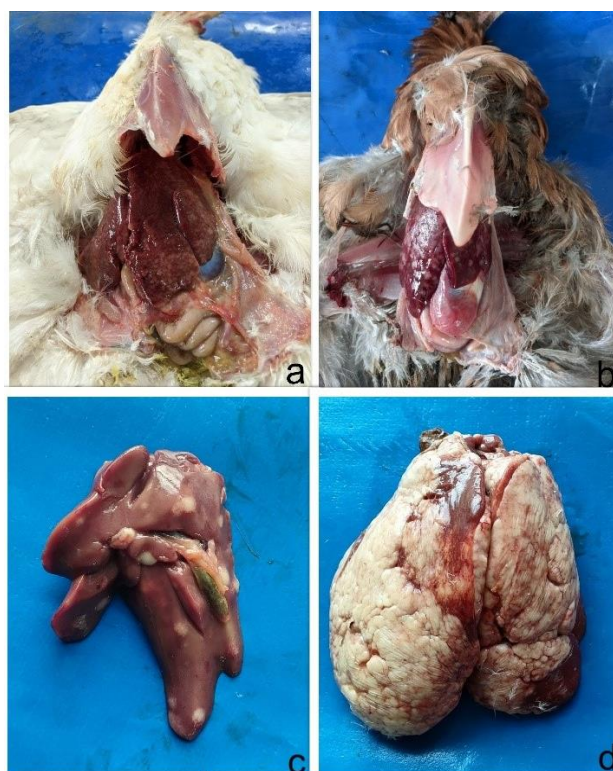


Fig. 3: Gross lesions of MD positive White leghorn layer (WLH) showing diffused lymphomas in liver (a) and nodular lymphomas in nondescript layer (b) nodular lymphomas on liver in WLH bird (c) and encapsulated liver with tumorous growth on liver in WLH bird (d).

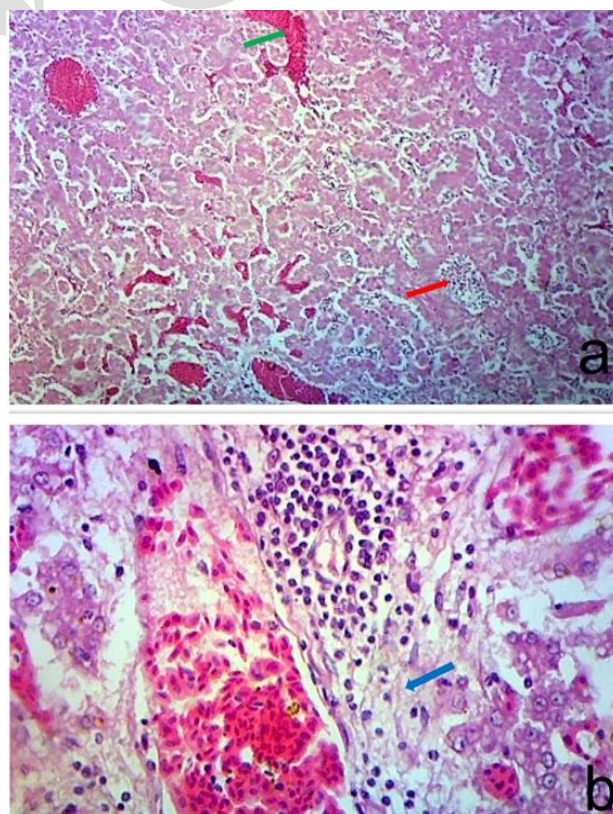


Fig. 4: The hepatic parenchyma in MD positive birds indicating hemorrhages and lymphoid cells aggregates (a) and in fig. 4.29b periportal fibrosis with pleomorphic lymphocytes in hepatic parenchyma by blue arrow (H & E staining 100X & 400X).

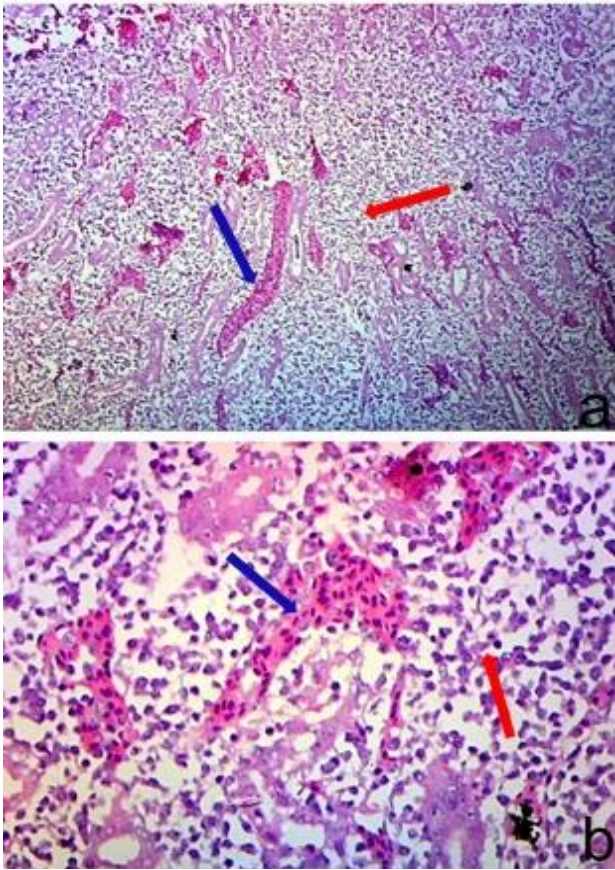


Fig. 5: Photomicrograph of kidneys in MDV positive bird is showing severe cellular infiltration (red arrows) with minimum normal parenchyma (b) & pleomorphic lymphocytes & congestion (blue arrow).

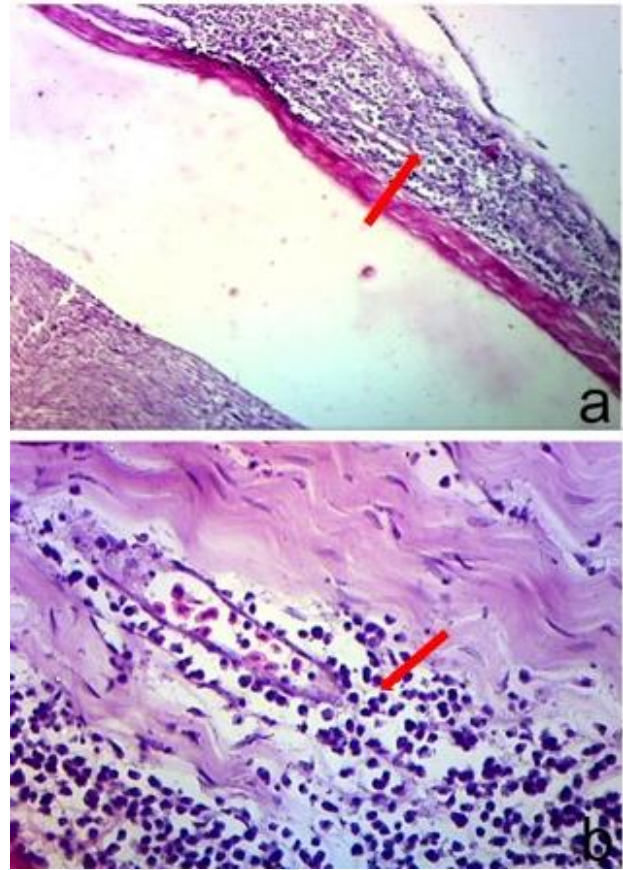


Fig. 6: Photomicrograph of sciatic nerve in MDV positive birds showing severe cellular infiltration of pleomorphic lymphocytes shown by red arrows in both figures a & b (H & E Staining 100X & 400X).

Similar to our results Sani *et al.* (2017) from Nigeria reported 7.58% (234/3085) prevalence of avian neoplastic diseases. The overall prevalence of MD was 6.25% (201/3085) while that of avian leucosis (AL) was 1.07% (33/3085). In contrast to our findings Wajid *et al.* (2013) reported prevalence of MD (49.5%) from Iraq with no significant difference among different provinces. The reason for this high prevalence in comparison to our study may be that all samples collected from Iraq were of birds nonvaccinated for MD, while in current study samples were collected from vaccinated birds. Trang *et al.* (2022) from Vietnam also reported MDV-1 accounting for 7.37% positive samples in non-vaccinated birds. Similar to our results Suresh *et al.* (2015) reported 57.5% and 25% MDV prevalence in vaccinated layers with monovalent and bivalent vaccination format respectively from India but these samples were collected from birds affected in an outbreak of MD. Othman and Aklilu, (2019) reported 53.33% positive samples for MDV-1 in layers and broiler breeders. Zhang *et al.* (2015) reported from China that the Marek's disease virus (MDV) is continuously evolving, and more virulent MDV pathotypes are emerging, thereby reducing the effectiveness of the existing vaccines. Walkden-Brown *et al.* (2013) from Australia reported that 23.1% of samples were positive for MDV-1, 26.1% in unvaccinated and 16.4% in vaccinated chickens. These findings were in line with our results.

At District level, the prevalence percentage in districts of Faisalabad divisions, including Faisalabad, Jhang and Toba Tek Singh were 20.41, 15.62 and 12.5%

respectively. At the tehsil level, the prevalence percentage of MDV-1 infection was highest in tehsil Chak Jhumra (25%) and lowest prevalence was found in Kamalia and Gojra (11.11% each). From Pakistan at tehsils level the incidence rate was 20.77% (Haq and Siddique, 2001) which addressed only tehsil Gojra. From Rawalpindi division recently 18.43% prevalence was reported in backyard poultry by Azeem *et al.* (2023). Similar to our results from Iraq prevalence ranged from 36.8% (Karbala and Nasiriyah) to 65% (Amarah). The percentages of positive samples were 59.1%, 46.7%, and 48.1% in broiler dust, broiler spleen, and layer spleen, respectively (Wajid *et al.*, 2013). Moreover, in Mizoram India, out of 89 samples 34 samples were found positive for MDV antigen. (Bhutia and Damodar, 2017).

On the basis of housing, the prevalence in control shed was 12.36%, in open sheds it was 23.09% while in semi-control sheds the prevalence was 16.67%. The highest prevalence was recorded in open sheds.

On the basis of flock size, the highest percentage prevalence was 26.44% found in 20001-30000 birds flock size and lowest in 10001-20000. No Sample was found positive in flock size ranging above 80000. On the basis of seasons, the prevalence percentage of Marek's disease in autumn, spring, summer and winter was 17.41, 20.0, 14.96 and 26.48% respectively. In contrast to our study, Sailen *et al.* (2017) reported that high incidence of Marek's disease was found in rainy and dry season i.e. September and June in Tanzania.

The age wise prevalence of Marek's disease was highest (27.03%) in 11-20 weeks age group and lowest (9.09%) was in 61-70 weeks age group. From India among the overall prevalence of 20%, none of the samples were found positive in 1-15 days age group, whereas 33.36% were found positive in 16-40 days age group (Saravanajayam *et al.*, 2020). In Nigeria the average age of poultry affected was 20.17 (SD±2.6) weeks for MD (Sani *et al.*, 2017). Gall *et al.* (2018) reported that the onset of neurological signs was at 4-8 weeks of age and lasted up to 22 weeks of age. Similarly, Lounas *et al.* (2021) reported occurrence of MD in 13 to 22 weeks of age more as compared with other age groups. From Tanzania, Sailen *et al.* (2017) reported that high incidence of Marek's disease was found at 10-16 weeks of age. On the basis of tumor found during sampling the prevalence percentage in those birds having tumors was 72.40%, while in those birds having no tumor was 5.40%. Similar to our results Azeem *et al.* (2023) reported that 75.76% MD positive samples were having tumors in gross lesions. From Malaysia, Othman and Aklilu (2019) reported 53.33% positive samples for MDV-1 in layers through PCR. Mete *et al.* (2016) reported that there was significance difference between poultry birds having tumors and without tumors.

Birds were pale, depressed and exhibited gasping, diarrhea, weight loss, incoordination, stilted gait and paralysis of leg due to involvement of sciatic nerve. Memon *et al.* (2013) reported the nerve damage, paralysis of legs and wings, diarrhea, gasping and loss of weight in broiler birds in Hyderabad, Pakistan. Similar signs and gross lesions were reported by Azeem *et al.* (2023) in backyard poultry from Rawalpindi division Pakistan. Zhang *et al.* (2021) also reported MD associated clinical signs like dropping of wings, weight loss, prominent keel bon, diarrhea, anorexia and grey abdomen. Biggs and Nair (2012) also reported all the classical and advanced clinical signs in birds infected with MDV. Similarly, Adedeji *et al.* (2022) also reported similar clinical picture from Nigerian flocks infected with MDV. Lounas *et al.* (2021) reported digestive, respiratory, nervous and digestive signs and lesions in MD infected birds.

At the time of necropsy tumors were found on almost every visceral organs including heart, liver, spleen, intestine, kidney, proventriculus and skeletal muscles. Lungs were found hard and firmed in texture in few cases. Both kind of lymphomas (diffused and nodular) were found which increased the size of organs. The floated structure of ovary became lost due to large tumors. Memon *et al.* (2013) and Azeem *et al.* (2023) reported the lymphoma development in different visceral organ like spleen, liver, kidney and heart in broiler birds and backyard poultry respectively from Pakistan. Kamaldeep *et al.* (2007) reported the tumor in spleen, liver, kidney and ovary in MD in Haryana (India). Stamilla *et al.* (2020) reported the lesions of MD in intestine, size of liver was increased, spleen was hyperplastic and fatty in consistency. There was hypertrophy of secretory gland of proventriculus. Enlargement of kidney, spleen and liver was reported by Zhang *et al.* (2021). Marek's disease is a prominent lymphoproliferative infectious disease (Bertzbach *et al.*, 2020). Biggs and Nair (2012) also reported all lesions including lymphomas in breast muscles in birds infected with MDV. Similarly, Adedeji *et al.* (2022) also reported

similar lesions from Nigerian flocks infected with MDV. Lounas *et al.* (2021) reported digestive, respiratory symptoms and nervous lesions in MD infected birds with lymphomatosis.

The microscopic picture of Marek's disease positive renal, hepatic, splenic and nerve parenchyma indicated severe T-lymphocyte infiltration throughout parenchyma. These cells were pleomorphic in shape. Vacuolar degeneration was also found in hepatic parenchyma along with congestion and necrosis. Both red and white pulp had mixed population of cells, which were pleomorphic lymphocyte. Kamaldeep *et al.* (2007) reported the infiltration of pleomorphic cells like lymphoblast, small and large lymphocyte and plasma cells in different organs having lymphomas in MD in Haryana (India) in vaccinated birds. Yavuz and Erer (2017) and Biggs and Nair (2012) reported the infiltration of lymphoblast and lymphocyte in different visceral organs in lying hen infected with MD. Bertzbach *et al.* (2020) reported the MD as lymphoproliferative in nature. Tumor cells invade and proliferate to develop the tumor (Zhang *et al.*, 2021). Lounas *et al.* (2021) also reported lymphoblast infiltration in nerve tissues.

Conclusions: The current study concluded that MDV-1 serotype was frequently found in Faisalabad division with highest prevalence being observed in district Faisalabad. Non-descript layer birds were more prone to MDV as compared to other bird types. Open sheds were at higher risk of Marek's disease infection. Similarly, incidence of Marek's Disease was high in winter season and the highest prevalence was recorded at 11-20 and 31-40 week of age. Marek's disease is reemerging in Pakistan therefore proper vaccination schedule with good quality vaccines should be adopted both in commercial and backyard poultry.

Authors contribution: MWT executed the research, sample collection and laboratory analysis, MKS designed and executed the research, write up of manuscript, MTJ was involved in experimental design and statistical analysis and MS was involved in manuscript preparation and improvement

Acknowledgement: This research was funded by Higher Education Commission of Pakistan under HEC Indigenous Scholar Program Phase II Batch VI.

REFERENCES

- Adedeji A, Abdu P, Akanbi O and Luka P, 2022. Molecular and pathological investigations of Marek's disease outbreaks in vaccinated poultry farms in plateau state, north central- Nigeria. *Vet Ital.* 58(1):77-85.
- Anonymous, 2024. Pakistan Economic Survey. 2023-24. Chapter No.2 Agriculture pp: 21-38. Published by Finance and Economic Affairs Division, Ministry of Finance, Govt. of Pakistan, Islamabad, Pakistan.
- Azeem M, Saleem G, Mushtaq MH, 2023. Marek's disease in backyard chickens of Pakistan: A study of pathological lesions in correlation to viral load. *South African J Anim Sci.* 53(6):798-08.
- Baigent SJ, Nair VK, and Galludec H L, 2016. Real-time PCR for differential quantification of CVI988 vaccine virus and virulent strains of Marek's disease virus. *J Virol Methods.* 233:23-36.
- Becker Y, Ashera Y, Tabora E, and Davidson I, 1992. Polymerase chain reaction for differentiation between pathogenic and non-pathogenic serotype I Marek's disease viruses (MDV) and vaccine. *Viruses.* 40: 307-22.

- Bertzbach LD, Conradie AM, You Y and Benedikt BK, 2020. Latest insights into Marek's disease virus pathogenesis and tumorigenesis. *Cancers* 12:647.
- Bhulia LD and Singh YD, 2017. Marek's disease outbreak in poultry population of Mizoram, India. 224-27.
- Biggs J and Nair V, 2012. The long view: 40 years of Marek's disease research and Avian Pathology. *Avian Pathol*, 4(1): 3-9.
- Birhan M, Gelaye E, Ibrahim SM, et al., 2023. Marek's disease in chicken farms from Northwest Ethiopia: gross pathology, virus isolation, and molecular characterization. *Virology* 20: 45.
- Boodhoo N, Gurung A, Sharif S, et al., 2016. Marek's disease in chickens: a review with focus on immunology. *Vet Res* 47:1-19.
- Gall S, Körösi L, Cortes AL, et al., 2018. Use of real-time PCR to rule out Marek's disease in the diagnosis of peripheral neuropathy. *Avian Pathol*. 47: 427-33.
- Haq AU and Siddique M, 2001. Epidemiological study of Marek's disease in commercial layer flocks in district toba tek sing. *Pak Vet J*. 21:198-01.
- Kamaldeep P, Sharma C and Narang G, 2007. Occurrence of Marek's disease in vaccinated poultry flocks of Haryana (India). *Int J Poultry Sci*. 6(5):372-7.
- Lounas A, Besbaci M, Akkou M, et al., 2021. Occurrence of Marek's disease in vaccinated Algerian broiler breeder flocks: A histopathological survey. *Vet World*, 14:3021.
- Memon ZN, Shah AM, and Gachal GS, 2013. Study on the gross pathology in broilers affected with Marek's disease in commercial broiler poultry farms of Hyderabad and adjoining areas, Sindh, Pakistan. *Sindh Uni. Res. J*. 45:(2) 225-228.
- Mescalini G, Lupini C, Davidson I, et al., 2020. Marek's disease viruses circulating in commercial poultry in Italy in the years 2015–2018 are closely related by their meq gene phylogeny. *Transbound Emerg Dis*. 67:98-107.
- Mete A, Gharpure R, Pitesky ME, et al., 2016. Marek's disease in backyard chickens, a study of pathologic findings and viral loads in tumorous and non-tumorous birds. *Avian Dis* 60:826-836.
- Nair V, Gimeno I, Dunn J, et al., 2020. Neoplastic diseases. In: *Diseases of Poultry: Vol 1: Agents* (Nair I, J Gimeno, G Dunn, G Zavala, SM Williams, RL Reece and S. Hafner, Eds.): John Wiley & Sons, Inc, New York, USA, pp. 548-715.
- Oluwayinka EB, Otesile EB, Oni OO, et al., 2023. Molecular characterization and phylogenetic analysis of Marek's disease virus in chickens from Ogun State, Nigeria. *Avian Pathol* 52:401-411.
- Othman I and Aklilu E, 2019. Marek's disease herpesvirus serotype 1 in broiler breeder and layer chickens in Malaysia. *Vet World*. 12(3):472.
- Reddy SM, Izumiya Y, Lupiani B, et al., 2017. Marek's disease vaccines: Current status, and strategies for improvement and development of vector vaccines. *Vet Microbiol* 206:113-20.
- Sailen AM, Marisa IM, Masanja P, et al., 2017. Trends in diagnosis of Marek's Disease (MD) in poultry at Central Veterinary Laboratory in Dar es Salaam, Tanzania. (2017): 54-57.
- Sani NA, Aliyu HB, Musa IW, et al., 2017. A nine - year retrospective study of avian neoplastic diseases in Zaria, Kaduna state, Nigeria. *Sokoto J Vet Sci* 15:36-41.
- Saravanajayam M, Palanivel KM, Selvaraju G, et al., 2020. Molecular detection of Marek's disease virus-1 (MDV-1) in the commercial broiler chicken of Tamil Nadu, India. *J Entomol Zool Stud* 9: 1571-74.
- Stamilla, A, Messina A, Condorelli L, et al., 2020. Morphological and Immunohistochemical Examination of Lymphoproliferative Lesions Caused by Marek's Disease Virus in Breeder Chickens. *Animals*. 10:1280.
- Suma US, Rahman MW, Nooruzzaman M, et al., 2017. Pathology of Marek's disease in layer chickens in Bangladesh. *The Bangladesh Vet*. 34:(2) 35-41.
- Suresh P, Sukumar K, Harikrishnan TI and Srinivasan P, 2015. Pathotyping of recent Indian field isolates of Marek's disease virus serotype 1. *Acta Virologica*. 1;59(2):156-65.
- Swayne, D.E., M. Boulianne, C.M. Logue L.R. Macdougald, V. Nair and D.L. Suarez. 2020. *Diseases of Poultry*, 14th Ed. Wiley Blackwell, Ames, IA, USA.
- Thrusfield M, 2007. *Surveys*. In: M. Thrusfield (Ed 3rd), *Veterinary Epidemiology*. Oxford, UK, pp. 228-242.
- Trang HN, Nguyen TPC and Thu HTV, 2022. Prevalence of Marek's disease virus in unvaccinated healthy backyard chickens in Cantho city, Vietnam and genetic characterization of meq gene. *Vet. Integr. Sci*. 20: 709-718.
- Wajid, Salih I, Margaret EK, et al., 2013. Prevalence of Marek's disease virus in different chicken populations in Iraq and indicative virulence based on sequence variation in the EcoRI-Q (meq) gene. *Avian Dis*. 57: 562-568.
- Walkden-Brown SW, Islam A, Groves PJ, et al., 2013. Development, application, and results of routine monitoring of Marek's disease virus in broiler house dust using real-time quantitative PCR. *Avian Dis*. 57: 544-554.
- Witter, RL, 2005. Marek's disease: the continuing struggle between pathogen and host. *Vet. J*. 170: 149-150.
- Yavuz O and Erer H, 2017. Immunohistochemical and immunocytochemical findings associated with Marek's disease virus in naturally infected laying hens. *Biotech. Histochem*. 92: 498-505.
- Zhang YP, Li ZJ, Bao KY, et al., 2015. Pathogenic characteristics of Marek's disease virus field strains prevalent in China and the effectiveness of existing vaccines against them. *Vet. Microbiol*. 177:62-68.
- Zhang Z, Zhang S, Wang S, et al., 2021. Role of microRNA and long non-coding RNA in Marek's disease tumorigenesis in chicken. *Res Vet Sci* 135: 134-42.