



RESEARCH ARTICLE

Biometric and Ultrasonographic Evaluation of the Testis of One-humped Camel (*Camelus dromedarius*)

Riaz Hussain Pasha, Anas Sarwar Qureshi*, Laeeq Akbar Lodhi¹ and Huma Jamil¹

Department of Anatomy; ¹Department of Theriogenology, Faculty of Veterinary Science, University of Agriculture, Faisalabad, Pakistan

*Corresponding Author: anas_sarwar@hotmail.com

ARTICLE HISTORY

Received: October 08, 2010
Revised: December 01, 2010
Accepted: December 12, 2010

Key words:

One-humped camel
Epididymis
Season
Testis
Ultrasound imaging

ABSTRACT

Twenty four adult clinically healthy one-humped male camels (*Camelus dromedarius*) were examined three times (beginning, mid and end) in each season (winter, spring, summer and autumn) for establishing the normal ultrasonic appearance and seasonal changes in the testicular parenchyma in the natural ecology of Punjab, Pakistan. The testes of each camel were scanned by using a B-mode real time ultrasound scanner fitted with a 7.5-MHz linear-array transducer. Scrotal biometry was done with the measuring tape during all the seasons of year. The tunics of the testes appeared as hyperechoic lines surrounding the homogenous, moderately echogenic parenchyma of the testis. The mediastinum testis was visualized as hyperechoic central line and a spot, in longitudinal and transverse sections, respectively. During winter season, the parenchyma was hyperechoic and mediastinum testis was seen as thin hyperechoic line. In spring, the echogenicity of parenchyma was moderate and mediastinum appeared relatively thick central hyperechoic line. In summer and autumn, less echoic parenchyma and thick band of mediastinum was recorded. Biometric studies showed significantly ($P < 0.01$) higher scrotal length and width of the testis during winter and spring season as compared to summer and autumn. Present study revealed that the ultrasonic structure of camel testis resembles other mammals and season has an apparent effect on the testicular size and echogenicity of the testicular parenchyma in the one-humped camel.

©2011 PVJ. All rights reserved

To Cite This Article: Pasha RH, AS Qureshi, LA Lodhi and H Jamil, 2011. Biometric and ultrasonographic evaluation of the testis of one-humped camel (*Camelus dromedarius*). Pak Vet J, 31(2): 129-133.

INTRODUCTION

One-humped camel is a seasonal breeder and shows sexual activity during specific period of year known as rut or musth. Seasonal changes have evident effect on the morphology of the testicular tissue and activity of Leydig cells in dromedary (Tingari *et al.*, 1984; Friedlander *et al.*, 1984). The testicular weight and size (Length, width and circumference) significantly ($P < 0.01$) increase during the breeding season of the camel compared to non-breeding season (Zayed *et al.*, 1995; Masood, 2007).

Ultrasound is a non-invasive and harmless technique, which has been used for the diagnosis of several types of testicular abnormalities in the human medicine. This technique was established in 1990 as a practical tool for animal production and has been declared as a revolutionary research tool in reproductive biology (Pierson and Ginther, 1988). For the use of ultrasonography as a reliable diagnostic tool for male reproductive problems, it is must to establish the normal ultrasonographic

manifestation of the testis. Some workers have reported research applications of ultrasonography in different species of animals including Female dromedary (Skidmore and Adams, 2000; Tibary and Anouassi, 2000), bovine (Pechman and Eilts, 1987; Pierson and Ginther, 1988), caprine and ovine (Ahmad *et al.*, 1991; Gouletsou *et al.*, 2003). Nevertheless, to the best of our knowledge, there is no report on the ultrasonographic appearance of the testis of male one-humped camel (*Camelus dromedarius*). Thus the objective of the present work was to describe the normal ultrasonographic structure of camel testis and to monitor the seasonal changes in the testicular parenchyma of one-humped camel.

MATERIALS AND METHODS

Animals

A total of 24 adult sexually mature male camels, aged 5 to 9 years with clinically normal testes, from three districts namely; Faisalabad (n=12), Attock (n=6) and

Bhakkar (n=6) located in the Punjab, Pakistan, were used in the present study. In Faisalabad two male camels were kept in the Department of Anatomy, University of Agriculture, Faisalabad and 10 privately owned animals were used, whereas in Attock 3 animals were used from the Barani Livestock Production & Research Institute (BLPRI) Kharimurat, Attock and in Bhakkar 3 camels were used from Camel Breeding & Research Station, Rakhmani. Equal number of privately owned camels was included from the neighboring localities of these farms at both districts. To compare the seasonal ultrasonographic changes in the testes, the study was conducted during four seasons of the year 2008, namely winter (December to February), spring (March to April), summer (May to September) and autumn (October to November).

Clinical Examination

All the experimental animals were examined for general health status and the appearance of genitalia. The testes were palpated and observed for their size, shape, free movement and position in the scrotum. The scrotal skin was observed for any kind of lesions. As the epididymis is present on dorsum of testis in camel, only tail of epididymides were palpated for the size and flexibility.

Scrotal length and width of the testis of all experimental camels were recorded by measuring tape during each season of the year at all the experimental zones under study.

Ultrasound Imaging of the Testis and Epididymis

All the camels under study were examined three times (beginning, mid and end) during all four seasons of the year at each experimental zone. The testes of each male camel were scanned while restrained in the sitting position without using any sedative using a B-mode real time ultrasound scanner (Picker CS 9100-Model EUB-405 Tokyo, Japan) equipped with a 7.5-MHz linear-array transducer. The scrotal skin was washed before the application of ultrasound gel to improve the penetration of sound waves through the skin. As camel has non-pendulous scrotum, prior to scanning, the testes were pulled down very gently within scrotum and maintained there by the left hand. Each testis was scanned, by placing transducer directly on the scrotal skin. For transverse view, the transducer was placed perpendicularly to its long axis while moving it from dorsum to the ventral edge of the testis, which produced a round image of the testicular parenchyma. For longitudinal view, the transducer was placed vertically parallel to the long axis of the testis.

Statistical analysis

The means (\pm SEM) and ranges of biometric parameters (length and width of testes) were worked out using the computer software package Microsoft Excel (Microsoft Office 2003). Data were subjected to one-way analysis of variance (ANOVA). Significance among different mean parameters was calculated at $P < 0.05$ by Duncan's multiple range (DMR) test.

RESULTS

Scrotal Biometry of the Testis

The mean of scrotal length and width of right and left testis are given in Table 1. Scrotal length of right and left testis were significantly ($P < 0.01$) higher during winter and spring seasons as compared to summer and autumn at all zones under study. Statistical analysis revealed that the overall means of scrotal width of right and left testis were significantly ($P < 0.01$) higher during winter and spring seasons as compared to summer and autumn at all the zones, while this parameter was recorded as significantly ($P < 0.01$) higher at Attock zone as compared to Bhakkar and Faisalabad (Table 1). This may be attributed to the long breeding season and climate in the Attock zone.

Table 1: Comparative means (\pm SEM) of scrotal length and width of right and left testes of one-humped camel at different zones of Punjab, Pakistan during all the seasons of the year.

Parameters	Seasons	Zones under study		
		Faisalabad	Attock	Bhakkar
SLRT (cm)	Winter	19.93 \pm 0.34b	22.25 \pm 1.09a	22.01 \pm 0.68a
	Spring	19.60 \pm 0.37	20.83 \pm 1.19	20.81 \pm 0.54
	Summer	17.84 \pm 0.26	17.04 \pm 0.54	16.68 \pm 0.28
	Autumn	17.91 \pm 0.28	17.25 \pm 1.16	18.79 \pm 0.76
SLLT (cm)	Winter	21.30 \pm 0.38b	22.99 \pm 1.06a	23.06 \pm 0.88a
	Spring	21.00 \pm 0.33	21.21 \pm 1.35	20.42 \pm 0.45
	Summer	18.79 \pm 0.25	17.88 \pm 0.63	17.45 \pm 0.31
	Autumn	19.05 \pm 0.34cd	17.79 \pm 0.97d	20.71 \pm 0.79b
SWCRT (cm)	Winter	11.69 \pm 0.25	15.67 \pm 0.82	13.72 \pm 0.39
	Spring	10.16 \pm 0.24	15.04 \pm 1.03	12.71 \pm 0.49
	Summer	7.70 \pm 0.19	12.13 \pm 0.47	10.17 \pm 0.27
	Autumn	7.55 \pm 0.26	11.58 \pm 0.60	10.96 \pm 0.44
SWCLT (cm)	Winter	12.36 \pm 0.22	16.36 \pm 0.89	15.24 \pm 0.62
	Spring	11.09 \pm 0.20	15.38 \pm 1.06	13.46 \pm 0.41
	Summer	8.67 \pm 0.15	12.88 \pm 0.49	10.99 \pm 0.28
	Autumn	8.29 \pm 0.26	12.06 \pm 0.68	11.75 \pm 0.61

Means bearing different letter in a row are differ significantly ($P < 0.05$). SLRT=Scrotal length of right testis; SLLT=Scrotal length of left testis, SWCRT= Scrotal width center of right testis; SWCLT= Scrotal width center of left testis.

Normal Ultrasonographic Appearance of Testis and Epididymis

The one-humped camel testes are surrounded by tough tunics and capsule, which appeared as hyperechoic border lines of the parenchyma in longitudinal scans a thin anechoic line was found in between the two (parietal and visceral) layers of the tunica vaginalis. The mediastinum testis was visualized as a hyperechoic central linear structure in the parenchyma. The testicular parenchyma was identified as moderately echogenic and homogenous (Fig. 1a).

In transverse images the tunics were appeared as hyperechoic borders with central anechoic fluid filled thin area. The mediastinum testis was observed as central, nearly circular hyperechoic area in the mid of the parenchyma (Fig. 1b). The tail of epididymis appeared as heterogeneous less echogenic structure as compared to the testicular parenchyma (Fig. 1c). The epididymal head and body were not accessible and could not be imaged due to anatomical topographic location of the epididymis on the dorsal or cranial surface of the testes in camels.

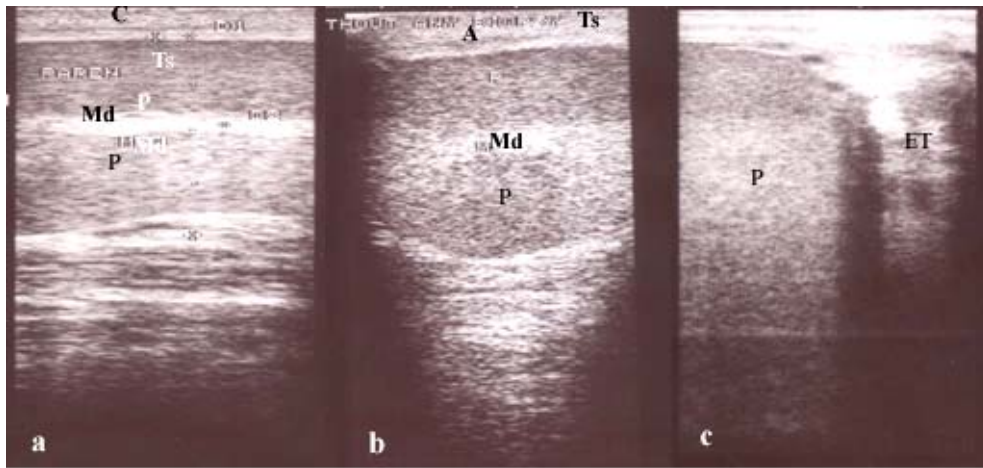


Fig. 1: Longitudinal (a) and transverse (b) sectional ultrasonographs of the camel testes and transverse sectional ultrasonograph (c) of tail of epididymis showing; Ts =Tunica, C=Capsule P=Parenchyma of testis, Md=Mediastinum, A=Thin anechoic area within the tunics elaborating; ET=Epididymal tail, P=Testicular parenchyma

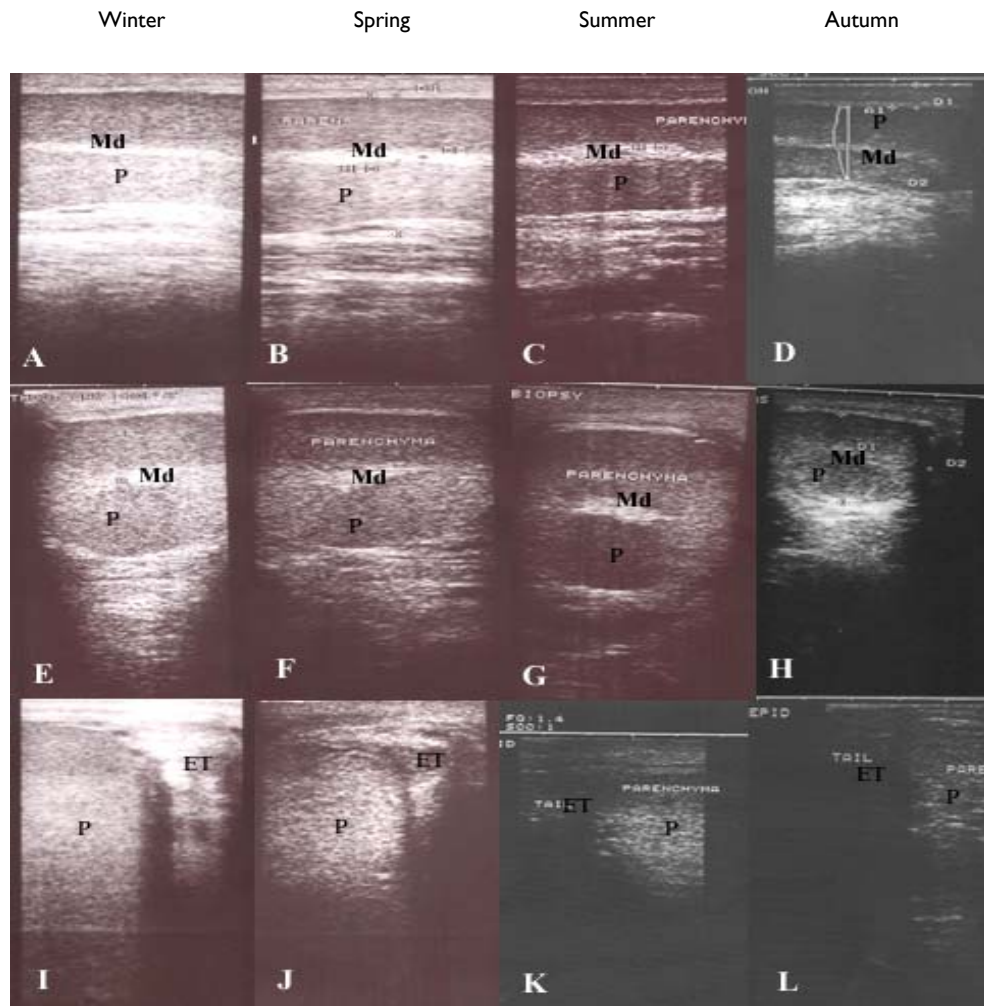


Fig. 2: Longitudinal (A, B, C and D) and transverse (E, F, G and H) sectional ultrasonographs of the camel testes and transverse ultrasonograph of right (I and J) and left side (K and L) of tail of epididymis elaborating seasonal changes: Winter: More echogenic parenchyma (P), Spring: moderate echogenicity, Summer: less echogenic and thicker mediastinum (Md) while in autumn parenchyma appeared as least echogenic and minimum interstitial connective tissue. P=Parenchyma, Md=Mediastinum, ET=Epididymal tail

Seasonal changes in ultrasonic appearance of the testis and epididymis

During winter, the testicular parenchyma was evident as more echogenic compared to other months of the year. The mediastinum testis was visualized as a thin hyperechoic line in the centre of the parenchyma (Fig. 2A and 2E). The tail of epididymis was more echogenic in this season, presumably indicating the presence of more sperms as compared to other seasons (Fig. 2I). In spring, the testicular parenchyma was seen as high to moderate echogenic. The mediastinum appeared as thick central echogenic band (Fig. 2B and 2F). While the tail of epididymis was imaged as moderately echogenic during this season (Fig. 2J).

During summer, the testicular parenchyma appeared as less echogenic and mediastinum was visualized as thicker band with scattered texture and less echogenicity (Fig. 2C and 2G). The tail of epididymis was evident as less echogenic compared to winter and spring seasons (Fig. 2K). During autumn, the testicular parenchyma appeared as least echogenic and reduced in size due to decrease in the interstitial contents (Fig. 2D and 2H). The tail of epididymis was identified as less echoic as compare to other seasons (Fig. 2L).

DISCUSSION

The present study was performed to record the seasonal changes in the scrotal size of the testis, to document the normal echotexture of the testis and epididymis of one-humped camel and to evaluate the seasonal changes in the echotexture of the testicular parenchyma at three different zones of Punjab, Pakistan. The measured dimensions (Scrotal length and width) of the testis were significantly ($P < 0.01$) higher during the winter and early spring seasons as compared to summer and autumn. These results are in line with the previous findings (Tingari *et al.*, 1984).

Ultrasonically, testicular parenchyma appeared as homogenous and moderate echogenic which is similar to the other animals reported earlier like bulls (Pechman and Eilts, 1987), boars (Cartee *et al.*, 1986), caprine and ovine (Gouletsou *et al.*, 2003; Ahmad *et al.*, 1991) and rabbit (Aksoy *et al.*, 2009). The testicular capsule appeared as thick hyper-echoic structure and tunics were identified as hyperechoic lines in both longitudinal and transverse planes, covering the parenchyma. A thin intratunical anechoic linear area was identified, because of fluid between the connective tissue coverings. Similar findings have been recorded in rams (Ahmad *et al.*, 1991) and bulls (Pechman and Eilts, 1987). But these tunics were undifferentiated and appeared as single hyperechoic band surrounding the parenchyma in rabbits (Aksoy *et al.*, 2009). Mediastinum testis, a heap of connective tissue, was a consistent ultrasonographic feature in all scanned testes. It was visualized as a hyperechoic central line in the longitudinal images and a central hyperechoic circular area in transverse plane which is in line with the findings in bucks and rams (Gouletsou *et al.*, 2003; Ahmad *et al.*, 1991) and bulls (Cartee *et al.*, 1989). Because of the anatomical topographic location of epididymis in camels, only tail was visible and approachable. It was identified as

heterogeneous and less echoic than the testicular parenchyma which resembles with the findings in rabbits (Aksoy *et al.*, 2009) and rams (Gouletsou *et al.*, 2003). However, in men the head is visualized as most clear and visible, while tail is not detectable (Lavoipierre, 2000). In the present study, the body and head of epididymis and pampiniform plexus were not detectable due to the anatomical location of these organs on the dorsal or cranial surface of camel testes.

Season had a prominent effect on the echotexture picture of the testis and epididymis at all the experimental zones. During breeding season (winter and early spring), there is significant increase in the volume of interstitial contents, activity of the tubular germ cells and increase in the mature germ cells (Singh and Bharadwaj, 1978; Zayed *et al.*, 1995). As echogenicity is related to the activity of the germ cells of seminiferous tubule and presence of increased number of mature germ cells (Evans *et al.*, 1996), the testicular parenchyma appeared as more echogenic during breeding season of the camel.

Testicular parenchyma was visualized as less echoic in summer and least echogenic in the autumn season, probably due to inactivity of the germ cells and reduced number of mature germ cells. Interstitial connective tissue content begins to decline in summer and become very narrow and reduced in the autumn (Zayed *et al.*, 1995). Though spermatogenesis is a continuous process throughout year (Tingari *et al.*, 1984) but the activity of tubular germ cells start to turn down in summer and become least dynamic in autumn (Singh and Bharadwaj, 1978). These anatomical seasonal changes directly affect the ultrasonic picture of the testis in the one-humped camel.

Conclusions

The results of the present study indicate that ultrasonography is a proficient tool for the examination of camel testes and epididymis. The ultrasonographic appearance structure of camel testis resembles other mammals. Season has an apparent effect on the testicular size, echogenicity of the testicular parenchyma and epididymis in one-humped camels.

Acknowledgements

We thank the financial support of Higher Education Commission, Islamabad Pakistan (HEC) and Pakistan Agriculture Research Council (PARC), during the period of this study.

REFERENCES

- Aksoy M, H Erdem, F Hatipoglu, NC Lehimcioglu, O Akman and K Ozkan, 2009. Ultrasonographic examination of the scrotal content in the rabbit. *Reprod Domes Anim*, 44: 156-160.
- Ahmad N, DE Noakes and AL Subandrio, 1991. B-mode real time ultrasonographic imaging of the testis and epididymis of sheep and goats. *Vet Rec*, 128: 491-496.
- Cartee RE, BW Gray, TA Powe, RS Hudson and J Whitesides, 1989. Preliminary implications of B-mode ultrasonography of the testicles of beef bulls

- with normal breeding soundness examination. *Theriogenology*, 31: 1149-1157.
- Cartee RE, TA Powe, BW Gray, RS Hudson and DL Kuhlers, 1986. Ultrasonographic evaluation of normal boar testicles. *Am J Vet Res*, 47: 2543-2548.
- Evans ACO, RA Pierson, A Garcia, LM Mcdougall, F Hrudka and NC Rawlings, 1996. Changes in circulating hormone concentrations, testes histology and testes ultrasonography during sexual maturation in beef bulls. *Theriogenology*, 46: 345-357.
- Friedlander M, A Rosenstrauch and E Bedrak, 1984. Leydig cell differentiation during the reproductive cycle of the seasonal breeder *Camelus dromedarius*: An ultrastructural analysis. *Gen Comp Endocrinol*, 55: 1-11.
- Gouletsou PG, GS Amiridis, PJ Cripps, T Lainas, K Deligiannis, P Saratsis and GC Fthenakis, 2003. Ultrasonographic appearance of clinically healthy testicles and epididymides of rams. *Theriogenology*, 59: 1959-1972.
- Lavoipierre AM, 2000. Ultrasound of the prostate and testicles. *World J Surg*, 24: 198-207.
- Masood A, 2007. Studies on the morphology of male reproductive system of one-humped camel (*Camelus dromedarius*) kept under natural ecology of Pakistan. M Sc (Hons) Thesis, University of Agriculture, Faisalabad (Pakistan).
- Pierson RA and OJ Ginther, 1988. Ultrasonic imaging of the ovaries and uterus in cattle. *Theriogenology*, 29: 521-522.
- Pechman RD and BE Eilts, 1987. B-mode ultrasonography of the bull testicles. *Theriogenology*, 27: 431-440.
- Skidmore JA and GP Adams, 2000. Anatomy of the Camel Reproductive Tract; The Camel Reproduction Centre, Dubai, United Arab Emirates.
- Singh UB and MB Bharadwaj, 1978. Histological and histochemical studies on the testis of camel (*Camelus dromedarius*) during the various seasons and ages. *Act Anat*, 101: 180-188.
- Tibary A and A Anouassi, 2000. Ultrasonography of the genital tract in camels (*Camelus dromedarius* and *Camelus bactrianus*). In: Selected Topics in Camelids, Gahlot, T. K., (ed). The Camelid Publishers, Bikaner-334001, India.
- Tingari MD, AS Ramos, ESE Gaili, BA Rahma and AH Saad, 1984. Morphology of the testis of the one-humped camel in relation to reproductive activity. *J Anat*, 139: 133-143.
- Zayed AE, A Hifny, A Abou-elmagd and KH Wrobel, 1995. Seasonal changes in the intertubular tissue of the camel testis (*Camelus dromedarius*). *Ann Anat*, 177: 199-212.