



CASE REPORT

Intra-Abdominal Actinomycetoma in a Dog Caused by *Actinomyces hordeovulneris*

S Valentini, R Tamburro*¹, M Zanatta, B Brunetti, M Gruarin, RG Zanoni, M Cipone and M Pietra

University of Bologna, School of Agriculture and Veterinary Medicine, Department of Veterinary Medical Sciences, Bologna, Italy; ¹University College Dublin, School of Veterinary Medicine, Belfield, Dublin 4, Ireland

*Corresponding author: roberto.tamburro@ucd.ie

ARTICLE HISTORY

Received: May 29, 2013

Revised: August 07, 2013

Accepted: September 15, 2013

Key words:

Actinomycetoma

Dog

Gastric wall

Mass

ABSTRACT

A 4-year-old, male French Brittany weighing 18 kg was presented for continuous disorexia associated with a large palpable mass in the cranial abdomen. Radiographic and ultrasonographic examination showed the presence of a mass close to the gastric wall. Percutaneous needle aspiration of the mass revealed pyogranulomatous inflammation. An exploratory laparotomy was performed in order to remove the mass. Actinomycotic mycetoma was revealed after surgery by positive culture. After a three months antibiotic therapy, nine months follow up showed complete remission.

©2013 PVJ. All rights reserved

To Cite This Article: Valentini S, R Tamburro, M Zanatta, B Brunetti, M Gruarin, RG Zanoni, M Cipone and M Pietra, 2014. Intra-abdominal actinomycetoma in a dog caused by *Actinomyces hordeovulneris*. Pak Vet J, 34(1): 133-136.

INTRODUCTION

Mycetoma is a chronic, slow growing pyogranulomatous tumour-like lesion caused by free-living bacteria (actinomycotic mycetoma) or fungi (eumycotic mycetoma) that can implant into the body. The etiologic agents of actinomycotic mycetomas in dogs are *Actinomyces* spp, Gram-positive filamentous bacteria (Sharman *et al.*, 2009). Mycetoma appears as a nodular inflammation characterized by fibrosis, sinuses draining from deep tissue, and the presence of grains (aggregates of pathogenic organisms) in infected tissue (Sharman *et al.*, 2009).

In the dog, the most common anatomic regions affected by actinomycosis are pleural cavity and cutaneous/subcutaneous tissue (Kirpensteijn *et al.*, 1992; Pelle *et al.*, 2000; Doyle *et al.*, 2009); less commonly bone, nervous system and abdominal cavity can be involved (Edwards *et al.*, 1988). In particular, abdominal eumycotic mycetoma has been documented in dog as a secondary complication of surgery or reproductive system diseases (Lambrechts *et al.*, 1991), while intra-abdominal actinomycotic mycetoma has rarely been described in the dog (Edwards *et al.*, 1988).

The aim of this report is to describe an uncommon case of actinomycetoma due to *Actinomyces hordeovulneris* involving the stomach wall in a dog: case history, diagnostic investigation and clinical outcome will be discussed.

History and clinical examination: A 4-year-old male French Brittany was presented with a 10 month history of asthenia, progressive weight loss and intermittent pyrexia. The dog had a history one year previously of stone gastric foreign bodies, which were removed by gastroscopy. Doxycycline has been prescribed prior to referral to treat the pyrexia. No abdominal traumatic events were reported by the owner. On physical examination, the patient was hyperthermic (rectal temperature 39.3°C). Abdominal palpation elicited slight pain and revealed a mass at the level of the cranial abdomen. The remainder of the physical examination was unremarkable.

Complete blood count revealed leukocytosis (30,680/mm³, normal range: 6000-17,000/mm³) with monocytosis (3100/mm³, normal range 100-1400/mm³) and neutrophilia (23,090/mm³, normal range 3000-12,000/mm³). Serum biochemical analysis revealed increases in CK (332 U/L, normal range 50-290 U/L), ALP (938 U/L, normal range 42-180 U/L) and AMY (1414 U/L, normal range 340-980 U/L). Serologic tests for *Babesia canis*, *Ehrlichia canis* and *Borrelia burgdorferi* were negative. The results of urinalysis on a sample collected via cystocentesis were within reference limits.

Radiographic examination revealed, in the lateral view, a mid-abdominal round soft-tissue mass protruding in the gas filled stomach and causing a caudal displacement of the small intestine (Fig. 1). No abnormalities were identified in radiographs of the dog's thorax.

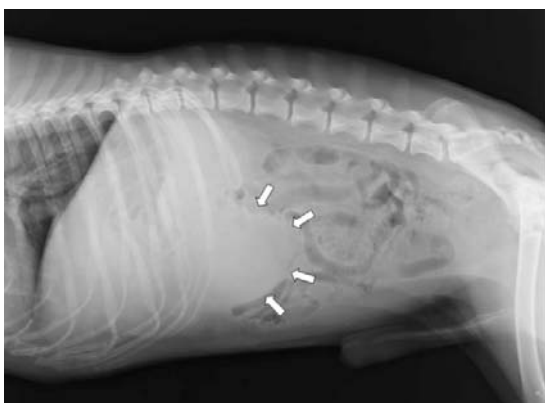


Fig. 1: Right lateral radiograph of the abdomen at admission. Presence of a mid-abdominal round soft-tissue mass caudal to the gastric shadow.

Abdominal ultrasonographic examination was performed with a 5-8 MHz microconvex probe. An ill-defined rounded mass (maximum diameter about 10 cm) with mixed echogenicity was found in the region of gastric greater curvature. The layers of the gastric wall were focally indistinct but were intact at the margin of the mass (Fig. 2). Colour Doppler examination revealed minor evidence of intra-lesional vascular flow motion. Splenic and pancreatic-duodenal lymph nodes were enlarged (15 and 9 mm respectively) and more rounded, with a heterogeneous ecotexture and hyperechoic hilus. These ultrasound features were suggestive of a gastric granulomatous lesion or a neoplasia, probably involving the stomach. A percutaneous needle aspirate of the mass revealed pyogranulomatous inflammation.

Treatment and postoperative care: Exploratory laparotomy was performed and the cranial abdominal cavity was explored. After premedication with Acepromazine 10 mg/Kg (Prequillan®, Fatro spa, Italy) and Methadone Hydrochloride 0,3 mg/Kg (Eptadone®, Molteni & C.F.lli Allitti spa, Italy), general anaesthesia was induced with Propofol 2 mg/kg *i.v.* (Rapinovet®, Intervet, Italy) and maintained with Isoflurane in oxygen. Ringer's lactate solution was administered at 5 ml/kg/h during anaesthesia. The patient was monitored with an electrocardiogram, spirometer, pulse oximeter, capnograph and noninvasive pressure. Lymphadenopathy was confirmed on abdominal exploration: intraoperative fine needle aspiration substantiated the piogranulomatous process. A large mass (about 15 x 10 cm) was found to be firmly attached to the greater curvature of the stomach and tightly adhered to the mesenteric surface of the spleen (Fig. 3). Wedge biopsy of the mass was taken for immediate impression smear cytology to rule out lymphoma or other neoplasia and confirmed pyogranulomatous inflammation. The spleen was not involved, but had to be removed to expose the lesion; a partial gastrectomy of the greater curvature of the stomach was performed in order to remove the mass. A second mass (3 x 4 cm) was attached to the lesser curvature of the stomach and was also removed. At the end of the surgery, an endoscopic examination was performed to rule out mucosal lesions of the oesophagus or gastric mucosa that could not be directly observed during the partial

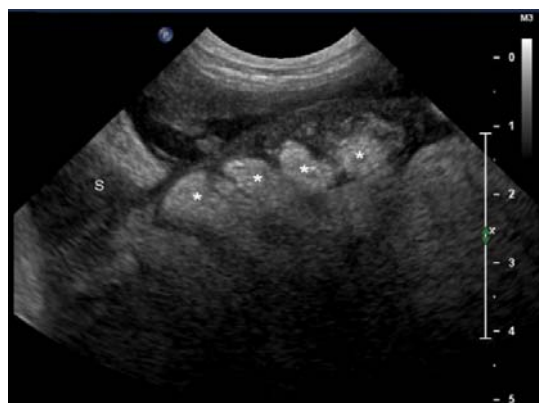


Fig. 2: Ultrasound abdominal examination at admission. Sonogram shows a 10-cm-thick mass extending immediately caudal to the stomach wall (S). The mass had a feature of a mixed echogenicity with a few hyperechoic structures inside (*).

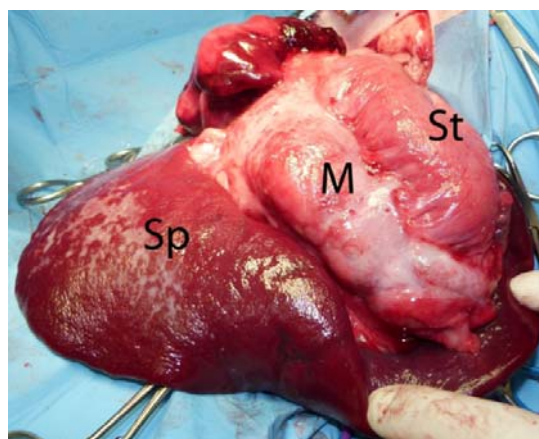


Fig. 3: Intrasurgical findings: a large mass (acnomycetoma) (M) between the greater gastric curvature (St) and the spleen (Sp) was observed.

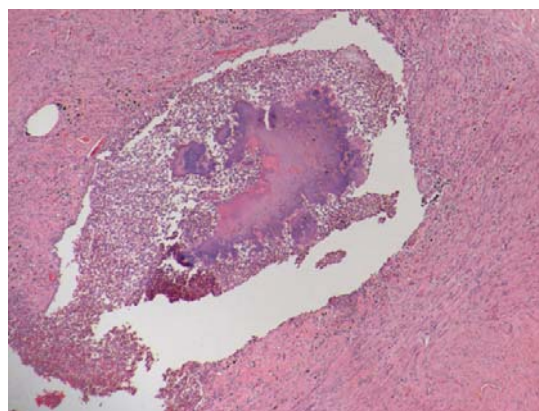


Fig. 4: Pyogranulomatous inflammation centred on a large basophilic bacterial colony. E-E, 4x.

gastrectomy. Gastric mucosal lesions were not present. The removed tissues were submitted for histological and bacteriological examination. The patient recovered from surgery without complications and was discharged three days after surgery. Postoperative care included antibiotic (Amoxicillin-Clavulanic Acid 20 mg/kg PO bid for 10 days) and analgesic therapy (Meloxicam 0.1 mg/kg/day PO for 7 days).

Diagnosis and treatment adopted: Histological sections of both masses removed were stained with hematoxylin and eosin and with the Gram method. Multiple microscopic coalescing pyogranulomas were present. They were centred on radiating basophilic colonies, up to 500 microns in diameter, composed of myriads of filamentous bacteria. Bacterial aggregates were surrounded by numerous degenerated neutrophils, lymphocytes and plasma cells, fewer epithelioid macrophages and Langhans-type multinucleated giant cells with up to 5 nuclei. The external layer of the lesions was composed of dense fibrous connective tissue with plump fibroblasts and macrophages containing abundant hemosiderin (Fig. 4). The bacteria were Gram-positive. After 72 hours of incubation in a capnophilic atmosphere, white colonies had grown in pure culture on blood agar. The colonies had a molar tooth-like appearance and after seven days of incubation showed slight haemolysis. The isolate was identified as *Actinomyces hordeovulneris* by chemical tests and by 16 S rRNA gene sequence. The isolate was susceptible to penicillin, amoxicillin+clavulanic acid, cefadroxil, clindamycin, erythromycin, tetracycline and doxycycline: administration of amoxicillin-clavulanic acid (20 mg/kg PO bid) was therefore continued for three months. Two months after surgery, clinical follow up and radiological examination showed no abnormalities; ultrasonography identified a 0.7 cm thick heterogeneous structure with blurred margins connected with the greater curvature of the stomach, probably due to the scar reaction. Clinical follow up, radiographic and ultrasound examination after nine months (six months after antimicrobial therapy discontinuation) excluded any recurrence.

DISCUSSION

Actinomycetomas are reported in human beings but abdominal pyogranulomatous lesions are rarely described in cat (Kawamura *et al.*, 2005; Sharman *et al.*, 2009) and are even rarer in the dog (Edwards *et al.*, 1988). *Actinomyces* penetration within the body depends on disruption of cutaneous and mucous barriers by disease or trauma caused, for example, by bite wounds or penetrating foreign bodies (Sharman *et al.*, 2009). Bacteria can induce a granulomatous reaction characterized by nodular swelling with secondary fibrosis and aggregates of pathogenic microorganisms in infected tissues (Sharman *et al.*, 2009). The result of this process is the onset of an actinomycetoma, a granulomatous tumour-like lesion unresponsive to routine antimicrobial therapy.

If the disease involves the peritoneal cavity, the most common symptoms include progressive weight loss and hyperthermia: one or more abdominal masses could be palpated, eventually accompanied by abdominal effusion (Edwards *et al.*, 1988). In our case, an abdominal mass was palpated; weight loss, in-appetence and non-responsive hyperthermia were present.

A foreign body was not identified in the current case and the precise mechanism of the development of the abdominal lesions is still to be determined, even if we hypothesize that foreign bodies (stones) or endoscopic forceps could have caused a gastric wall trauma representing access to the pathogens. Differential

diagnosis should include neoplasia and non-mycotic granulomatous lesions, such as foreign body granulomatous lesion.

Diagnosis of abdominal mycetoma is not easy and differential diagnosis need to be included (Sharman *et al.*, 2008): determination of the lesion is usually difficult prior to surgery as the few available diagnostic tests are not without limitations and often do not provide clear information. Laparoscopic ultrasound could be useful as a miniminvasive technique to take samples for histological examination and culture (Spinella *et al.*, 2006), but in this case the owner refused for economic reasons.

Ultrasonographic and radiologic examination is usually sufficient to indicate the presence of a mass, identify the original organ and take tissue samples. Ultrasonographic imaging of mycetoma in humans has been described: eumycetoma and actinomycetoma show varying degrees of bright hyper-reflective echoes that should permit them to be distinguished from other tumorous lesions (Fahal *et al.*, 1997). In the present case, the ultrasonographic features of the actinomycetoma were not comparable to those described in humans and therefore were not useful in comparative diagnosis. However, it must be underlined that Fahal describes human patients showing subcutaneous mycetoma swelling and not intra-abdominal lesions: we speculate that the difference between the tissues involved (subcutaneous tissue vs sero-muscular layers) could generate different reactions to the presence of the pathogens and, therefore, different ultrasonographic features. Actually, this remains a hypothesis because of the lack of literature regarding ultrasonography of mycetoma lesions in veterinary medicine.

A positive culture is required for definitive diagnosis: however, a deep surgical biopsy is always needed. Cultures may frequently be positive only for associated bacteria and isolation of *Actinomyces* spp may take up to 4 weeks (Sharman *et al.*, 2009). In our case, a definite diagnosis was obtained examining the surgically removed mycetoma, whilst all diagnostic tests carried out before surgery only confirmed the presence of a pyogranulomatous lesion. Surgery is effective as an adjunct to antimicrobial therapy, especially in symptomatic dogs with solitary large masses; sometimes repeat surgeries may be necessary (Sharman *et al.*, 2009). In this case, partial gastrectomy was performed also including normal gastric tissue to make sure the sutures were placed in healthy tissue. No complications such as dehiscence, infections or minor complications were observed.

An appropriate long-term antimicrobial therapy is always necessary. In dogs, long-term high-dose penicillin and trimethoprim-sulfonamide treatment have been most commonly administered for a period ranging from weeks to years (mean two months). However, the use of this combination is controversial because of the possibility of resistance (Sharman *et al.*, 2009). Administration of amoxicillin + clavulanic acid for 3 months was clinically efficacious in the current case, but the positive influence of surgery must be underlined.

For the few published case reports of abdominal actinomycetoma in dogs, the authors consider a 9 month follow up without any infection redevelopment satisfactory. Presenting this clinical case would be

beneficial as actinomycetoma is an uncommon condition in the dog that requires extensive diagnostic tests, a suitable surgical therapy and a proper prolonged antimicrobial therapy.

Conclusion: It is assumed that the rarity of the lesion, the diagnostic difficulties and the intra/post operatively management described in this case report could be very useful for readership involved in clinical practice.

REFERENCES

- Doyle JL, RG Kuipers Von Lande and AJ Worth, 2009. Intra-thoracic pyogranulomatous disease in four working dogs. *New Zeal Vet J*, 57: 346-351.
- Edwards DF, TG Nyland and JP Weigel, 1988. Thoracic, abdominal, and vertebral actinomycosis. Diagnosis and long-term therapy in three dogs. *J Vet Intern Med*, 2: 184-191.
- Fahal AH, HE Sheik, MMA Homeida, YE Arabi and ES Mahgoub, 1997. Ultrasonographic imaging of mycetoma. *Brit J Surg*, 84: 1120-1122.
- Kirpensteijn J and RB Fingland, 1992. Cutaneous actinomycosis and nocardiosis in dogs: 48 cases (1980-1990). *J Am Vet Med Assoc*, 6, 15: 917-920.
- Lambrechts N, MG Collett and M Henton, 1991. Black grain eumycetoma (*Madurella mycetomatis*) in the abdominal cavity of a dog. *J Med Vet Mycol*, 29: 211-214
- Kawamura N, A Shimada, T Morita, S Mukarami, R Azuma, M Fujiwara and A Fusjiwara, 2005. Intraperitoneal actinomycosis in a cat. *Vet Rec*, 157: 593-594.
- Pelle G, L Makrai, L Fodor and M Dobos-Kovacs, 2000. Actinomycosis of dogs caused by *Actinomyces hordeovulneris*. *J Comp Pathol*, 123: 72-76.
- Sharman MJ, SG Goh, RG Kuipers Von Lande and JL Hodgson, 2009. Intra abdominal actinomycetoma in a cat. *J Feline Med Surg*, 11: 701-705.
- Spinella G, S Valentini, A Spadari and M Fedrigo, 2006. Laparoscopic ultrasonography in six dogs. *Vet Radiol Ultrasoun*, 47, 3: 283-286.