



CASE REPORT

Testicular Leiomyosarcoma in an SMP30 Knockout Mouse

Jin-Kyu Park and Kyu-Shik Jeong*

Department of Veterinary Pathology, College of Veterinary Medicine, Kyungpook National University, Daegu, 702-701, Republic of Korea

*Corresponding author: jeongks@knu.ac.kr

ARTICLE HISTORY (16-207)

Received: August 07, 2016
Revised: December 16, 2016
Accepted: December 28, 2016
Published online: January 16, 2017

Key words:

Mouse
SMP30
Testicular leiomyosarcoma
Vimentin
 α -SMA

ABSTRACT

Reports of testicular leiomyosarcoma are extremely rare in the veterinary literature. Here we report a case of testicular leiomyosarcoma occurring in a 32-weeks-old male senescence marker protein 30 (SMP30) knockout mouse. Grossly, a testicular mass completely replaced the right testis. The mass had a diameter of 1.6×0.9cm, and was well-encapsulated and firm. The cut surface showed heterogeneous white and yellow-brownish components with multifocal hemorrhages. Microscopically, the mass was composed of interlacing bundles of neoplastic cells characterized by a spindle-shaped appearance with elongated blunt-end nuclei and frequently observed mitotic figures. Immunohistochemically, the neoplastic cells showed strong positivity for vimentin and α -smooth muscle actin. Finally, present case was diagnosed as testicular leiomyosarcoma in an SMP30 knockout mouse.

©2017 PVJ. All rights reserved

To Cite This Article: Park JK and KS Jeong, 2017. Testicular leiomyosarcoma in an SMP30 knockout mouse. Pak Vet J, 37(2): 239-241.

INTRODUCTION

Leiomyosarcoma is one of the common tumors originating from smooth muscle cells, and comprises approximately 10-15% of all soft tissue malignancies in humans (Park *et al.*, 2010), but is rarely reported in the veterinary field, where it accounts for 7% of all soft tissue sarcomas (Nakamura *et al.*, 2010). To date, leiomyosarcoma has been reported to occur mainly in the female genital tract and gastrointestinal tracts (Nakamura *et al.*, 2010). Leiomyosarcomas in other organs are thought to be relatively rare in the veterinary field, although a few cases have been reported in the subcutaneous (Park *et al.*, 2010), cutaneous (Liu and Mikaelian, 2003), cardiac (Vogler *et al.*, 2012), bovine rumen (Benavides *et al.*, 2016), and kidney (Evans and Fowlkes, 2016).

Primary testicular tumors are quite common in domestic animals, especially in dogs. According to the World Health Organization classification for tumors in domestic animals, the most common testicular tumors are Sertoli cell tumors, interstitial cell tumors of sex-cord-interstitial origin, and seminomas arising from germ cells (Kennedy *et al.*, 1998). Thus, other types of testicular tumor, such as sarcoma and carcinoma of the testis, are considered to be extremely rare. To date, only three cases of testicular leiomyosarcoma have been reported in the veterinary literature (Kammeyer *et al.*, 2014).

Senescence marker protein 30 (SMP30) is a marker of aging, and its expression has been shown to decrease with aging in mice. SMP30 has gluconolactonase activity, which is associated with vitamin C biosynthesis in animals, except for primates and guinea pigs. SMP30 knockout mouse undergoes accelerated aging and has a short lifespan because of heightened oxidative stress induced by vitamin C deficiency (Kondo *et al.*, 2006). Here, we report a rare case of testicular leiomyosarcoma in an SMP30 knockout mouse.

MATERIALS AND METHODS

Gene targeted SMP30 knockout mice (C57BL/6 background) were obtained from the Tokyo Metropolitan Institute of Gerontology (Tokyo, Japan) and kept in a controlled environment (22±3°C; 50±10% relative humidity on a 12-hr light-dark cycle). The mice had access to food and filtered tap water ad libitum. For SMP30 genotyping, PCR were performed using genomic DNA isolated from the mouse tail and primers TA4 (5'-CAAGTAACTCTAGGTATGGAC-3'), TS3 (5'-CTAGCCATGGTGGATGAAGAT-3') and NEO (5'-TCGTGCTTTACGGTATCGCCGCTCCCGATT-3') to detect the normal SMP30 allele. A firm mass was noted in the right inguinal region of one 32-weeks-old male SMP30 knockout mouse. The mass showed very rapid growth in the subsequent 4 weeks, and the mouse

developed symptoms of anorexia, weight loss, and depression. Finally, the mouse was euthanized due to the rapidly growing inguinal mass, and a necropsy was performed. All organs including the testicular mass were removed for histological examination and they were fixed immediately in 10% neutral buffered formalin for 2 days, processed routinely, and embedded in paraffin wax. Tissue blocks were cut at a thickness of 4 μ m, and the sections were stained with hematoxylin and eosin. Immunohistochemistry was performed to identify the origin of the neoplastic cells using the avidin-biotin-peroxidase complex method (Vectastatin ABC kit; Vector Laboratories Inc., Burlingame, CA, USA) with 3,3'-diaminobenzidine (Zymed Laboratories Inc., San Francisco, CA, USA) for visualization of a positive reaction. For immunohistochemistry, an anti- α -smooth muscle actin (α -SMA) antibody (Sigma-Aldrich, St Louis, MO, USA), anti-vimentin (Dako Cytomation, Denmark), anti-desmin (Dako North America, Inc., Carpinteria, CA, USA), cytokeratin 8 (Novocastra Laboratories Ltd, UK), cytokeratin 18 (Novocastra Laboratories Ltd, UK), anti-myogenin (Santa Cruz Biotechnology, Santa Cruz, CA,

USA), anti-myoglobin (Santa Cruz Biotechnology, Santa Cruz, CA, USA) and anti-S100 antibodies (Santa Cruz Biotechnology, Santa Cruz, CA, USA) were used. Positive and negative controls were used for each immunohistochemistry test.

RESULTS AND DISCUSSION

Gross findings were unremarkable in all organs except for the right testis occupied by the mass, suggesting no tumor metastasis. The right testis was severely enlarged and occupied throughout by neoplastic changes, whereas the left testis was of normal appearance and size (Fig. 1A). The excised right testicular mass was firm, had a diameter of 1.6 \times 0.9cm, and was well-encapsulated by fibrous tissue. The cut surface of the mass was heterogeneously white and yellow-brownish with multifocal hemorrhages (Fig. 1B, 1C). Genotyping by PCR analysis confirmed that the tumor in this SMP30 knockout mouse had a PCR band at 1363 bp (TS4/TS3) and 323 bp (TA4/NEO) (Fig. 1D).

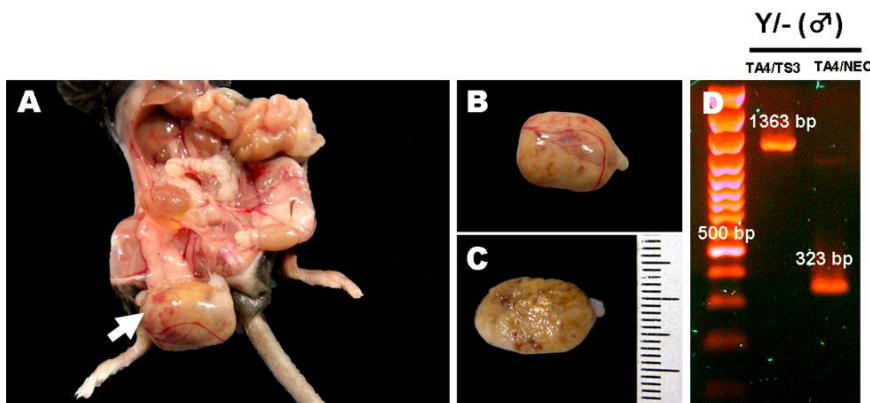


Fig. 1: Photomicrographs of a testicular mass (A, B, C) and polymerase chain reaction analysis for genotyping using isolated genomic DNA in an SMP30 knockout mouse (D). The right testicular mass has completely replaced the normal portion of the right testis, which is severely enlarged compared with the left testis (A). The excised mass has a well-demarcated and well encapsulated appearance (B). The cut surface of the mass shows a homogeneous whitish component, multifocal congestion, and hemorrhage, and had a diameter of 1.6 \times 0.9 cm (C). This SMP30 knockout mouse showed polymerase chain reaction bands at 1363 bp (TA4/TS3) and 323 bp (TA4/NEO) (D).

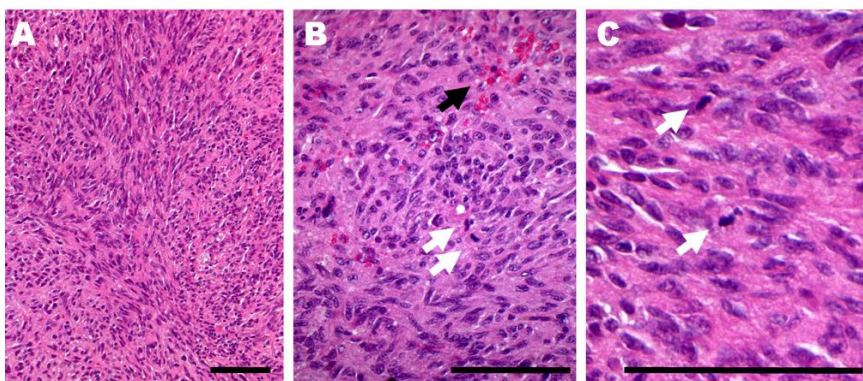


Fig. 2: Photomicrographs of histopathological features (A–C). The mass is composed of interlacing bundles of neoplastic cells with the appearance of smooth muscle cells and showing elongated blunt-end nuclei (cigar-like shaped) and abundant eosinophilic cytoplasm (A). Hemorrhages (black arrow) and mitotic figures (white arrows) of tumor cells are observed (B). Mitotic figures were observed frequently in proliferative tumor cells with poor differentiation (C). H and E stain. Bars=100 μ m.

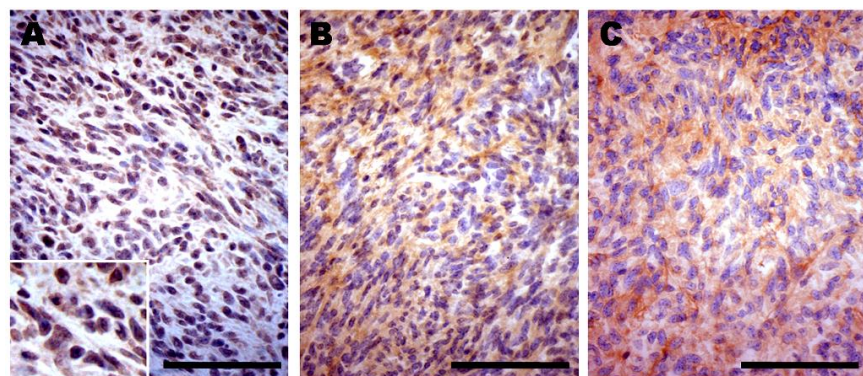


Fig. 3: Photomicrographs for identification of the origin of the tumor cells (A–C). Immunohistochemistry of the tumor mass shows a strong positive reaction for α -smooth muscle actin (A) and vimentin (B) but a weak positive reaction for desmin (C). Bars=100 μ m.

On microscopy, the right testicular mass was composed of interlacing bundles of neoplastic cells that were characterized by a spindle-shaped appearance with elongated blunt-end nuclei and abundant eosinophilic cytoplasm (Fig. 2A). Mitotic figures were also frequently observed in the proliferating tumor cells. Some poorly differentiated tumor cells showed pleomorphic changes, including hyperchromatic, irregular, and round to ovoid nuclei (Fig. 2B). Generally, 2–4 mitotic figures were observed in a field of 400× magnification (Fig. 2C). On immunohistochemistry, the tumor cells showed strong cytoplasmic positivity for α -SMA (Fig. 3A) and vimentin (Fig. 3B). The cytoplasm in the tumor cells was also weakly positive for desmin (Fig. 3C). However, the tumor cells showed negative reactions for cytokeratin 8, cytokeratin 18, myogenin and myoglobin (Data not shown).

In the present case, gross and microscopic observation and immunohistochemistry results suggested that the tumor cells originated from smooth muscle cells. However, the origin of the neoplastic smooth muscle cells could not be determined due to the disappearance of normal the structure of the right testis. Microscopically, the normal testis is surrounded by the tunica albuginea, which is a thick fibrous capsule containing prominent smooth muscle cells and lobuli composed of seminiferous tubules (Dellmann and Eurell, 1998). The present case had a well demarcated and encapsulated gross and microscopic morphology (Fig. 1; Fig. 2), suggesting that the tumor cells might have originated from smooth muscle cells inside the testis. Thus, we excluded blood vessels and the tunica albuginea as being the origin of the smooth muscle tumor cells. Importantly, the seminiferous tubules are surrounded by the tunica propria, which contains many smooth muscle cells that aid contraction of the tubules (Dellmann and Eurell, 1998). Therefore, the tumor cells in the present case might have originated from peritubular smooth muscle cells in the right testis.

For differential diagnosis, leiomyosarcoma needs to be differentiated from other malignant spindle-shaped cell tumors, including spindle cell squamous cell carcinoma, myxosarcoma, fibrosarcoma, rhabdomyosarcoma, schwannoma, and desmoplastic melanoma. Therefore, we performed immunohistochemistry for definitive diagnosis. The testicular tumor found in the present case showed strong positivity for α -SMA and vimentin, weak positivity for desmin (Fig. 3), and was negative for cytokeratin, S100, myogenin, and myoglobin, suggesting that the tumor cells originated from smooth muscle cells. Schwannoma and desmoplastic melanoma was excluded because the tumor tissue was negative for S100. Spindle cell squamous cell carcinoma was excluded because the tumor cells were negative for cytokeratin. Rhabdomyosarcoma was also ruled out because the tumor cells were negative reaction for myoglobin and myogenin. Myxosarcoma was discounted because mucinous stroma was not observed in the tumor tissue. Fibrosarcoma was ruled out because of the absence of collagenous stroma in the tumor tissue. The present case was finally diagnosed as testicular leiomyosarcoma based on gross and microscopic observation and immunohistochemistry results.

SMP30 is known to have an important role in the biosynthesis of vitamin C in mammals, with the exception of humans, primates and guinea pigs. Previous studies

have also reported that SMP30 knockout mice had scurvy, bone fractures and vascular contraction due to vitamin C deficiency (Kondo *et al.*, 2006). The pathogenesis of testicular tumorigenesis is not clearly understood, oxidative stress may be one of the most important factors affecting the tumorigenesis of testicular tumors in animals. Therefore, it is believed that vitamin C insufficiency might be associated with the development of testicular leiomyosarcoma in the present case.

Reports of testicular leiomyosarcoma are rare in human and veterinary medicine. In animals, there have been three reports of testicular leiomyosarcoma, one each in a stallion, an albino African lungfish and a ferret with cryptorchidism (Kammeyer *et al.*, 2014); however, cases of leiomyosarcoma have been reported more commonly in the uterus, liver, gastrointestinal tract, heart, subcutaneous blood vessels (Park *et al.*, 2010), bovine rumen (Benavides *et al.*, 2016), and kidney (Evans and Fowlkes, 2016). Therefore, the biological behavior of testicular leiomyosarcoma is not only poorly understood but also very difficult to predict in both animals and humans, which has led to difficulty in making recommendations for a standardized treatment strategy (Kammeyer *et al.*, 2014).

In summary, the present case describes a very rare case of testicular leiomyosarcoma that occurred spontaneously in an SMP30 knockout mouse. Further, this case suggests that leiomyosarcoma should be included in the differential diagnosis for testicular tumors in the veterinary field. To the authors' knowledge, this is the first report of a testicular leiomyosarcoma occurring in rodents.

Acknowledgements: This research was supported by Kyungpook National University Research Fund, 2015.

REFERENCES

- Benavides J, Fuertes M, Pérez V, *et al.*, 2016. Ruminal Leiomyosarcoma in an adult cow. *Berl Munch Tierarztl Wochenschr* 129:355-9.
- Dellmann HD and Eurell JA, 1998. Male Reproductive System. In: *Textbook of Veterinary Histology*, 5th Ed, Lippincott Williams & Wilkins, USA pp:230-50.
- Evans D and Fowlkes N, 2016. Renal leiomyosarcoma in a cat. *J Vet Diagn Invest* 28:315-8.
- Kammeyer P, Ziege S, Wellhöner S, *et al.*, 2014. Testicular leiomyosarcoma and marked alopecia in a cryptorchid ferret (*Mustela putorius furo*). *Tierärztliche Praxis Kleintiere* 42:406-10.
- Kennedy PC, Cullen JM, Edwards JF, *et al.*, 1998. Histological classifications of tumors of the genital system of domestic animals. In: *World Health Organization International Histological Classification of Tumors of Domestic Animals: Vol 4* (Kennedy PC, ed), Armed Forces Institute of Pathology, Washington DC, USA pp:17-8.
- Kondo Y, Inai Y, Sato Y, *et al.*, 2006. Senescence marker protein 30 functions as gluconolactonase in L-ascorbic acid biosynthesis, and its knockout mice are prone to scurvy. *Proc Natl Acad Sci USA* 103:5723-8.
- Liu SM and Mikaelian I, 2003. Cutaneous smooth muscle tumors in the dog and cat. *Vet Pathol* 40:685-92.
- Nakamura SI, Seda S and Une Y, 2010. Subcutaneous leiomyosarcoma in a common squirrel monkey (*Saimiri sciureus*). *J Vet Med Sci* 72:639-42.
- Park JK, Hong IH, Goo MJ, *et al.*, 2010. Subcutaneous leiomyosarcoma in an adrenomedullin heterozygous mouse. *Exp Toxicol Pathol* 62:221-5.
- Vogler BR, Vetsch E, Wernick MB, *et al.*, 2012. Primary Leiomyosarcoma in the Heart of a Guinea Pig. *J Comp Pathol* 147:452-4.