



## RESEARCH ARTICLE

### Alterations of Pro-Inflammatory Cytokines and Tissue Protein Expressions in Cats with Interstitial Cystitis

Walaa I. Mohamaden<sup>1,2\*</sup>, Rania Hamad<sup>3</sup> and Hoda I. Bahr<sup>4</sup>

<sup>1</sup>Department of Animal Medicine, Faculty of Veterinary Medicine, Suez Canal University, Ismailia 41522, Egypt;

<sup>2</sup>College of Grassland Science, Gansu Agricultural University, Lanzhou 730070, China; <sup>3</sup>Department of Pathology,

Faculty of Veterinary Medicine, Suez Canal University, Ismailia 41522, Egypt; <sup>4</sup>Department of Biochemistry, Faculty of Veterinary Medicine, Suez Canal University, Ismailia 41522, Egypt

\*Corresponding author: walaa\_mohamedien@vet.suez.edu.eg

#### ARTICLE HISTORY (17-421)

Received: December 20, 2017

Revised: September 24, 2018

Accepted: December 05, 2018

Published online: March 07, 2019

#### Key words:

Cytokines

E-cadherin

mast cells

Plasma-glycoprotein

FIC

#### ABSTRACT

Feline interstitial cystitis (FIC) is a chronic disease of the urinary system in cats. Our main objective is to investigate the concurrent changes in serum, urine and at the bladder tissue level in FIC affected cats which might provoke the observed clinical signs. Twelve adult cats were used in this study, six cats were suffering from signs of feline lower urinary tract dysfunction (FLUTD) and the other six were clinically healthy and served as the control group. All cats were clinically examined. Serum and urine samples were collected and tested for IL-6, IL-1  $\beta$ , TNF- $\alpha$  level while total nitric oxide (TNO) was additionally tested in urine. Bladder tissue specimens were obtained for histopathological examination and immunohistochemical expression of mast cells (MC) tryptase, vasoactive growth factor-A (VAGF-A), E-cadherin and plasma glycoprotein (P-gp). There were significant increases in the serum levels of IL-6, IL-1 $\beta$ , and TNF- $\alpha$  and in the urinary levels of IL-6, IL-1  $\beta$  of affected cats in comparison to the control healthy ones. The immunohistochemical technique revealed a marked increase in the MC tryptase and VAGF-A in the bladder tissue of FIC cats compared to the control group, while E-cadherin and p-glycoprotein were significantly decreased. We concluded that mast cells and its released mediators play an important role in the pathogenesis of the interstitial cystitis in cats.

©2018 PVJ. All rights reserved

**To Cite This Article:** Mohamaden WI, Hamad R and Bahr HI, 2019. Alterations of pro-inflammatory cytokines and tissue protein expressions in cats with interstitial cystitis. Pak Vet J, 39(2): 151-156. <http://dx.doi.org/10.29261/pakvetj/2019.026>

#### INTRODUCTION

Feline lower urinary tract diseases (FLUTD) are naturally occurring diseases of the urinary system in domestic cats that induces pain, discomfort for animal, dysuria, discolored urine due to hematuria and sometimes ends with formation of stones in the urinary tract which ultimately lead to discarding them by their owners due to the appearance of some annoying signs and changes in the cats' behavior such as urination out of the box (Buffington, 2011). Lower urinary tract (LUT) dysfunction in cats is caused by several causes; some of them are identified such as bacterial cystitis, urolithiasis, urethral plugs, trauma, and neoplasia. Meanwhile, cats were classified as having idiopathic feline LUT disease as they show signs of LUT dysfunction even though they have no obstruction and the exact causes are not fully

identified (Forrester and Towel, 2015). Because most of the signs of chronic idiopathic LUT diseases in cats are similar to those in humans with interstitial cystitis (IC), Buffington *et al.* (1996) proposed that also cats with idiopathic LUT could be referred as *feline interstitial cystitis* (FIC).

Knowledge of the pathogenesis and associated biochemical alterations is crucial for further understanding and treatment of FIC. The bladder wall lining (urothelium) forms an impermeable barrier to urinary solutes. This high resistance barrier with its high glycoproteins concentrations prevents the urinary solutes from interacting with or damaging the underlying urothelial cells (Rooney *et al.*, 2015). The urothelium serves as an effective blood-urine permeability barrier to the penetration of urine into the bladder stroma. This function is maintained by the effect of different proteins

such as E-cadherin, the cell-cell adhesion molecule, which forms tight junctions between adjacent transitional epithelial cells (Li *et al.*, 2015). Furthermore, there are other proteins such as permeability glycoprotein (P-gp) that one of its functions is an efflux pump membrane protein that transports any harmful and injurious substances from inside to outside of the cell and releases them into the lumen (Finch and Philans, 2014). Any disruption of the urothelium tight cells adhesion leads to alterations in bladder wall permeability. This increased permeability subsequently results in the escape of the urinary solutes into the bladder tissue and infiltrating the underlying stroma, leading to stimulation of inflammation, activation of vasoactive agents, mast cell invasion and increased sensitization of neural nerve endings (Rooney *et al.*, 2015). In the same vein, development of such pathological condition along with the inflammatory reaction will be reflected in the blood and urine parameters. Levels of IL-1 and IL-6 were also altered (Lv *et al.*, 2013) in the urine of animal models of interstitial cystitis plus alterations in the inorganic nitric oxide synthetase (iNOS) (Logadottir *et al.*, 2014).

Multiple studies tried to explain the pathogenesis of FIC in cats by using animal models (Logadottir *et al.*, 2014; Dogishi *et al.*, 2017) like mice and rats or even by comparing it with human interstitial cystitis (IC) (Hauser *et al.*, 2015). In fact, some of these studies revealed a part of the pathophysiology of the syndrome, yet still investigating the disease condition in naturally-occurring model of IC in cats may permit more accurate results than those obtained by acute models of inflammation/injury of the bladder in healthy animals. Our aim is to investigate the FIC pathogenesis at the bladder tissue level through analyzing the expression patterns of some inflammatory cytokines that are involved in the development of this syndrome in serum and urine. As well as the assessment of the bladder tissue condition and follow some bladder tissue proteins expression in the FIC cats and compare them with other healthy normal cats.

## MATERIALS AND METHODS

**Animals:** All protocols involving the use of animals in this study were conducted according to the ethical guidelines of the Institutional Animal Care and Use Committee, Faculty of Veterinary Medicine, Suez Canal University, Ismailia, Egypt. Twelve adult cats [Six healthy served as the control group and six cats with lower urinary tract disturbance which were diagnosed as FIC afterward] were used for this study. Cats in the control group were clinically examined to confirm that they were free of diseases particularly signs referable to the lower urinary tract according to the same diagnostic criteria as cats with FIC. All cats were housed in stainless steel cages and provided with a standard cat food and water ad libitum.

**Clinical examination and samples collection:** History was taken carefully from the owners, and all cats were examined by ultrasonography. Cats were deeply anesthetized (Ketamine 10-20 mg/kg IM) that was determined to be adequate for surgery by periodically testing for an absent withdrawal reflex to a strong pinch of

the hind paw and an absent eye blink reflex to tactile stimulation of the cornea. After that, blood, urine and bladder samples were collected from each animal in both groups. Blood was centrifuged for serum collection. Urine and serum samples were preserved at -20°C for further analysis. The bladder tissues were harvested and fixed in 10% PBS formalin solution at room temperature for histopathology and immunohistochemical assay. Finally, cats were euthanized by an overdose of sodium pentobarbital (80mg/kg IV).

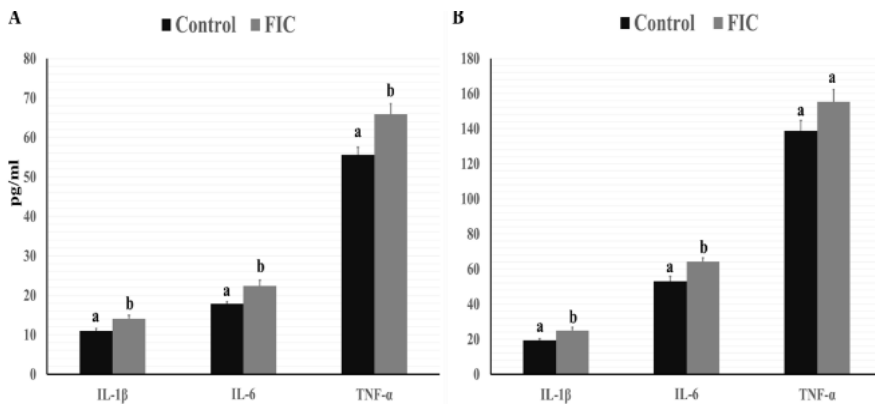
**Serum and urine analysis:** Interleukin 1 Beta (IL-1 $\beta$ ), Interleukin 6 (IL-6) & Tumor necrosis factor alpha (TNF- $\alpha$ ) were analyzed in both serum and urine using canine ELISA Kit (Wuhan Fine Biological Technology Co. China). Total nitric oxide (TNO) was measured in urine using nitrate/nitrite assay kit (Parameter, China).

**Histopathology and immunohistochemistry:** Fixed tissue samples were processed for dehydration in increasing concentrations of ethanol, two changes of xylene, and embedded in paraffin wax. Then, the paraffin blocks were sectioned serially at 4  $\mu$ m by a microtome (Model. 2235, Leica Biosystems, USA). Some sections were routinely stained with H&E while other serial tissue sections were processed for immunohistochemical detection and quantification of mast cell tryptase activity, E-cadherin, P-glycoprotein (P-gp) and vascular endothelial growth factor-A (VEGF-A) expressions. Immunoreactivity was detected using 1:100 dilution of purified mouse monoclonal anti-tryptase antibody (ab2 Colon AA1, Thermo-scientific Inc. USA), anti-E-cadherin rabbit polyclonal antibody (GTX100443, Gen Tex Inc. USA), anti-rabbit polyclonal anti-P-glycoprotein (6970-100, Bio-vision Inc. USA) and anti-rabbit polyclonal anti-VEGF (GTX102643, Gen Tex Inc. USA) at 4°C overnight, followed by incubation with peroxidase conjugated anti-rabbit IgG for 1 hr. at room temperature and reacted with DAB according to SABC kit guidelines. All stained sections were examined under a light microscope (Axio Imager.A2, ZEISS). Images were captured using Axiocam MRC5. The integrated optical density (IOD) was then measured using ImageJ software (Rueden *et al.*, 2017).

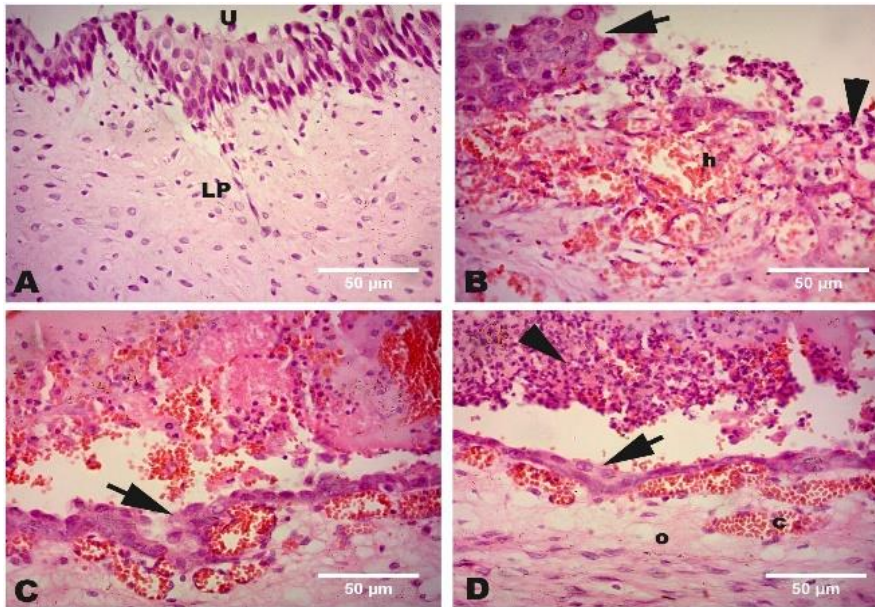
**Statistical analysis:** SPSS 22.00 software was used for all analyses. Independent t-test was performed to test the significance between Control and FIC-diagnosed cats in serum and urine biochemical parameters and immunohistochemical reactivity in the bladder tissues. The level of significance at which the null hypothesis was rejected was  $\alpha=0.05$ .

## RESULTS

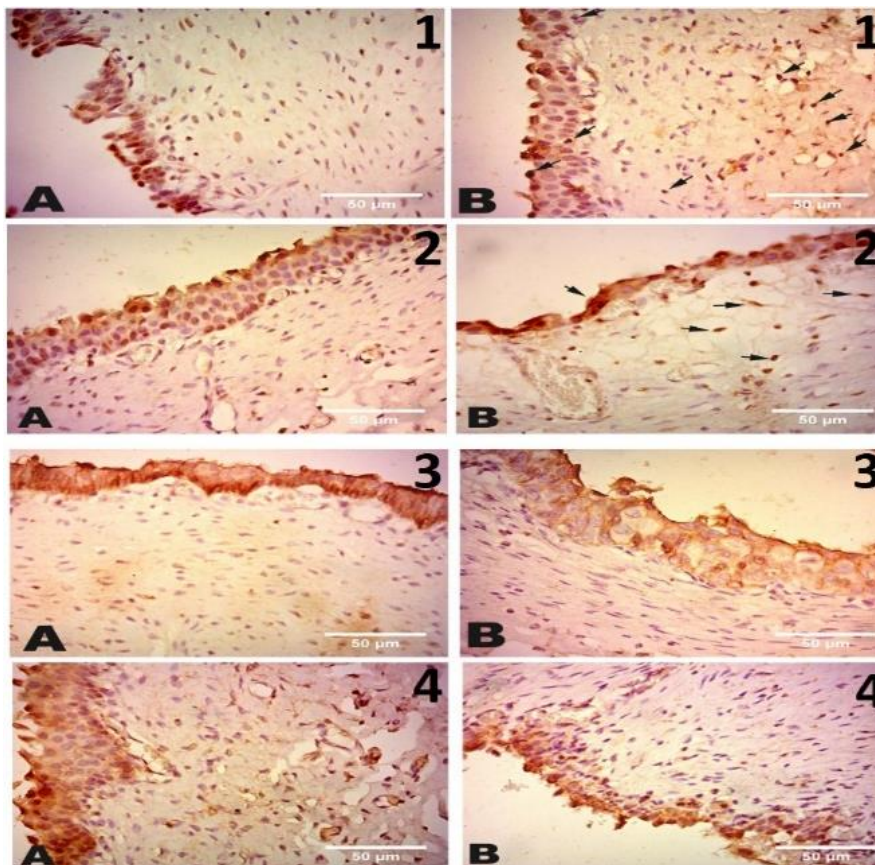
**Clinical sings:** FIC-diagnosed cats exhibited several symptoms and signs different from the control group which helped us to differentiate between the two groups. FIC cats showed history of chronic recurrent stranguria, hematuria, pollakiuria and/or urination in inappropriate locations, in addition to decrease or loss of appetite followed by loss of condition as cats were exhibiting signs of discomfort and pain. Ultra-sonographic examination showed a narrow lumen, thick, hyper-echogenic bladder wall.



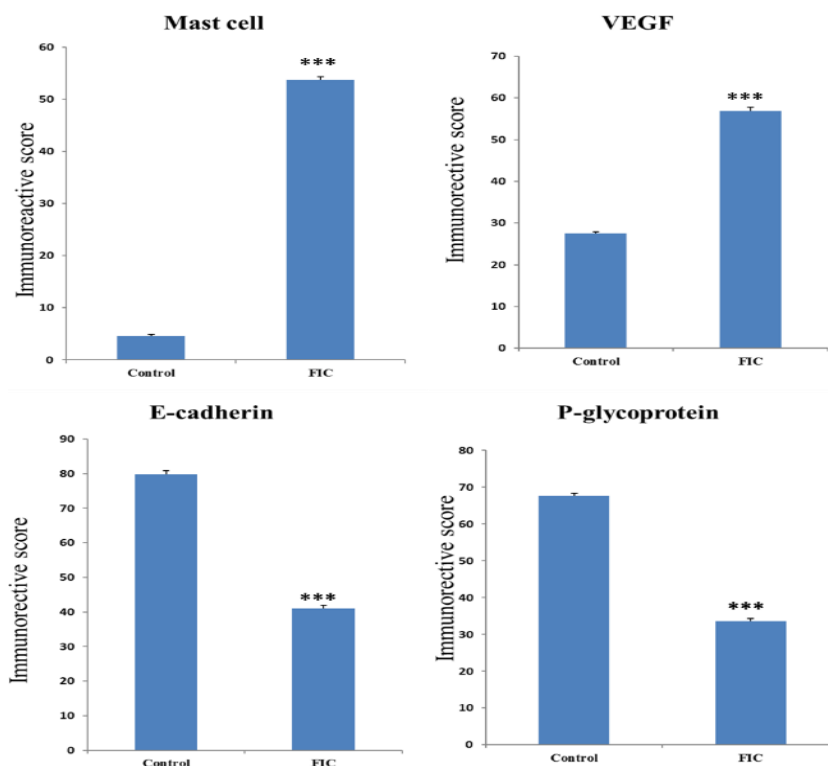
**Fig. 1:** (A) IL-1 $\beta$ , IL-6 and TNF- $\alpha$  (pg/ml) serum levels of both control and FIC cats. Means with different superscripts are significant at  $P \leq 0.05$ . (B) IL-1 $\beta$ , IL-6 and TNF- $\alpha$  (pg/ml) urine levels of both control and FC cats. Means with different superscripts are significant at  $P \leq 0.05$ .



**Fig. 2:** A Urinary bladder of control cat showed intact urothelium. B, C and D are adjacent sections of urinary bladder from interstitial cystitis (IC) cats showed denudation of the urothelium (arrow), edema (o), hemorrhage (h), congestion of blood vessels (c) in lamina propria (LP) and accumulation of serohemorrhagic exudates in lumen of urinary bladder with infiltration of lymphocytes and mast cells (Arrowhead) as demonstrated with staining by Hematoxylin and eosin (H&E).  $\times 40$ . Bar is 50 $\mu$ m.



**Fig. 3:** (1) Immunohistochemical staining of mast cell tryptase, A. bladder of control cat. B. bladder of IC cats showed an increase in mast cell numbers between urothelium and in lamina propria (arrows) as compared to normal control cats. (2) VEGF-A immunohistochemical staining showed increased VEGF expression in the urothelium and in lamina propria of IC cats (arrows) (B) as compared to normal control cats (A). (3) Immunohistochemical detection of E-cadherin A. bladder of control cats showed normal quantity on the outer surface of urothelium. B. bladder of IC cats revealed a significant decrease in E-cadherin as compared to control cats. (4) Immunohistochemical detection of P-glycoprotein. A. bladder of control cats showed normal quantity on the outer surface of urothelium. B. bladder of IC cats revealed absence or decreased levels of P-glycoprotein as compared to control cats.  $\times 40$ . Bar is 50 $\mu$ m.



**Fig. 4:** Immunoreactive score of mast cells tryptase, VEGF, E-cadherin and P-glycoprotein expression in bladder tissue of both control and FIC cats. Means with different superscripts are significant at  $P \leq 0.05$ .

**Serum and urine biochemical analysis:** Serum analysis revealed that the serum levels for IL-1 $\beta$ , IL-6 and TNF- $\alpha$  (pg/ml) were significantly higher in diseased cats than in control group ( $t=2.87$ ,  $P=0.03$  for IL-1  $\beta$ ,  $t=2.88$ ,  $P=0.03$  for IL-6 and  $t=3.23$ ,  $P=0.02$  for TNF- $\alpha$ ) as shown in Fig. 1A.

Fig. 1B showed that the urine levels of IL-1 $\beta$ , IL-6 (pg/ml) were significantly higher in diseased than control group ( $t=2.81$ ,  $P=0.02$  for IL-1 $\beta$ ) and ( $t=3.21$ ,  $P=0.01$  for IL-6). However, although both urinary TNF- $\alpha$  and TNO levels were higher in diseased cats than control group but t-test failed to disclose any significant differences between the two group in both TNF- $\alpha$  ( $t=1.80$ ,  $P=0.11$ ) as TNO levels were  $71.55 \pm 4.33 \mu\text{mol/L}$  in the FIC group and  $62.44 \pm 2.62 \mu\text{mol/L}$  in the control group ( $t=1.80$ ,  $P=0.11$ ).

**Histopathology:** Urinary bladder tissues of unaffected cats showed normal histoarchitecture while that of FIC cats showed denudation and thinning of the urothelium, urothelial spongiosis, edema, hemorrhage, congestion of blood vessels in lamina propria and accumulation of serohemorrhagic exudates in lumen of urinary bladder with infiltration of lymphocytes and inflammatory cells in the bladder interstitium (Fig. 2).

**Immunohistochemical reactivity:** Immunohistochemical labeling of mast cell showed a significant increase in mast cell number between urothelium and in lamina propria in the U.B tissue specimens of FIC cats when compared to normal control cats ( $t=75.00$ ,  $P \leq 0.001$ ). Also, VEGF-A was significantly increased in expression in the urothelium and lamina propria of FIC cats compared to normal control cats ( $t=28.20$ ,  $P \leq 0.001$ ) as shown in Fig. 3 & 4.

The E-cadherin molecules were widely distributed at the cell-cell junction in the superficial layers of the urothelium in normal control cats. The expression of E-

cadherin in affected cats' bladder tissue was significantly down-regulated, compared with that in the control. As shown in Fig. 3 & 4, the expression of E-cadherin in the control group was standardized at specific level, but those with FIC group were significantly decreased, ( $t=33.62$ ,  $P \leq 0.001$ ). Immunohistochemical expression of P-glycoprotein (P-gp) in the bladder specimens of FIC cats revealed significant decreased levels compared to a normal quantity of P- glycoprotein on the outer surface of the transitional cell apical membrane ( $t=32.93$ ,  $P \leq 0.001$ ), the so-called umbrella cell layer in the control cats (Fig. 3 & 4).

## DISCUSSION

Cats are usually admitted to clinics suffering from signs of LUTD, then after receiving complaints and information from the owners besides clinical examination and observation, they are diagnosed as feline interstitial cystitis (FIC). In the current study, affected cats exhibited signs of discomfort, stranguria, pollakiuria and loss of condition which are the most prominent signs of FIC (Forrester and Towel, 2015). As long as these signs persisted more frequently and for a considerable period of time, they are transformed into chronic pain which result from the continuous stimulation of nociceptors to induce central sensitization which means intense, repeated and sustained activity of first-order neurons that elicits changes in neuronal and biochemical processing at central synapses and descending projections, transitioning these sites into a pain-facilitatory state (Ossipov *et al.*, 2010, Grace *et al.*, 2014). In the current study, we tried to comprehend the pathogenesis of FIC and the role of specific cytokines in the appearance of some clinical signs like pain; moreover, we recorded the alteration in the

expressed proteins and the effect of these alterations on bladder tissues and body conditions.

Histopathological examination revealed thinning, ulceration of urolithium and infiltration with inflammatory cells (Leiby *et al.*, 2007). Immunohistochemical labeling of mast cells by remarking mast cell tryptase indicated a significant infiltration of MC in the bladder tissue of cats affected with FIC in comparison to normal healthy cats. These results were also previously reported in several studies on interstitial cystitis in animal models and in human (Liu *et al.*, 2012, Wang *et al.*, 2016a). Mast cells (MC) are well known as the first defender to external allergen and pathogen. In fact, the elevated number of mast cells in the bladder tissue in case of inflammation induces mast cells degranulation and release of their pre-formed mediators. In light of other reports and according to our experiment during the course of FIC, MC increasingly releases TNF- $\alpha$  in the blood which up-regulates by its role the expression of VEGF-A (Wang *et al.*, 2016b) and because of hypoxia induced by inflammation, VEGF-A was up-regulated to induce vasodilation, hyper-vascularity and glomerations at the site of inflammation (Ramakrishnan *et al.*, 2014). This explains the significant increase in the VEGF-A immunohistochemical staining which was highly distributed in urolithium and sub-urolithial layers of the affected cats. The degranulation of MC and the release of various cytokines together with the increased VEGF-A expression enhanced the leakage of these cytokines such as IL-6 and TNF- $\alpha$  which are well known to be released from MC into circulation and that clarifies the significant increase in the levels of IL-6 and TNF- $\alpha$  in the serum of cats with interstitial cystitis, that was recorded before in CYP (cyclophosphamide) model of cystitis and in IC/ (bladder pain syndrome) BPS patients (Jiang *et al.*, 2013). Also, numerous studies denoted urinary elevation of IL-6 level in ulcerative BPS/IC patients that associated with inflammation or pain and nocturia (Lv *et al.*, 2013, Lamb *et al.*, 2017). Moreover, it was reported that bladder is the main source of urinary IL-6 where it didn't present in ureteral urine (Lotz *et al.*, 1994). This means that the increased level of IL-6 is only produced by the affected bladder tissue.

Even though MCs do not secrete IL-1 $\beta$ , but mast cell-derived proteases that play a vital role in IL-1 $\beta$  activation as it helps it convert it from pro IL-1 $\beta$  to active IL-1 $\beta$  (Afonina *et al.*, 2015). IL-1 $\beta$  is a pro-inflammatory cytokine that is important for cell apoptosis, proliferation, and differentiation (Aich *et al.*, 2015). The increased levels of IL-6, IL-1 $\beta$  and TNF- $\alpha$  in serum and the increased levels of IL-6, IL-1 $\beta$  in urine, in addition to other mediators that were not measured in the current study like NGF, prostaglandins and histamine are involved in nociception (Jiang *et al.*, 2013). The released histamine and its receptors on the bladder afferent nerves as well as TNF- $\alpha$ , normal T cell and several secreted chemokines sensitize afferent nerve fibers and induce chronic pain associated with cystitis (Aich *et al.*, 2015). Recently, it was reported that the anti-hyperalgesic effects of diosmin were linked with reduced levels of TNF- $\alpha$ , IL-1 $\beta$  and IL-6; which means the theses chemokines are in somehow related to hyperalgesia (Carballo-Villalobos *et al.*, 2017).

It is important to refer that MC infiltration decreases the expression of E-cadherine, the cell-cell tight junction protein of urolithium, (Liu *et al.*, 2012; Lee *et al.*, 2013; Li *et al.*, 2015) which is consistent with the obtained results by immunohistochemical staining. The down-regulation of E-cadherin expression allows luminal content to come in contact with bladder urolithium and leakage of urine solutes into the underlying stroma. Beside the decrement in E-cadherin expression, we recorded a significantly lowered expression of P-glycoprotein in FIC affected cats. P-glycoprotein was first described as in all transitional epithelium of the bladder tissue of normal cats and it was markedly expressed on the surface cells that are in contact with the lumen (Van Der Heyden *et al.*, 2009). It is a membrane-bound energy-dependent efflux pump that exports endogenous and exogenous substrates out of the cell and serves as a biological barrier. The reduced protein expression of both E-cadherin and P-glycoprotein provides the urolithium and the underlying tissue less protection from different insults that probably come in contact with the cells. In addition to the influx of potassium ions of urine which are more concentrated, and the degranulation of mast cells altogether causing depolarization of the sensory nerves, resulting in injury to tissue and bladder pain (Ha *et al.*, 2017).

**Conclusions:** The present study examined the urine, serum and bladder tissue of cats with feline interstitial cystitis compared to healthy control cats. There was a significant increase in some pro-inflammatory cytokines of FIC cats at both serum and urine levels. At the bladder tissue level there was a significant decrease in the expression of E-cadherin and P-glycoprotein that positively modulated the uroepithelial layer permeability which aggravates the symptoms of FIC. This is the first-time molecular evidence has been presented demonstrating that mast cells have a direct effect on inflammation, and epithelial permeability in cats with FIC, but the pathogenesis of this condition still mysterious and requires further studies upon it.

**Acknowledgement:** The authors would like to thank Prof. Dr. Mohsen Zagloul, Professor of veterinary surgery and Dr. Mohamed Abd Allah, Lecturer of Veterinary Surgery, Department of Animal Surgery, Faculty of Veterinary Medicine, Suez Canal University for their support during performing the experiment.

**Authors contribution:** WIM designed the experiment and examined healthy and diseased cats. RH performed the histopathology and immunohistochemistry. HIB performed serum and urine analysis. All authors contributed to drafting and writing the manuscript.

## REFERENCES

- Afonina Inna S, Müller C, Martin Seamus J, *et al.*, 2015. Proteolytic processing of interleukin-1 family cytokines: variations on a common theme. *Immunity* 42:991-1004.
- Aich A, Afrin BL and Gupta K, 2015. Mast cell-mediated mechanisms of nociception. *Int J Mol Sci* 16:29069-92.
- Buffington CA, 2011. Idiopathic cystitis in domestic cats beyond the lower urinary tract. *J Vet Intern Med* 25:784-96.

- Buffington CAT, Chew DJ and DiBartola SP, 1996. Interstitial cystitis in cats. *Vet Clin North Am Small Anim Pract* 26:317-26.
- Carballo-Villalobos AI, Gonzalez-Trujano ME, Alvarado-Vazquez N, et al., 2017. Pro-inflammatory cytokines involvement in the hesperidin anti-hyperalgesic effects at peripheral and central levels in a neuropathic pain model. *Inflammopharmacology* 25:265-9.
- Dogishi K, Okamoto K, Majima T, et al., 2017. A rat long-lasting cystitis model induced by intravesical injection of hydrogen peroxide. *Physiol Rep* 5:e13127.
- Finch A and Pillans P, 2014. P-glycoprotein and its role in drug-drug interactions. *Aust Prescr* 37:137-94.
- Forrester SD and Towell TL, 2015. Feline Idiopathic Cystitis. *Vet Clin North Am Small Anim Pract* 45:783-806.
- Grace PM, Hutchinson MR, Maier SF, et al., 2014. Pathological pain and the neuroimmune interface. *Nat Rev Immunol* 14:217-31.
- Ha T and Xu JH, 2017. Interstitial cystitis intravesical therapy. *Transl Androl Urol* 6:S171-9.
- Hauser PJ, VanGordon SB, Seavey J, et al., 2015. Abnormalities in expression of structural, barrier and differentiation related proteins, and chondroitin sulfate in feline and human interstitial cystitis. *J Urol* 194:571-7.
- Jiang YH, Peng CH, Liu HT, et al., 2013. Increased pro-inflammatory cytokines, C-reactive protein and nerve growth factor expressions in serum of patients with interstitial cystitis/bladder pain syndrome. *PLoS One* 8:e76779.
- Lee CL, Jiang YH and Kuo HC, 2013. Increased apoptosis and suburothelial inflammation in patients with ketamine-related cystitis: a comparison with non-ulcerative interstitial cystitis and controls. *BJU Int* 112:1156-62.
- Leiby BE, Landis JR, Propert KJ, et al., 2007. Discovery of morphological subgroups that correlate with severity of symptoms in interstitial cystitis: A proposed biopsy classification system. *J Urol* 177:142-8.
- Li M, Yang K, Wang X, et al., 2015. Mast cells infiltration and decreased E-cadherin expression in ketamine-induced cystitis. *Toxicol Rep* 2:205-9.
- Liu HT, Shie JH, Chen SH, et al., 2012. Differences in mast cell infiltration, E-cadherin, and zonula occludens-1 expression between patients with overactive bladder and interstitial cystitis/bladder pain syndrome. *Urology* 80:225e13-8.
- Lotz M, Villiger P, Hugli T, et al., 1994. Interleukin-6 and Interstitial Cystitis. *J Urol* 152:869-73.
- Lv YS, Yao YS, Lin ME, et al., 2013. Interleukin-6 levels in female rats with protamine sulfate-induced chronic cystitis treated with hyaluronic acid. *International J Urol* 20:1017-22.
- Ossipov MH, Dussor GO and Porreca F, 2010. Central modulation of pain. *J Clin Invest* 120:3779-87.
- Ramakrishnan S, An V and Roy S, 2014. Vascular Endothelial growth factor signaling in hypoxia and Inflammation. *J Neuroimmune Pharmacol* 9:142-60.
- Rooney P, Srivastava A, Watson L, et al., 2015. Hyaluronic acid decreases IL-6 and IL-8 secretion and permeability in an inflammatory model of interstitial cystitis. *Acta Biomaterialia* 19:66-75.
- Rueden CT, Schindelin J, Hiner MC, et al., 2017. ImageJ2: ImageJ for the next generation of scientific image data. *BMC Bioinformatics* 18:529.
- Kim HJ, 2016. Update on the pathology and diagnosis of interstitial cystitis/bladder pain syndrome: A Review. *Int Neurourol J* 20:13-7.
- Van Der Heyden S, Chiers K and Ducatelle R, 2009. Tissue distribution of P-glycoprotein in cats. *Anat Histol Embryol* 38:455-60.
- Wang H, Han X, Wittchen ES, et al., 2016a. TNF- $\alpha$  mediates choroidal neovascularization by upregulating VEGF expression in RPE through ROS-dependent  $\beta$ -catenin activation. *Mol Vis* 22:116-28.
- Wang X, Liu W, O'Donnell M, et al., 2016b. Evidence for the role of mast cells in cystitis-associated lower urinary tract dysfunction: A multidisciplinary approach to the study of chronic pelvic pain research network animal model study. *PLoS One* 11:e0168772.