



RESEARCH ARTICLE

Trivalent Chromium Restore Dexamethasone-Induced Attenuation Effect of Insulin-Like Growth Factor-1 and Promote Skin Wound Healing in Mice

Yu-Ta Hsieh¹, Tien-Huan Hsu¹, Hsein-Chi Wang^{1,2}, Kuan-Sheng Chen^{1,2} and Wei-Ming Lee^{1,2*}

¹Department of Veterinary Medicine; ²Veterinary Medical Teaching Hospital, College of Veterinary Medicine, National Chung Hsing University, Taichung, Taiwan, R.O.C. 145, Xingda Rd., Taichung city, Taiwan, R.O.C.

*Corresponding author: wmlee@dragon.nchu.edu.tw

ARTICLE HISTORY (18-286)

Received: August 04, 2018
Revised: February 14, 2019
Accepted: February 15, 2019
Published online: March 22, 2019

Key words:

Dexamethasone
Healing
Insulin-like growth factor-1
Mice
Trivalent chromium
Wound

ABSTRACT

This study was conducted to investigate the effects of Cr³⁺ on wound healing in mice. A total of 96 male C57BL/6/J mice were randomly assigned to four groups (n=24/group). These mice were divided 4 groups and treated by normal saline, chromium chloride (CrCl₃), dexamethasone (Dex) as well as combination of CrCl₃ and Dex, respectively. Six mice of each group were sacrificed on day 7, 14, and 21 after skin incision. Skin wound area were measured and collected for histology evaluation, tissue of organs was collected for Cr³⁺ concentration determination as well as blood collected for serum IGF-I concentrations determination. Delayed healing was found in Dex group, and an accelerated healing was observed in both Cr groups. In histology, the delayed inflammation process, reepithelization, granulation tissue formation as well as collagen deposition were observed in Dex groups. However, reversed detrimental effects of Dex were observed in Cr groups. The concentrations of IGF-1 in Dex groups revealed significant decrement compared to other groups, but Cr³⁺ reversed this effect. Therefore, Cr³⁺ accelerated wound healing in surgical wound model of mice through the regulation of hormone concentrations such as IGF-1, meanwhile, the effects could be more prominent when animal is under stress or treated by exogenous glucocorticoids.

©2019 PVJ. All rights reserved

To Cite This Article: Hsieh YT, Hsu TH, Wang HC, Chen KS and Lee WM, 2019. Trivalent chromium restore dexamethasone-induced attenuation effect of insulin-like growth factor-1 and promote skin wound healing in mice. Pak Vet J, 39(2): 199-204. <http://dx.doi.org/10.29261/pakvetj/2019.042>

INTRODUCTION

Wound healing is a complex but dynamic, well-orchestrated biological event. The process is composed of three phases: inflammation, proliferation, and tissue remodeling. The inflammatory phase is initiated immediately upon injury and lasts up to 4-6 days after wounding. During this phase, neutrophils and macrophages appear in the wounded area to fight bacteria and remove debris. The proliferative phase lasts from about day 4 to day 14 after wounding and is characterized by the formation of granulation tissue. In this phase, fibroblasts produce collagen matrix while new blood vessels invade the forming granulation tissue, and epidermal cells migrate across the wound surface to close the breach. The remodeling phase starts at around day 8 and may last up to months or even longer. There is continuous synthesis and breakdown of collagen as the extracellular matrix is constantly remodeled to effect connective tissue compaction and wound contraction

(Broughton *et al.*, 2006). Glucocorticoids are effective anti-inflammatory (Sato *et al.*, 2017), immunosuppressive (Amann *et al.*, 2017) and anti-proliferation (Lee *et al.*, 2016) agents. Meanwhile, glucocorticoids are powerful agents to inhibit skin wound healing (de Almeida *et al.*, 2015; Jozic *et al.*, 2017; Slominski *et al.*, 2017) by suppression inflammation that is required for wound healing process (Kato *et al.*, 2017; Yan *et al.*, 2017). Therefore, the wound healing may be improved when the effect of glucocorticoids is blockade (de Almeida *et al.*, 2015). In fact, we have documented Cr³⁺ has an inhibitory effect on the corticosterone secretion by adrenal gland in ACTH-stimulated rats (King *et al.*, 2016). In addition, Insulin-like growth factor-I (IGF-I) can be helpful on wound healing (Cieszkowski *et al.*, 2017) which associated with proliferation, differentiation as well as wound healing process (Reckenbeil *et al.*, 2017). Likewise, IGF-1 can be suppressed by glucocorticoids (Wolthers *et al.*, 2017). Chromium (Cr) is an essential trace element and nutrient for humans and animals, it

functions as a cofactor for insulin when in the trivalent oxidation state (Cr^{3+}). Therefore, Cr^{3+} enhances the functions of insulin in cell metabolism and enhances the ability of insulin to regulate glucose, protein, and fat metabolism (Vincent, 2004). Hence, Cr^{3+} has long been studied as a useful blood glucose control (Chen *et al.*, 2014), attenuation of corticosterone action (Hrynyk and Neufeld, 2014) and regulates body composition as food supplement in livestock (Evock-Clover *et al.*, 1993). Meanwhile, Cr^{3+} has been documented that it could increase protein deposition by stimulating protein anabolism and lowering protein degradation (Peng *et al.*, 2010). However, Cr^{3+} is reduced by the treatment of prednisolone has been reported (Chen *et al.*, 2013). Therefore, the aim of this study is to investigate the effects of chromium chloride (CrCl_3) on skin wound repair in mice following surgical incision and using dexamethasone-treated mice as contrast. We hypothesized that dietary dose of Cr^{3+} can improve the skin wound healing and restore the dexamethasone-induced attenuated effect of IGF-I that can improve skin wound healing.

MATERIALS AND METHODS

Animals and study design: C57BL/6J (n=96) mice were got from National Laboratory Animal Center, Taipei, Taiwan. Eight-weeks-old male C57BL/6J mice (n=96) weighing 20-27 g were randomly divided into four groups of six animals. 24 mice were fed normal saline 0.3 ml as control group (C), 24 mice was fed CrCl_3 (80 $\mu\text{g}/\text{kg}$ BW/day, Maxluck Biotechnology, Taipei, Taiwan) in 0.3 ml solution as chromium group (Cr), 24 mice were fed dexamethasone (0.1 mg/kg BW/day, China Chemical & Pharmaceutical Co., Ltd., Taipei, ROC) in 0.3 ml solution as dexamethasone group (Dex), 24 mice were fed CrCl_3 (80 $\mu\text{g}/\text{kg}$ BW/day) and dexamethasone (0.1 mg/kg BW/day) in 0.3 ml solution as mixed group (Mix). These mice were group housed in 29.0×18.5×12.0 cm polycarbonate cages under constant temperature (23±2°C) and a 12/12 h light/dark cycle (dark phase: 20:00-08:00 h). Food and water were available *ad libitum*. This study was fully compliant with Institutional Animal Care and Use Committee (IACUC) on the care and use of laboratory animals and codes of practice.

Wound model and wounding procedure: A 3 cm long incision was made on the middle line of back of these mice which was anesthetized by Zoletil® (50 mg/kg, intraperitoneal injection). The wound area was then exposed and the animals were housed separately. The degree of wound healing was checked at Day 7, 14 and 21 after incision wound made.

Blood and tissue sample collection: Six animals of each group were sacrificed at Day 7, 14 and 21 after incision performance. Wound strips consisting of the wounded area plus 5 mm of the surrounding unwounded and/or healed skin area were collected. The blood samples were collected directly from heart. All blood samples were clot for 2 hours at 4°C refrigerator before centrifuging for 20 minutes at 2000 x g. The serum was collected and stored at -70°C refrigerator. Liver, fat, and gastrocnemius muscle tissue were taken from each carcass and stored at -70°C refrigerator for chromium determination.

Measurement of wound area: The wound area was measured by ruler for determination of length and width at Day 7, 14, and 21 after incision wound made, respectively. The area of the wound was calculated as the shape of the diamond ($1/2 \times \text{length} \times \text{width}$). Wound closure at each time point was expressed as percentage.

Semi-quantitative analysis by histological sections: The skin samples were preserved in 10% buffered formalin. Paraffin sections, 5 μm thick, were stained by hematoxylin and eosin (H&E). Semi-quantitative scales were evaluated by the structures of reepithelization, PMNL (polymorphonuclear leucocytes), fibroblasts, new vessels, and new collagen (Gal *et al.*, 2008).

Determination of tissue chromium concentrations: Liver, fat, and muscle were collected and digested by adding 65% nitric acid and heated at 65°C for 1 h. After digestion, the concentration of chromium of each sample was analyzed by graphite furnace atomic absorption spectrophotometry (Hitachi Z-2000 series polarized Zeeman atomic absorption spectrophotometer, JPN).

Determination of serum IGF-1 concentrations: All mouse serum samples were collected. Serum was processed for ELISA of IGF-1 on 96 well plate (R&D Systems, Minneapolis, MN, USA) according to the manufacturer's protocol. Serum IGF-1 levels were reported in ng/ml. Mouse serum samples were diluted 500-fold into Calibrator diluents RDS-38 before analysis.

Statistical analysis: The data was indicated by mean ± standard error mean (S.E.M.). Wound area measurement, tissue Cr concentrations, Serum IGF-1 levels were analyzed by Student t-test. P<0.05 was considered significantly difference. The data obtained from the semiquantitative evaluation were compared using the nonparametric Kruskal-Wallis test. Significant difference was accepted when P was less than 0.05.

RESULTS

The wound closure observed at Day 7, 14 and 21, respectively was shown in Fig. 1. At Day 7, the average healed wound area were 73.9, 77.9, 63.7, and 71.5 % compared to the original wound size in control, Cr, Dex and Mix groups, respectively. The results indicated that the wound healing in Dex group significantly delayed compared to control group and Cr group. At Day 14, the average healed wound area were 97.8, 99.1, 94.2, and 98.1 % compared to original wound size in control, Cr, Dex and Mix groups, respectively. A significant delay of healing of Dex group still existed in comparison to Cr group. At Day 21, the average wound healed areas were 100% in each group (Fig. 2). The keratinization of the epithelium was observed between the scab and epidermis. The dermis near excision was rich on inflammatory cells (PMNL), and the granulation tissue formed beneath the epidermis was observed at Day 7, 14 and 21, respectively (Fig. 3). Meanwhile, collagen fibers stained by Masson Trichrome was observed at Day 7, 14, and 21, respectively (Fig. 4). At Day 21, the wound healing was undergoing remodeling phase. The thickness of epidermis

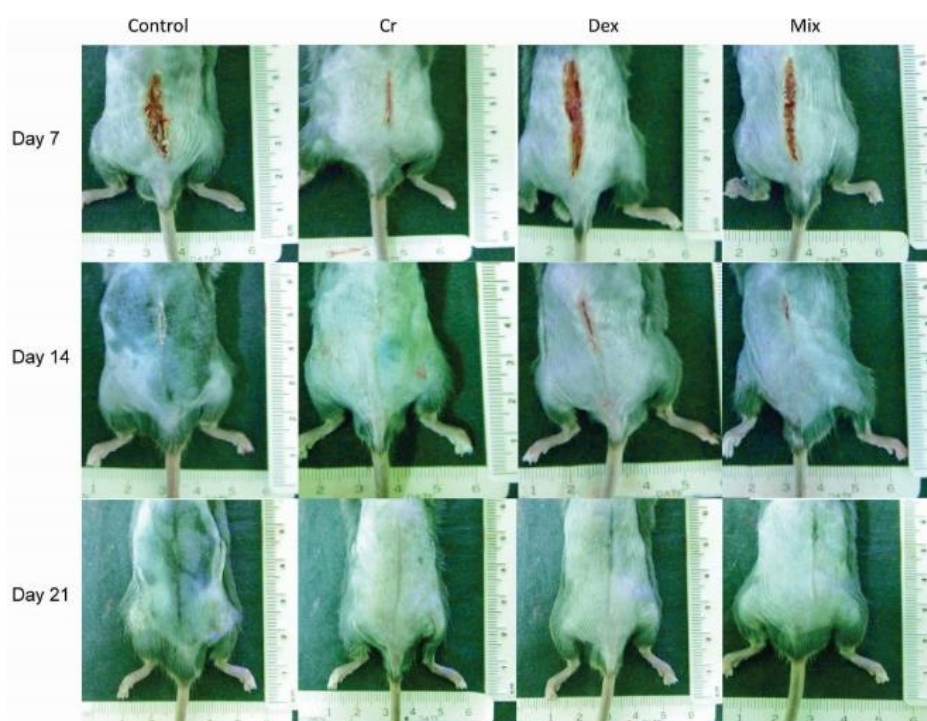

Fig. 1: The process of wound healing in each groups at Day 7 (top row), 14 (middle row) and 21 (bottom row) after surgical incision made.

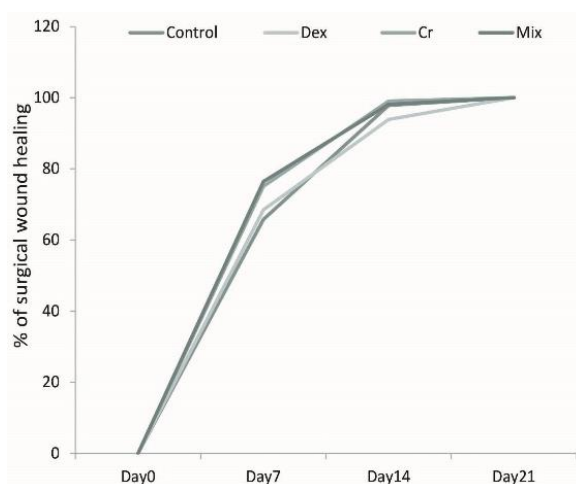


Fig. 2: The percentage of recovered wound area during 21 days in each group at Day 7, 14 and 21 after incision wound made, respectively.

was similar to intact epidermis. The organization of collagen into newly formed fibrils was observed. Furthermore, inflammatory phase, wound reepithelization, angiogenesis, fibroblast proliferation and collagen deposition were observed for semi-quantitative assessment Day 7, 14 and 21 after wound incision made, respectively (Fig. 5). Chromium concentrations of muscle, liver and fat in different groups were shown in Fig. 6. The Cr^{3+} concentrations of tissue in Dex groups showed decrement at Day 7 and Day 14 compared to control group. In Mix group, the mean Cr^{3+} concentrations were higher than that in Dex groups but lower than that in Cr group at each time points. The mean concentrations of IGF-1 at Day 7 after incision in control, Cr, Dex, and Mix groups were 351.8 ± 46.7 , 311.6 ± 31.0 , 250.3 ± 52.2 and 258.1 ± 35.0 ng/ml, respectively. The systemic levels of IGF-1 in both of Dex and Mix groups were significantly lower than that in control and Cr groups. At Day 14, the mean levels of IGF-1 in control, Cr, Dex and Mix groups were 315.9 ± 60.3 , 308.5 ± 71.7 , 221.6 ± 40.0 and 322.0 ± 34.6

ng/ml, respectively. The mean concentrations of IGF-1 in Dex group were significantly ($P < 0.05$) lower than that in control and Cr groups. At Day 21 after incision, mean concentrations of IGF-1 in control, Cr, Dex and Mix groups were 369.7 ± 68.1 , 315.9 ± 77.4 , 320.0 ± 50.1 and 346.0 ± 52.0 ng/ml, respectively (Fig. 7).

DISCUSSION

Based on the results of this study, it indicated that the effect of DEXs delay the wound healing but Cr^{3+} can improve the wound healing in the Mix group. Actually, glucocorticoids have been considered as powerful agents to inhibit skin wound healing (de Almeida *et al.*, 2015; Jozic *et al.*, 2017) by suppression of inflammation that is required for the wound healing process (Kato *et al.*, 2017). Meanwhile, glucocorticoids decreased the concentration of Cr^{3+} in the insulin sensitive tissue (Chen *et al.*, 2013). In addition, increased Cr^{3+} levels in bone but decreased them in the fat and liver after glucagon challenge and contrast finding after insulin challenge (Lin *et al.*, 2013). Thus, the inhibition of glucocorticoid secretion by Cr^{3+} (King *et al.*, 2016) and higher levels of Cr^{3+} found in fat and muscle after insulin treatment that may be benefited on the wound healing. In fact, insulin may play a role to improve wound recovery (Hrynyk and Neufeld, 2014) which may be associated with the effect of IGF-1 (Zhou *et al.*, 2018).

The IGF-1 levels are significantly decreased in dexamethason-treated mice at Day 7. This result was in accordance with the report that dexamethason decreased serum and liver IGF-1 and maintained liver IGF-1 mRNA in parenterally fed rats (Wolthers *et al.*, 2017). IGF-1 has been considered as a major regulator of growth and development as well as wound healing and has direct actions on fibroblasts, endothelial and epithelial cells (Wicke *et al.*, 2000). This result also suggested that under conditions of adequate nutrition, dexamethason down-regulates the hepatic IGF-1 endocrine axis and is

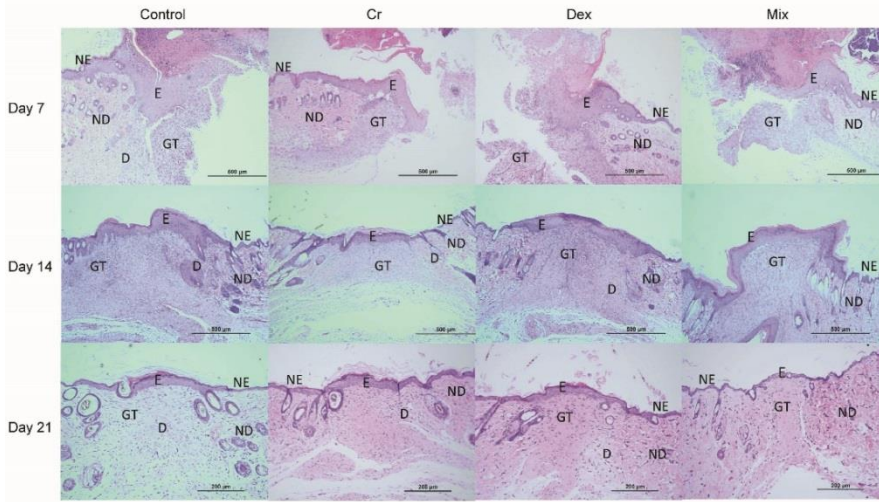


Fig. 3: Histological evaluation of wound healing in each group at Day 7 (top row), 14 (middle row) and 21 (bottom row) after incision wound made, respectively. (H&E stain, 100 X magnifications) E, epidermis; D, dermis; GT, granulation tissue; ND, normal dermis; NE, normal epidermis.

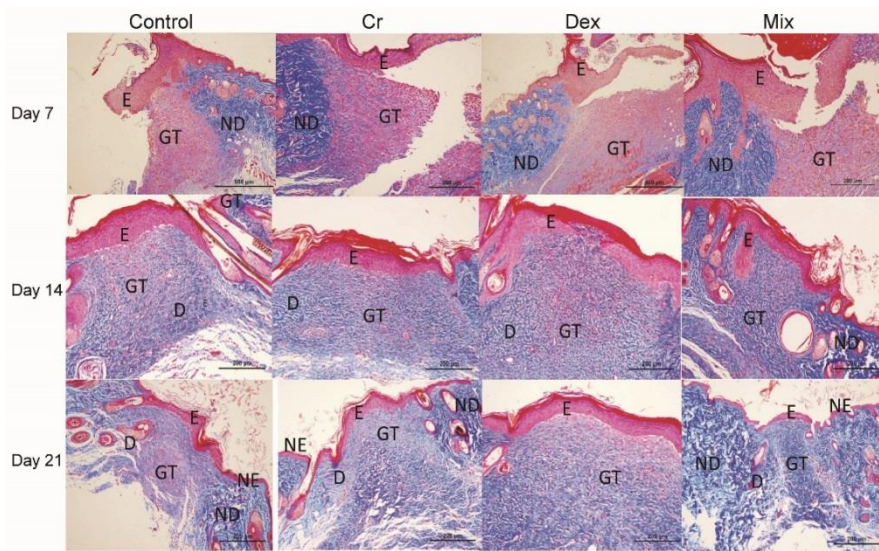


Fig. 4: Collagen deposition at the wound gap stained by Masson Trichrome in each groups at Day 7 (top row), 14 (middle row) and 21 (bottom row) after incision wound made, respectively. (200X magnification) E, epidermis; D, dermis; GT, granulation tissue; ND, normal dermis; NE, normal epidermis.

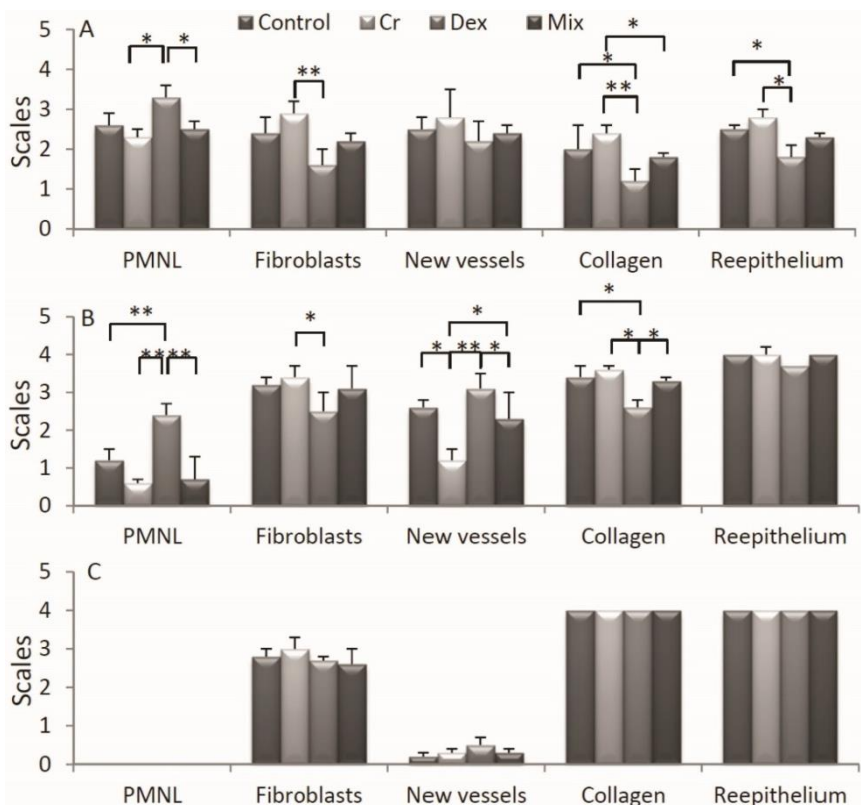


Fig. 5: Semi-quantitative evaluation by histological changes/structures in each group at Day 7(A), 14 (B) and 21 (C) after incision wound made, respectively. *P<0.05, **P<0.01. PMNL, polymorphonuclear leucocytes.

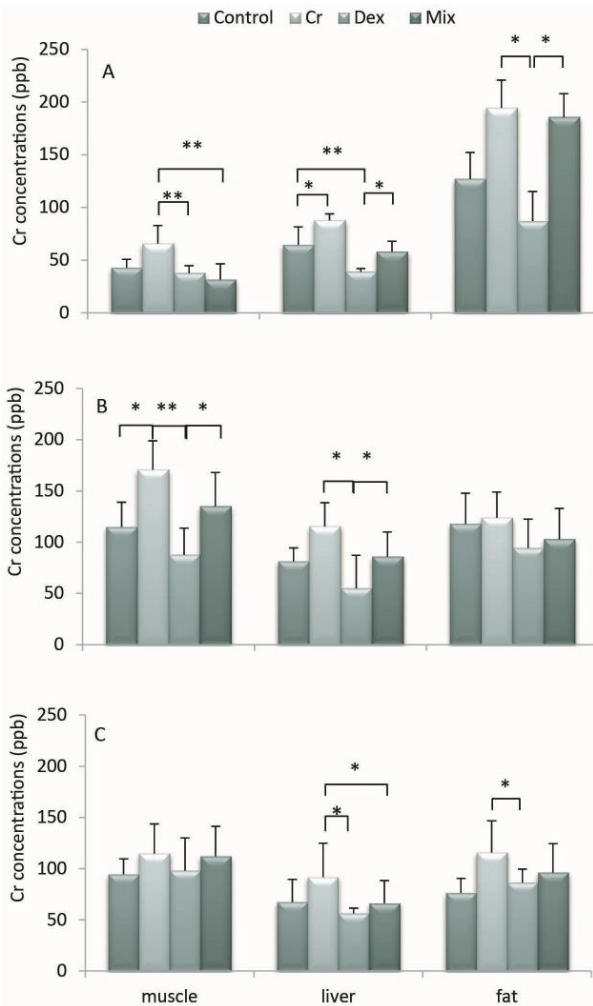


Fig. 6: Cr levels in muscle, liver and fat in each group at Day 7(A), 14(B) and 21(C) after incision wound made, respectively. * $P < 0.05$, ** $P < 0.01$.

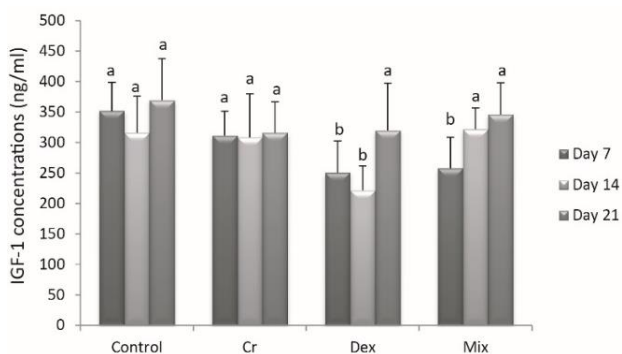


Fig. 7: The levels of serum IGF-1 in each group at Day 7, 14 and 21 after incision wound made. Different alphabet indicated significant difference ($P < 0.05$).

partly responsible for whole body catabolism against the anabolism function in insulin. However, in Mix groups, the serum IGF-1 levels showed a trend to increase. This result indicated that Cr^{3+} may have blockade the suppressive effect of glucocorticoids on IGF-1 (de Almeida *et al.*, 2015). At Day 14, the reverse effect of Cr^{3+} in Dex-induced low serum IGF-1 levels was more prominent, in which serum IGF-1 level was significantly higher in Mix group than Dex group. This evidence is in line with the result we obtained at Day 7 and suggested

that the Cr may increase the serum IGF-1 by enhancing insulin activity to increase the mRNA levels of IGF-1 and IGF-1 receptor (Peng *et al.*, 2010). The significant rise of the IGF-1 levels in Mix groups also indicated that regular ingestion of Cr^{3+} in diet may have anabolism effects against exogenous DEXs or stress-induced endogenous DEXs in hormone regulation which can be beneficial in clinical uses (King *et al.*, 2016).

Since the wound healing was associated with Cr^{3+} and the levels of IGF-1 discussed as above. In this study, the result indicated that an inhibition of inflammatory process due to prolonged presence of leucocytes during the 7 evaluated day in Dex group. The delayed inflammatory process led to less recruitment of various inflammatory cells and gene expression of many key wound healing cytokines and growth factors in the early phase of wounding period (Guo and DiPietro, 2010). Normally, the mitotic activity of basal cells produces thickened epidermis at the cut edges of wound. However, Dex group presented relatively thickened epidermis compared to control group, this may be resulted in an impaired process of reepithelization. The proliferation and migration of fibroblasts were decelerated as well. These results can be explained by glucocorticoids inhibited keratinocyte growth factor production in dermal fibroblasts (Chedid *et al.*, 1996). A negative impact on the formation of the granulation tissue observed in Dex group may be due to decreased process of neo-angiogenesis. This is in agreement with study in which daily local injection of dexamethason inhibited a basal sponge-induced angiogenesis (Hori *et al.*, 1996). The inflammatory cells in Mix groups at Day 7 showed less infiltration of neutrophils and mostly dominated by the macrophage compared to Dex group. It is understood that the extensive proliferation of fibroblasts is the first manifestation of the early matrix, observed subsequent to attenuation of the initial inflammatory response and is closely linked to early granulation tissue formation (Braiman-Wiksmann *et al.*, 2007). Thus, the fibroblasts are more intense calculated in Mix than Dex group at Day 7 that suggested Cr^{3+} may attenuate the inhibiting effects of DEXs on inflammatory process and enhanced the proliferation and migration of fibroblasts. The mature granulation tissue at late stages of the wound healing process is associated with deposition of collagen fibers. The more deposition of collagen fibers stained by Masson Trichrome in Mix group compared to Dex group at Day 14 also supported the theory that Cr^{3+} may restore the DEX-induced IGF-I attenuation and promote skin wound healing process in this study. (Reckenbeil *et al.*, 2017).

Conclusions: The results of his study may not present the direct evidence between Cr^{3+} with IGF-1. However, in this study we presented that Cr^{3+} may play a role to restore DEX-induced attenuation effect of IGF-1 and promote the skin wound healing process.

Acknowledgments: The authors would like to thank kind help of Dr. Cheng-Chung Lin for the histological scoring.

Authors contribution: YT and WM conceived and designed the study. TH, HC and KS executed the experiment and analyzed the sera and tissue samples. YT analyzed the data.

REFERENCES

- Amann J, Wessels AM, Breitenfeldt F, *et al.*, 2017. Quantifying cutaneous adverse effects of systemic glucocorticoids in patients with rheumatoid arthritis: a cross-sectional cohort study. *Clin Exp Rheumatol* 35:471-6.
- Braiman-Wiksmann L, Solomonik I, Spira R, *et al.*, 2007. Novel insights into wound healing sequence of events. *Toxicol Pathol* 35:767-79.
- Broughton G II, Janis JE and Attinger CE, 2006. The basic science of wound healing. *Plast Reconstr Surg* 117:12-34.
- Chen PW, Lin C, Chen CD, *et al.*, 2013. Chromium levels in insulin-sensitive tissues and the thigh bone are modulated by prednisolone and high-fat diets in mice. *Biomaterials* 26:347-54.
- Chen YL, Lin JD, Hsia TL, *et al.*, 2014. The effect of chromium on inflammatory markers, 1st and 2nd phase insulin secretion in type 2 diabetes. *Eur J Nutr* 53:127-33.
- Chedid M, Hoyle JR, Csaky KG, *et al.*, 1996. Glucocorticoids inhibit keratinocyte growth factor production in primary dermal fibroblasts. *Endocrinology* 137:2232-7.
- Cieszkowski J, Warzecha Z, Ceranowicz P, *et al.*, 2017. Therapeutic effect of exogenous ghrelin in the healing of gingival ulcers is mediated by the release of endogenous growth hormone and insulin-like growth factor-1. *J Physiol Pharmacol* 68:609-17.
- de Almeida TF, de Castro Pires T and Monte-Alto-Costa A, 2016. Blockade of glucocorticoid receptors improves cutaneous wound healing in stressed mice. *Exp Biol Med (Maywood)* 241:353-8.
- Evock-Clover CM, Polansky MM, Anderson RA, *et al.*, 1993. Dietary chromium supplementation with or without somatotropin treatment alters serum hormones and metabolites in growing pigs without affecting growth performance. *J Nutr* 123:1504-12.
- Gal P, Kilik R, Mokry M, *et al.*, 2008. Simple method of open skin wound healing model in corticosteroid-treated and diabetic rats: standardization of semi-quantitative and quantitative histological assessments. *Vet Med* 53:652-9.
- Guo S and Dipietro LA, 2010. Factors affecting wound healing. *J Dent Res* 89:219-29.
- Hori Y, Hu DE, Yasui K, *et al.*, 1996. Differential effects of angiostatic steroids and dexamethasone on angiogenesis and cytokine levels in rat sponge implants. *Br J Pharmacol* 118:1584-91.
- Hrynyk M and Neufeld RJ, 2014. Insulin and wound healing. *Burns* 40:1433-46.
- Jozic I, Vukelic S, Stojadinovic O, *et al.*, 2017. Stress Signals, Mediated by Membranous Glucocorticoid Receptor, Activate PLC/PKC/GSK-3 β / β -catenin Pathway to Inhibit Wound Closure. *J Invest Dermatol* 137:1144-54.
- Kato T, Khanh VC, Sato K, *et al.*, 2017. SDF-1 improves wound healing ability of glucocorticoid-treated adipose tissue-derived mesenchymal stem cells. *Biochem Biophys Res Commun* 493:1010-7.
- King HH, Wang HC, Chen KS, *et al.*, 2016. Trivalent chromium attenuated corticosterone secretion and actions in adrenocorticotrophic hormone-stimulated rats. *Pak Vet J* 36:41-4.
- Lee SY, Bae IH, Sung Park D, *et al.*, 2016. Prednisolone- and sirolimus-eluting stent: Anti-inflammatory approach for inhibiting in-stent restenosis. *J Biomater Appl* 31:36-44.
- Peng Z, Qiao W, Wang Z, *et al.*, 2010. Chromium improves protein deposition through regulating the mRNA levels of IGF-I, IGF-IR, and Ub in rat skeletal muscle cells. *Biol Trace Elem Res* 137:226-34.
- Reckenbeil J, Kraus D, Stark H, *et al.*, 2017. Insulin-like growth factor 1 (IGF1) affects proliferation and differentiation and wound healing processes in an inflammatory environment with p38 controlling early osteoblast differentiation in periodontal ligament cells. *Arch Oral Biol* 73:142-50.
- Sato J, Uchida T, Komiya K, *et al.*, 2017. Comparison of the therapeutic effects of prednisolone and nonsteroidal anti-inflammatory drugs in patients with subacute thyroiditis. *Endocrine* 55:209-14.
- Slominski AT and Zmijewski MA, 2017. Glucocorticoids Inhibit Wound Healing: Novel Mechanism of Action. *J Invest Dermatol* 137:1012-4.
- Vincent JB, 2004. Recent developments in the biochemistry of chromium (III). *Biol Trace Elem Res* 99:1-16.
- Wicke C, Halliday B, Allen D, *et al.*, 2000. Effects of steroids and retinoids on wound healing. *Arch Surg* 135:1265-70.
- Wolthers OD, Ramshanker N, Heuck C, *et al.*, 2017. The timing of administration of exogenous glucocorticoid affects 24hour growth hormone secretion in children. *Growth Horm IGF Res* 35:40-4.
- Yan H, Wang Y, Shen S, *et al.*, 2017. Corticosteroids effects on LPS-induced rat inflammatory keratocyte cell model. *PLoS One* 12:e0176639.
- Zhou W, Rowitz BM and Dailey MJ, 2018. Insulin/IGF-I enhances intestinal epithelial crypt proliferation through PI3K/Akt and not ERK signaling in obese humans. *Exp Biol Med (Maywood)*. 1535370218785152.