



RESEARCH ARTICLE

Protective Effects of Baicalein against Cadmium-Induced Oxidative Stress in Rat Testes

Jicang Wang^{1*}, Huali Zhu², Cai Zhang¹, Hongwei Wang¹ and Zijun Yang¹

¹College of Animal Science and Technology; ²Law hospital, Henan University of Science and Technology, No.263, Kaiyuan Avenue, 471023, Luoyang, PR China

*Corresponding author: wangjicang@126.com

ARTICLE HISTORY (17-133)

Received: April 19, 2017
Revised: January 10, 2019
Accepted: January 11, 2019
Published online: March 07, 2019

Key words:

Baicalein
Cadmium
Oxidative stress
Rat
Testes

ABSTRACT

This study explored the protective effects of baicalein on cadmium induced oxidative stress and morphological changes in rat testes. Twenty-four male Sprague–Dawley rats were assigned into four groups: control group, CdCl₂-treated group (2 mg/kg.b.w), Baicalein-treated group (100 mg/kg.b.w), CdCl₂+Baicalein-treated group (2 mg/kg.b.w CdCl₂ and 100 mg/kg.b.w of baicalein). They were treated accordingly for 4 weeks. Body weight, relative weight of the testes, and morphological changes of the testes were assessed. The levels of superoxide dismutase (SOD), catalase (CAT), glutathione peroxidase (GSH-Px), glutathione (GSH), and malondialdehyde (MDA) were measured. Results showed that cadmium decreased the body weight, and relative weight of the testes. In cadmium-treated rats, the spermatogenic cells in the testicular seminiferous tubule showed disordered arrangement and structure, and their levels were unclear. Furthermore, cadmium increased the activities of antioxidant enzymes, SOD, CAT and GSH-Px, decreased GSH levels, and increased MDA content in the testes, indicating cadmium-induced oxidative stress. However, baicalein treatment increased the body weight and relative weight of the testes and prevented cadmium-induced testicular damage. Treatment with baicalein reversed the cadmium-induced changes of the antioxidant defense system. Therefore, as an effective antioxidant, baicalein protects testes from cadmium-induced oxidative stress and injury.

©2019 PVJ. All rights reserved

To Cite This Article: Wang J, Zhu H, Zhang C, Wang H and Yang Z, 2019. Protective effects of baicalein against cadmium-induced oxidative stress in rat testes. Pak Vet J, 39(2): 216-220. <http://dx.doi.org/10.29261/pakvetj/2019.025>

INTRODUCTION

Manufactured or domestic chemicals, fertilizers, heavy metals are considered environmental pollutants. Many of them can induce oxidative stress. Particularly, cadmium, lead, arsenic and mercury are heavy metals that constitute severe dangers to human wellbeing health (Ognjanović *et al.*, 2010; Liu *et al.*, 2016; Tahir *et al.*, 2017). Cadmium is a poisonous environmental pollutant. Cadmium is classified as a human carcinogen (Group 1 [IARC], Group 2a [EPA], and 1B Carcinogen [ECHA]). However, cadmium is widely used in batteries, plastics, colors, and electroplated. The main way for smokers or professional workers to ingest cadmium is through inhalation (Siu *et al.*, 2009). Industrial workers as well as people in general, are exposed to cadmium given its increased production and usage. Cadmium can induce various severe pathological conditions such as hepatic and renal dysfunctions, testicular harm, and nervous system issue.

Long-term exposure to low doses of cadmium has become a growing public health concern, which can invade

into an individual's or animal's body mainly by the following ways: ingestion of cadmium-contaminated foods (e.g., irrigation water and fertilizers) and/or cadmium bioconcentration in aquatic and plant organisms through food chains intake of polluted water, or inhalation of polluted air. Ingestion of cadmium affects the functions of the kidney, liver, bones and other tissues (Butt *et al.*, 2018). Furthermore, cadmium induces free-radical production, leading to the oxidative stress of lipids, proteins and DNA.

The health benefits of plant-derived polyphenolic compounds have been extensively studied. Baicalein is the main active constituent in the roots of the medicinal herb *Scutellaria baicalensis Georgi* (Lamiaceae family) (Sahu *et al.*, 2015). The roots of *S. baicalensis* have been utilized for the treatment of bacterial and chronic hepatitis, thrombotic stroke in China (Hsieh *et al.*, 2007). Baicalein can improve myocardial ischemic/reperfusion injury and show remedial impact in endotoxin-induced myocardial dysfunction in rats (Song *et al.*, 2014). Baicalein decreases doxorubicin-induced cardiotoxicity suppressing myocardial oxidative stress, apoptosis, and JNK activation

(Sahu *et al.*, 2016). Many *in vitro* studies of baicalien have been carried out. However, no study has clarified the mechanism and valuable impact of baicalein on testes in cadmium-induced injury *in vivo* study. Hence, this study investigated the mechanisms to understand the protective effects of baicalein on rat testes.

In this study, the body weight, relative weight of the testes, and morphological changes of the testes of male Sprague–Dawley (SD) rats were examined. Cadmium-induced biochemical aspects were investigated by measuring the levels of superoxide dismutase (SOD), catalase (CAT), glutathione peroxidase (GSH-Px), glutathione (GSH), and malondialdehyde (MDA). In addition, the protective effects of baicalein on cadmium-induced injury in rat testes were studied.

MATERIALS AND METHODS

Chemicals: SOD, CAT, GSH-Px, MDA and GSH kits (Nanjing Jiancheng Bioengineering Institute, Nanjing, China). CdCl₂ was obtained from Aladdin Industrial Corporation. Furthermore, baicalein (purity: >98%) was purchased from Mianyang Oriental Source Technology Co., Ltd (Mianyang, China).

Animals: Adult male SD rats weighing 180–200 g were used and kept on 12 h light: 12 h dark cycles with controlled temperature (24±2°C). They were fed with a commercial standard diet with free access to drinking water under standard laboratory conditions.

Experimental design: After acclimatization to the laboratory conditions for 2 weeks, the rats were randomly divided into four experimental groups with 6 rats each. They were treated everyday as follows: control group (received redistilled water and 0.9% NaCl by oral gavage); CdCl₂-treated group (received 2 mg/kg.b.w of CdCl₂ intraperitoneally); baicalein-treated group (received 100 mg/kg.b.w of baicalein daily by oral gavage) and CdCl₂+baicalein-treated group (received 2 mg/kg.b.w of CdCl₂ intraperitoneally and 100 mg/kg.b.w of baicalein intragastrically).

Every weekend, the rats' body weight was recorded. The experiment lasted for 4 weeks. After the treatments, the rats were anesthetized with ether anesthesia. Then, all rats were sacrificed, and the testes were removed and washed using cold PBS solution. The relative weight of the testes was calculated. Tissues were minced, homogenized (10%, w/v) in PBS solution (pH 7.4), and centrifuged (3000 rpm for 10 min). The clear supernatant was stored at -80°C and used for different enzymatic and nonenzymatic biochemical measures. Moreover, some testes were preserved in 10% neutral buffered formalin for microscopic analysis.

Biochemical assays: The lipid peroxidation (LP) content was exhibited by the MDA level with thiobarbituric acid

reaction. The testicular SOD, CAT, GSH-Px, GSH and MDA levels were analyzed using commercial kits (Wang *et al.*, 2012).

Histopathological analyzes: The testicular tissues were fixed in 10% neutral buffered formalin for 48 h, dehydrated with different concentrations of ethanol, cleared with xylene and embedded in paraffin. Then, 4 µm-thick sections were prepared and stained with hematoxylin and eosin (Sahu *et al.*, 2016). The structural changes of the sections were assessed by optical microscopy.

Statistical analyses: The results obtained were expressed as the mean ± standard deviation. All statistical analyses were performed using SPSS 15.0 statistical software. Comparison of means was subjected to one-way analysis of variance and Duncan's multiple range test. Values were considered significant when P<0.05.

RESULTS

Effect of baicalein on cadmium-induced body weight and relative weight of the testes: As shown in Table 1, in rats treated with cadmium alone, the body weight significantly (P<0.05) decreased compared with that of the control group after cadmium exposure for 1–4 weeks. However, treatment with baicalein (100 mg/kg) alongside cadmium significantly decreased the reduction in body weight (P<0.05) after exposure for 3 and 4 weeks compared with the control group.

Effect of baicalein on cadmium-induced relative weight of the testes in rats: As shown in Table 2, in rats treated with cadmium alone, the relative weight of the testes significantly decreased (P<0.05) compared with that of the control group. Treatment with baicalein (100 mg/kg/day) alongside cadmium increased the relative weight of the testes. However, no significant difference was found compared with the cadmium group (P>0.05).

Histological assessment of seminiferous tubules: The testicular seminiferous tubules of rats in the control group (Fig. 1A and B) and the baicalein-treated group (Fig. 1E and F) were arranged in order, interstitial clear, seminiferous tubules seen in all stages of spermatogenic cells. Examination of tissue sections affirmed the extreme morphological changes in the testes of cadmium-treated rats. In cadmium-treated rats, the spermatogenic cells in the testicular seminiferous tubule showed disordered arrangement and structure, and their levels were unclear; meanwhile, the sperm chromatin structure of the testes in the cavity of the spermatogenic small tube could not be observed (Fig. 1C and D). In the CdCl₂+baicalein group (Fig. 1G and H), the atrophy and degeneration of rat testicular tissue structure were significantly improved, and germ cells levels of in the tubule of rats were basically in order.

Table 1: Effects of baicalein on cadmium-induced changes in body weight (g)

Treated	week 0	week 1	week 2	week 3	week 4
control	176.92±18.64	214.16±14.23	239.35±8.81	258.71±9.15	274.37±12.17
cadmium	172.40±11.15	187.44±12.81*	219.77±16.62*	220.72±20.83*	232.50±23.64*
baicalein	178.73±13.14	211.36±21.28	240.24±22.17	256.87±20.25	278.30±19.83
cadmium+ baicalein	176.72±14.79	191.25±22.60	217.37±10.77	233.04±11.51 [#]	240.08±13.52 [#]

*P<0.05, compared with control group (non-cadmium exposed group); [#]P<0.05 compared with cadmium exposed group, the same as follow.

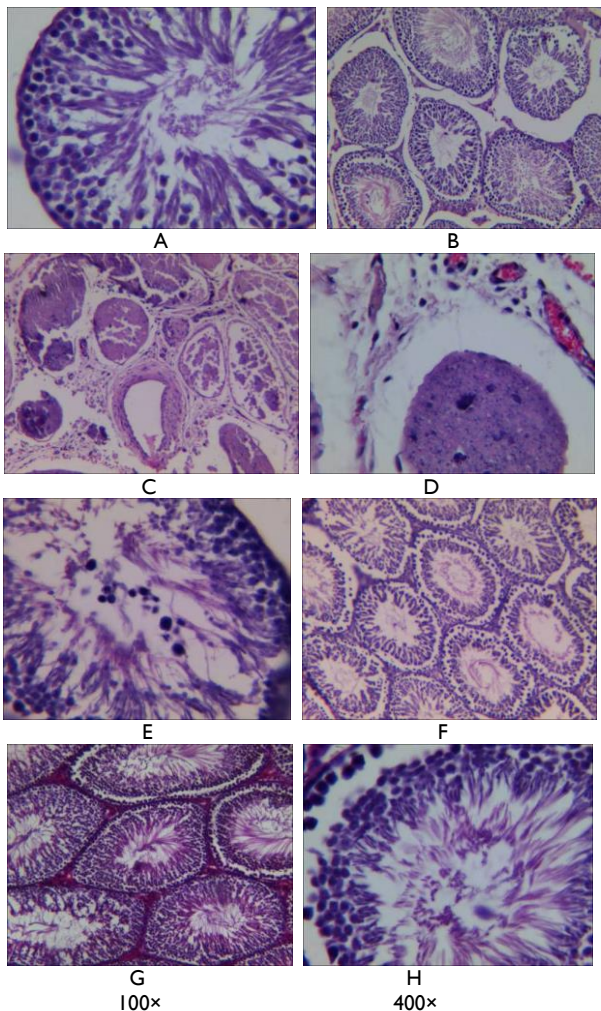


Fig. 1 Testicular histopathology of rats treated with cadmium and baicalein (A, C, E, G 100 \times ; B, D, F, H 400 \times); A, B: control showing seminiferous tubules arranged in order, interstitial clear, seminiferous tubules seen in all stages of spermatogenic cells; C, D: cadmium treated rats showing the spermatogenic cells in the testicular seminiferous tubule showed disordered arrangement and structure, and their levels were unclear; meanwhile, the sperm chromatin structure of the testes in the cavity of the spermatogenic small tube could not be observed; E, F: baicalein alone treated rats showing normal appearance of testicular structure; G, H: cadmium and baicalein treated showing germ cells levels of in the tubule of the rats were basically in order.

Table 2: Effects of baicalein on cadmium-induced changes in relative weight of the testes

Group	control	cadmium	baicalein	cadmium + baicalein
	1.17 \pm 0.18%	0.33 \pm 0.11%*	1.13 \pm 0.08%	0.35 \pm 0.16%

Table 3: Testicular oxidative stress parameters of rats treated with cadmium and baicalein

Group parameter	control	cadmium	baicalein	cadmium+baicalein
SOD (U/mgprot)	11.63 \pm 0.84	15.78 \pm 2.04 [#]	12.07 \pm 0.89	14.65 \pm 1.96 [#]
CAT (U/mgprot)	59.88 \pm 7.12	80.05 \pm 8.09 [#]	65.79 \pm 4.87	68.69 \pm 4.31 [#]
GSH-Px (U/mgprot)	9.74 \pm 1.23	12.87 \pm 1.57 [#]	9.61 \pm 1.37	10.59 \pm 1.84 [#]
GSH (mg/gprot)	2.29 \pm 0.37	1.56 \pm 0.21*	2.57 \pm 0.38	2.13 \pm 0.11 [#]
MDA (nmol/mgprot)	2.93 \pm 0.45	5.01 \pm 0.38 [#]	2.44 \pm 0.25	4.13 \pm 0.13 [#]

Histological assessment of seminiferous tubules: The testicular seminiferous tubules of rats in the control group (Fig. 1A and B) and the baicalein-treated group (Fig. 1E and F) were arranged in order, interstitial clear, seminiferous tubules seen in all stages of spermatogenic cells. Examination of tissue sections affirmed the extreme

morphological changes in the testes of cadmium-treated rats. In cadmium-treated rats, the spermatogenic cells in the testicular seminiferous tubule showed disordered arrangement and structure, and their levels were unclear; meanwhile, the sperm chromatin structure of the testes in the cavity of the spermatogenic small tube could not be observed (Fig. 1C and D). In the CdCl₂+baicalein group (Fig. 1G and H), the atrophy and degeneration of rat testicular tissue structure were significantly improved, and germ cells levels of in the tubule of rats were basically in order.

Effect of baicalein on testicular oxidative stress:

Changes in oxidative status were assessed by enzymatic and nonenzymatic measures. Cadmium administration significantly increased the levels of SOD, CAT and GSH-Px ($P < 0.05$) and decreased the GSH content ($P < 0.05$) in the testicular tissue compared with the control group. Baicalein treatment significantly ($P < 0.05$) recovered the levels of these antioxidants to nearly normal values when compared with the cadmium-treated rats.

In rats treated with cadmium alone the MDA level significantly increased (Table 3) compared with the control group. Baicalein treatment attenuated the cadmium-induced elevation of MDA in the testicular tissue.

DISCUSSION

Cadmium is one of the highly toxic environmental pollutants. It can induce oxidative damage by disturbing the oxidant/antioxidant balance in the tissue, as observed in previous study (Adi *et al.*, 2016). The male reproductive system is particularly sensitive to cadmium (Doaa *et al.*, 2014). However, the mechanisms of cadmium-induced male reproductive system toxicity have not been established (Spiazzi *et al.*, 2013). Whether baicalein has the ability of protective effects against cadmium-induced toxicity has not been clarified. In this study, the body weight loss, relative testicular mass, morphological changes, and oxidative stress of the testes in rats exposed to cadmium were investigated to elucidate its molecular toxicity mechanisms.

We demonstrated that intraperitoneal injection of 2 mg CdCl₂/kg for 28 days induced weight loss and reduced relative testicular mass and macroscopic changes in rats. Weight gain is related to the availability and absorption of nutrients (Asagba and Eriyamremu, 2007). Our results showed that cadmium can inhibit the growth of rats. Cadmium-induced decreased nutrient digestion and absorption has also been shown (Eriyamremu *et al.*, 2005). The current study is consistent with the results of Horiguchi *et al.* (1996), who found that the effect of cadmium can induce body weight loss. Yousef *et al.* (2008) indicated that body weight reduction can be used as an important indicator for the deterioration of rat general health status. Cadmium has inhibitory action on digestive and absorption enzymes (Asagba, 2010). This finding may explain the weight loss of rats as observed in this experiment. Reduced relative testicular mass is consistent with recent studies that cadmium decreases testicular volume, sperm count and motility (Ekhoje *et al.*, 2013; Djuric *et al.*, 2015). Szuster-Ciesielska *et al.* (2000)

reported that the decrease in the quality of male sex organs is a major indicator of the changes in the status of androgen, which can lead to apoptosis and necrosis of testicular tissue.

In the testes of rats in the cadmium-treated group, we found histopathological alterations, including the degeneration of seminiferous tubules and germinal cells, and the absence of spermatogenesis (Fig. 1C and D). The irregular arrangement of spermatogenic cell lines showed the lack of spermatogenesis. Laskey and Phelps (1991) also observed the decreased testicular testosterone level may be due to its reduced production by Leydig cells. Baicalein treatment significantly inhibited body weight loss and testicular relative weight. In addition, optical microscopic examination of testicular tissue in CdCl₂+baicalein (100 mg/kg) -treated rats revealed almost normal seminiferous tubules compared with rats treated with cadmium alone. Thus, our results showed baicalein reduced the cadmium-induced weight loss and exhibited testicular protective effect.

Our results showed that the activities of antioxidative enzymes SOD, CAT, and GSH-Px increased in the testes of rats exposed to cadmium. However, this finding was contrary to that in the liver and kidney (data not shown). Djuric *et al.* (2015) reported that SOD and CAT decreased in cadmium-treated male Wistar rats for 21 days. This difference is related to the route, dose, and duration of exposure to cadmium. The reason for this result is that cadmium stimulated testicular cells induced oxidative stress. Considering the cellular response to oxidative damage, the expression of these enzymes was enhanced to balance a large number of ROS. Thus, the activity increased. The results in testes differed from those in the liver and kidneys, possibly because the testes have a specific blood testicular barrier; in addition, cadmium cannot easily enter the testes and the organizational structure of different cells may have led to different reactions caused by cadmium. Ezedom and Asagba (2016) reported that the activities of oxidative enzymes increased after rats were exposed to cadmium for one month (P<0.05). This finding may be because the level of cadmium was still at a low accumulated state after the 1 month exposure. Treatment with baicalein significantly reduced the activities of SOD, CAT and GSH-Px. To clarify the mechanisms of baicalein exerting its effect on cadmium-induced testicular toxicity, we treated rats with baicalein and cadmium. We found that baicalein decreased the activities of SOD, CAT and GSH-Px significantly. Thus, that baicalein could reduce the oxidative injury induced by cadmium in rats.

The changes in GSH and MDA levels in the testes are shown in Table 3. Exposure to cadmium decreased the GSH level and increased the MDA level (i.e., LPO level). Cadmium exposure can produce free radicals and lead to an increase in LP levels (Varoni *et al.*, 2016). LP inactivates cellular components by oxidative stress in free radical chain reaction, ultimately resulting in the loss of membrane integrity or oxidation. It is a sulfhydryl peptide widely found in all biological systems. GSH acts as a nonenzymatic antioxidant to defend against oxidative stress. The decrease in GSH levels may be because of its utilization in the scavenging free radicals created by cadmium, thereby interfering with the antioxidant activity

(Wang *et al.*, 2012). Cadmium also interferes with protein metal-binding sites and/or functional groups by altering essential biometal homeostasis and the activities of corresponding metal enzymes in various organs (Wang *et al.*, 2018). The stimulation of LP observed in this study could be because of the formation of free radicals through an exhaustion of antioxidants leading to oxidative stress and ultimately, increasing the LP level. Baicalein can inhibit oxidative stress-induced cellular damage via antioxidant effects (Kang *et al.*, 2012). Interestingly, baicalein markedly increased GSH level and decreased MDA level in cadmium-treated rat testes in our study. Our results showed that baicalein can reduce oxidative stress by reducing the LP level in cadmium-treated testes.

Conclusions: Cadmium administration significantly decreased the body weight and the relative weight of the testes. Furthermore, it induced serious testicular injury and elevated SOD, CAT, and GSH-Px activities. The GSH level decreased, whereas the MDA level increased when rats were treated with cadmium. Conversely, treatment with baicalein ameliorated the cadmium-induced testicular toxicity in rats. Therefore, baicalein may be useful to treat cadmium toxicity.

Authors contribution: WJ, ZH and YZ conceived and designed the experiment. WJ, ZH, ZC and WH performed the experiment and analyzed the data. WJ and ZH wrote the paper. All authors have contributed to, read and approved the manuscript.

Acknowledgements: This study was supported by the Natural Science Foundation of Henan Province (No: 182300410048)

REFERENCES

- Adi PJ, Burra SP, Vataparti AR, *et al.*, 2016. Calcium, zinc and vitamin E ameliorate cadmium-induced renal oxidative damage in albino Wistar rats. *Toxicol Reports* 3:591-7.
- Asagba S, 2010. Alteration in the activity of oxidative enzymes in the tissues of male wistar albino rats exposed to cadmium. *Int J Occup Med Environ Health* 23:55-62.
- Asagba S and Eriyamremu G, 2007. Oral cadmium exposure alters haematological and liver function parameters of rats fed a Nigerian-like diet. *J Nutr Environ Med* 16:267-74.
- Butt SL, Kashif M, Khan M, *et al.*, 2018. Cadmium toxicity in female Japanese quail (*Coturnix japonica*) and its diminution with silymarin. *Pak Vet J* 38:249-55.
- Djuric A, Begic A, Gobeljic B, *et al.*, 2015. Oxidative stress, bioelements and androgen status in testes of rats subacutely exposed to cadmium. *Food Chem Toxicol* 86:25-33.
- Doaa M, Ashraf S, Ahmed O, *et al.*, 2014. Effect of cadmium on the testes of adult albino rats and the ameliorating effect of zinc and vitamin E. *British J Sci* 11:72-95.
- Ekhoye E, Nwangwa E and Aloamaka C, 2013. Changes in some testicular biometric parameters and testicular function in cadmium chloride administered Wistar rats. *British J Med Med Res* 3:2031.
- Eriyamremu G, Asagba S, Onyeneke E, *et al.*, 2005. Changes in carboxypeptidase A, dipeptidase and Na⁺/K⁺ ATPase activities in the intestine of rats orally exposed to different doses of cadmium. *Biometals* 18:1-6.
- Ezedom T and Asagba SO, 2016. Effect of a controlled food-chain mediated exposure to cadmium and arsenic on oxidative enzymes in the tissues of rats. *Toxicol Reports* 3:708-15.
- Horiguchi H, Sato M, Konno N, *et al.*, 1996. Long-term cadmium exposure induces anemia in rats through hypoinduction of erythropoietin in the kidneys. *Arch Toxicol* 71:11-9.

- Hsieh CJ, Hall K, Ha T, *et al.*, 2007. Baicalein inhibits IL-1 β -and TNF- α -induced inflammatory cytokine production from human mast cells via regulation of the NF-kB pathway. *Clin Mol Aller* 5:5.
- Kang KA, Zhang R, Piao MJ, *et al.*, 2012. Baicalein inhibits oxidative stress-induced cellular damage via antioxidant effects. *Toxicol Indust Health* 28:412-21.
- Laskey J and Phelps P, 1991. Effect of cadmium and other metal cations on in vitro Leydig cell testosterone production. *Toxicol Appl Pharmacol* 108:296-306.
- Liu G, Wang ZK, Wang ZY, *et al.*, 2016. Mitochondrial permeability transition and its regulatory components are implicated in apoptosis of primary cultures of rat proximal tubular cells exposed to lead. *Arch Toxicol* 90:1193-209.
- Ognjanović BI, Marković SD, Đorđević NZ, *et al.*, 2010. Cadmium-induced lipid peroxidation and changes in antioxidant defense system in the rat testes: Protective role of coenzyme Q 10 and Vitamin E. *Reprod Toxicol* 29:191-7.
- Sahu BD, Kumar JM, Kuncha M, *et al.*, 2016. Baicalein alleviates doxorubicin-induced cardiotoxicity via suppression of myocardial oxidative stress and apoptosis in mice. *Life Sci* 144:8-18.
- Sahu BD, Kumar JM and Sistla R, 2015. Baicalein, a bioflavonoid, prevents cisplatin-induced acute kidney injury by up-regulating antioxidant defenses and down-regulating the MAPKs and NF-kB pathways. *PLoS One* 10:e0134139.
- Siu ER, Mruk DD, Porto CS, *et al.*, 2009. Cadmium-induced testicular injury. *Toxicol Appl Pharmacol* 238:240-9.
- Song L, Yang H, Wang HX, *et al.*, 2014. Inhibition of 12/15 lipoxygenase by baicalein reduces myocardial ischemia/reperfusion injury via modulation of multiple signaling pathways. *Apoptosis* 19:567-80.
- Spiazzi CC, Manfredini V, da Silva FEB, *et al.*, 2013. c-Oryzanol protects against acute cadmium-induced oxidative damage in mice testes. *Food Chem Toxicol* 55:526-32.
- Szuster-Ciesielska A, Stachura A, Słotwińska M, *et al.*, 2000. The inhibitory effect of zinc on cadmium-induced cell apoptosis and reactive oxygen species (ROS) production in cell cultures. *Toxicology* 145:159-71.
- Tahir MVV, Saleemi MK, Khan A, *et al.*, 2017. Hematobiochemical effects of cadmium intoxication in male Japanese quail (*Coturnix japonica*) and its amelioration with silymarin and milk thistle. *Toxin Rev* 36:187-93.
- Varoni MV, Pasciu V, Gadau SD, *et al.*, 2017. Possible antioxidant effect of *Lycium barbarum* polysaccharides on hepatic cadmium-induced oxidative stress in rats. *Environ Sci Poll Res* 24:2946-55.
- Wang J, Zhu H, Cai Z, *et al.*, 2018. Baicalein ameliorates cadmium-induced hepatic and renal oxidative damage in rats. *Indian J Anim Res* DOI: 10.18805/ijar.B-853.
- Wang JC, Yang Z, Lin L, *et al.*, 2012. Protective effect of naringenin against lead-induced oxidative stress in rats. *Biolog Trace Element Res* 146:354-9.
- Yousef MI, El-Demerdash FM, Radwan FM, 2008. Sodium arsenite induced biochemical perturbations in rats: ameliorating effect of curcumin. *Food Chem Toxicol* 46:3506-11.