



CASE REPORT

Long-Term Use of Oclacitinib for the Control of Pruritus in a Geriatric Atopic Dog

P Chansiripornchai* and N Chansiripornchai

Faculty of Veterinary Science, Chulalongkorn University, Bangkok 10330, Thailand

*Corresponding author: spiyarat@hotmail.com

ARTICLE HISTORY (18-134)

Received: April 07, 2018

Revised: May 28, 2018

Accepted: June 06, 2018

Published online: November 13, 2018

Key words:

Atopic dermatitis

Geriatric dog

Oclacitinib

ABSTRACT

An 8 – year – old, 23 kg male beagle dog with a repeated history of chronic atopic dermatitis was presented at the animal hospital. The dog had been treated at previous animal hospitals with a variety of drugs such as antimicrobials, glucocorticoids, cyclosporine, skin supplements and topical shampoo therapy on separate occasions. Microscopic examination of skin samples from the dog revealed the presence of *Malassezia pachydermatis*. The dog was treated with oclacitinib and itraconazole orally. Chlorhexidine plus miconazole shampoo was used as a topical therapy. The level of pruritus in the dog was decreased within 24 h of the first administration of the drugs. The dog's skin lesions decreased by week 2 and the skin lesions were resolved by week 8. There were no clinical abnormalities in the dog throughout 12 months of the treatment with oclacitinib.

©2018 PVJ. All rights reserved

To Cite This Article: Chansiripornchai P and Chansiripornchai N, 2019. Long-term use of oclacitinib for the control of pruritus in a geriatric atopic dog. Pak Vet J, 39(2): 313-315. <http://dx.doi.org/10.29261/pakvetj/2018.105>

INTRODUCTION

Canine atopic dermatitis (CAD) is the most frequent type of allergic dermatosis (Favrot, 2016). CAD has a genetically predisposed tendency to develop IgE – mediated allergy to environmental allergens (Olivry *et al.*, 2010). One of the diagnoses of CAD is based on the history, development of the disease and the pattern of lesions (Favrot, 2016). There is a set of criteria for the diagnosis of CAD as follows: age onset <3 years, mostly indoor, corticosteroid-responsive pruritus, chronic or recurrent yeast infections, affected front feet, affected ear pinnae, non - affected ear margins and non-affected dorso-lumbar area. CAD is diagnosed when 5 of 8 criteria are fulfilled (Favrot *et al.*, 2010). Although CAD is a life-long disease that cannot be cured but, in most cases, it can be successfully controlled. Several studies have described the role of cytokine dysregulation in the development of both human and CAD (Cosgrove *et al.*, 2015). Especially, the over expression of T-helper type 2 cytokines such as IL 2, 4, 6, 13 and 31 is the main cause of pruritus (Falk and Ferrer, 2015). Janus kinase (JAK) plays a role in cytokine signaling, with JAK 1 and JAK 3 involved in the signaling of numerous cytokines involved in allergy and inflammation (IL 2, 4, 6, 13), including IL 31, which is considered to have a major role in the pathophysiology of CAD (Gonzales *et al.*, 2014).

Oclacitinib is a novel JAK inhibitor for the control of pruritus in atopic dogs (Cosgrove *et al.*, 2015) by inhibiting IL 2, 4, 6, 13 and 31 thereby help to reduce pruritus and

inflammation (Gonzales *et al.*, 2014). Oclacitinib can be used instead of glucocorticoids (GCs) and cyclosporine (CsA) in those atopic dogs that cannot keep the severity of pruritus under control or tolerate the adverse drug reactions (ADRs) to both drugs. Especially, using GCs or CsA in a geriatric atopic dog may easily induce ADRs. There is a study that indicates the efficacy and safety of long – term use of oclacitinib in the USA (Cosgrove *et al.*, 2015). However, the ADRs of the drug, such as diarrhea, vomiting, pyoderma, otitis and urinary tract infection, are the most frequently reported in some dogs (Cosgrove *et al.*, 2015). Therefore, further independent and long-term studies are needed to prove the efficacy and safety of this drug for the control of pruritus in CAD.

This is the first report on a successful control of pruritus in a geriatric atopic dog using oclacitinib for 12 months long-term treatment in Thailand.

Case history and clinical examination: An 8-year-old, 23 kg male beagle dog with a history of chronic atopic dermatitis was presented at the skin clinic at Suvarnachad Animal Hospital, Bangkok. The skin problem in the dog started when he was 3-year-old. The first symptom was severe pruritus. The dog had been treated in previous animal hospitals with a variety of drugs such as antimicrobials, GCs, CsA, skin supplements and topical shampoo therapy on separate occasions. Moreover, an 8-week food allergy test using novel proteins, or hypoallergenic diet had been done but no response to the trials was revealed.

Physical examination revealed excoriation, lichenification, hyperpigmentation, hyperkeratosis and oily seborrhea on the ventral area of the dog (Fig. 1a, b). Folliculitis with haemorrhagic exudation was found on both forelegs. The level of pruritus observed by the dog's owner was 9 (from level 1 to 10). Otitis externa was found in both ears. Multiple skin scrapings were done and explored microscopically in paraffin oil, while other portions were stained with Gram's staining. The microscopic examination revealed an overgrowth of *Malassezia pachydermatis* and a few cocci bacteria. Haematology, blood chemistry and urinalysis were ranged in the normal value for a dog.

Treatment: The dog was treated with oclacitinib (Apoquel[®], Zoetis, USA) at 0.4 mg/kg PO q 12 h for 14 days then decreased to 0.4 mg/kg PO q 24 h from day 15. Itraconazole (Spornar[®], Charoen Bhaesaj Lab. Co., LTD., Thailand) at 7 mg/kg PO q 24 h was prescribed for 8 weeks then decreased to 7 mg/kg PO qod. Chlorhexidine plus miconazole shampoo (Malaseb[®], Dermcare – VetPty Ltd., Australia) was used as a topical therapy. Oclacitinib and itraconazole were still prescribed for the maintenance of CAD. Topical ear drugs composed of marbofloxacin, clotrimazole and dexamethasone (Aurizon[®], Vetoquinol, France) were used for the treatment of otitis externa for 14 days. Skin cytology and the general health of the dog were analysed at intervals of 3-4 weeks.

A typical treatment outcome was observed after 24 h of treatment. The level of pruritus in the dog was decreased from level 9 to level 2 within 24 h of the first administration of the drugs and was decreased from level 2 to level 1 by week 2. The dog's skin lesions decreased and hair regrowth appeared by week 2. The skin lesions were resolved by week 8 (Fig. 1c, d). There were no clinical abnormalities in the dog throughout the 12 months of the treatment. Haematology and blood chemistry were also at the normal value (Table 1).

DISCUSSION

In this report, the long-term administration of oclacitinib for the control of pruritus appeared to be well tolerated in a geriatric atopic dog. The criterion for diagnosis of CAD is useful in order to rule out CAD from other pruritic skin diseases (Favrot *et al.*, 2010). In our report, the dog had 6 of 8 criterias of CAD including; corticosteroid-responsive pruritus, chronic or recurrent yeast infections, affected front feet, affected ear pinnae, non-affected ear margins and non-affected dorso-lumbar area, therefore it was indicated that he is an atopic dog (Favrot *et al.*, 2010).

One of the key therapeutic goals when treating CAD is to stop the itching quickly for both the quality of life of the dog and the owner (Favrot *et al.*, 2010). GCs are the most frequently and effectively prescribed drug for antipruritus in atopic dogs but they can cause severe ADRs. CsA is approved for use in the control of CAD but is limited by long time onset of action.

Moreover, GCs and CsA can easily induce ADRs in geriatric animals since the decrease in normal organ protective mechanisms in the geriatric animals may increase the risk of ADRs (Boothe, 2012). Therefore, it is

important to take account of this point when prescribing the drugs to a geriatric animals.

In this report, severe pruritus and *Malassezia* overgrowth in a geriatric atopic dog were successfully controlled with oclacitinib and itraconazole, respectively within 8 weeks of treatment. Resolution of the condition was complete by week 8 and ADRs did not occur. In the USA, Canada and the EU, oclacitinib is approved for the control of pruritus in allergic dermatitis in dogs of 12 months in age or older (Cosgrove *et al.*, 2015). The

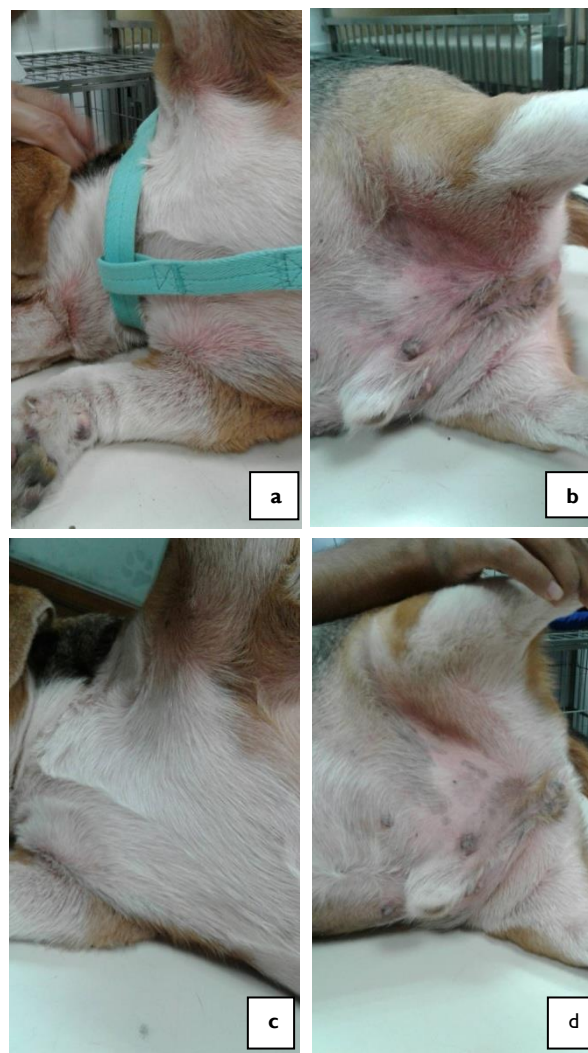


Fig. 1: Macroscopic lesions on the ventral areas of the dog. a and b, before treatment; c and d, at week 8 of treatment.

Table 1: Haematology and blood chemistry profiles in the dog on D₀, Wk₄ and Wk₈ of treatment

Parameters	D ₀	Wk ₄	Wk ₈	Reference*
RBC (x10 ⁶ /μl)	07.42	07.34	07.63	4.48-8.53
Hb (g/dl)	16.90	16.70	16.80	10.5-20.1
Hct (%)	49.60	48.70	46.30	33-58.7
MCV (fl)	66.80	66.20	67.20	63-78.3
Platelet (x10 ³ /μl)	479	452	438	140-540
WBC (x10 ³ /μl)	20.77	14.20	13.90	4.0-18.2
Neutrophil (x10 ³ /μl)	16.20	10.80	8.70	2.5-15.7
Eosinophil (x10 ³ /μl)	1	00.90	0.20	0-1.3
Lymphocyte (x10 ³ /μl)	4.03	03.80	1.04	0.3-3.9
ALT (U/L)	41	50	38	14-151
Creatinine (mg/dl)	0.6	0.70	0.70	0.4-2.0
BUN (mg/dl)	14	12	13.10	8-30
ALP (U/L)	301	295	232	13-289
Glucose (mg/dl)	99	102	94	74-145

* Plumb, 2015

recommended dose is 0.4-0.6 mg/kg PO q 12 h, administered for the first 2 weeks, followed by 0.4-0.6 mg/kg q 24 h as a maintenance dose (Falk and Ferrer, 2015). In our report, oclacitinib was used as antipruritic drug. As a result, oclacitinib was effective in controlling CAD, decreasing pruritus within 24 h of the first administration of the drug and improving the skin condition within week 2 of the treatment. This report is concurrent to the previous study that oclacitinib provided relief in itching within 24 h of the first administration of the drug (Cosgrove *et al.*, 2013). However, increased pruritus occurred in the dog in week 3 when the drug was decreased from q 12 h to q 24 h. This may be temporary and could resolve spontaneously. There is a recommendation that the administration of oclacitinib at the most pruritic period of the day can help restore control of the pruritus (Falk and Ferrer, 2015). Therefore, we gave the drug in the morning which was the most pruritic period for this dog when the frequency of administration was decreased from q 12 h to q 24 h in week 3. As a result, the level of pruritus in the dog decreased on day 7 of week 3.

On the other hand, *M. pachydermatis* and *Staphylococcus pseudintermedius* are frequently colonized on the skin of atopic dogs, so treatment of both microbials is needed. Itraconazole was prescribed to control the overgrowth of *Malassezia* and it is a suitable drug for treatment of *Malassezia* infection. Marbofloxacin was prescribed as an antibacterial drug for bacterial skin infection and otitis externa. This drug is a second tier drug for the treatment of bacterial skin infection (Hillier *et al.*, 2014). In our report, the number of *M. pachydermatis* was decreased by week 2 after

dosing. The severity of otitis externa was also decreased by week 2 of the treatment.

Although CAD cannot be cured it can be controlled by drug therapy. Our report indicates the efficacy and safety of oclacitinib for long-term use up to 12 months in a geriatric atopic dog.

REFERENCES

- Boothe DM, 2012. Factors affecting drug disposition. In: Small Animal Clinical Pharmacology and Therapeutics 2nd Ed, Elsevier Saunders, St. Louis, USA pp:34-7.
- Cosgrove SB, Cleaver DM, King VL, *et al.*, 2015. Long term compassionate use of oclacitinib in dogs with atopic dermatitis and allergic skin Disease: safety, efficacy and quality of life. *Vet Dermatol* 26:171-9.
- Cosgrove SB, Wren JA, Cleaver DM, *et al.*, 2013. Efficacy and safety of oclacitinib for the control of pruritus and associated skin lesions in dogs with canine allergic dermatitis. *Vet Dermatol* 24:479-87.
- Falk E and Ferrer L, 2015. Oclacitinib. www.clinicianbrief.com December 2015. pp:30-2.
- Favrot C, 2016. Diagnosis of canine atopic dermatitis. Proc "The 8th World Congress of Veterinary Dermatology", Bordeaux, France, 31 May – 4 June, 2016, pp:78-83.
- Favrot C, Steffan J, Seewald W, *et al.*, 2010. A prospective study on the clinical features of chronic canine atopic dermatitis and its diagnosis. *Vet Dermatol* 21:23-31.
- Gonzales AJ, Bowman JW, Gici GJ, *et al.*, 2014. Oclacitinib is a novel Janus kinase inhibitor with activity against cytokines involved in allergy. *J Vet Pharmacol Therap* 37:317-24.
- Hillier A, Lloyd DH, Weese JS, *et al.*, 2014. Guidelines for the diagnosis and antimicrobial therapy of canine superficial bacterial folliculitis. *Vet Dermatol* 25:163-75.
- Olivry T, DeBoer DJ, Favrot C, *et al.*, 2010. Treatment of canine atopic dermatitis: 2010 clinical practice guidelines from the International Task Force on Canine Atopic Dermatitis. *Vet Dermatol* 21:233-48.
- Plumb DC, 2015. Reference Laboratory Ranges. In: Plumb's Veterinary drug handbook 8th Ed, Blackwell, Ames, USA, pp:1250-1.