



CASE REPORT

Topical Chemotherapy Using Cisplatin for Treatment of Malignant Melanoma in a Grey Horse

Hyohoon Jeong¹ and Young Sam Kwon^{2,*}

¹Department of Equine Resources Science, School of Equine Science, Cheju Halla University, 38 Halladaehak-ro, Jeju 63092, Republic of Korea; ²Department of Veterinary Surgery, College of Veterinary Medicine, Kyungpook National University, 80 Daehakro, Daegu 41566, Republic of Korea

*Corresponding author: kwon@knu.ac.kr

ARTICLE HISTORY (19-149)

Received: April 04, 2019
Revised: April 29, 2019
Accepted: May 08, 2019
Published online: May 16, 2019

Key words:

Chemotherapy
Cisplatin
FNA
Grey horse
Malignant melanoma

ABSTRACT

A 7-year-old grey horse was referred to Kyungpook National University Veterinary Teaching Hospital due to two slowly growing pigmented masses located on her tail. At presentation, about 2 cm in diameter round dome-shaped masses with firm consistency were visualized and palpated one on the dorsal tail root on Co5 and the other on ventral proximal tail, between Co6 and Co7 area. A fine needle aspiration (FNA) biopsy confirmed malignant melanoma. A series of four topical chemotherapy with 2-week intervals was conducted using cisplatin in water-sesame seed oil emulsion. The tumor sites appeared healed with no signs of recurrence of tumor 6 weeks after completion of the treatment. To our knowledge, this is the first report of a treatment of the malignant melanoma using cisplatin in a horse in Republic of Korea.

©2019 PVJ. All rights reserved

To Cite This Article: Jeong H and Kwon YS, 2020. Topical chemotherapy using cisplatin for treatment of malignant melanoma in a grey horse. Pak Vet J, 40(1): 130-132. <http://dx.doi.org/10.29261/pakvetj/2019.072>

INTRODUCTION

Melanomas are cutaneous tumors that are common in horses with a prevalence of 4-15% (Johnson, 1998). Many reports have approximated that about 80% of aged grey horses will develop melanomas with the majority being benign (Valentine, 1995; Johnson, 1998). It has also been told that many of the histologically benign cutaneous melanomas may ultimately metastasize and therefore should be regarded potentially malignant (Valentine, 1995; Johnson, 1998). Even though the melanoma tumors do not show any clinical signs by themselves at the beginning, some serious consequences could occur once the tumors metastasize. For example, the tumors that are formed deeper within the internal body system of the patient in the abdomen or chest could interfere with normal function of the vital organs (Hablolvarid, 2018). The following report describes a case of malignant melanoma in a grey mare. To our knowledge, this is the first report of a treatment of the malignant melanoma in a horse in Republic of Korea.

Case history, examination and findings: A 7-year-old grey mare weighing 450 kg was referred to Kyungpook National University Veterinary Teaching Hospital for two slowly growing pigmented masses located on her tail with normal body temperature and pulse. At presentation,

two lumps, about 2 cm in diameter round dome-shaped, with firm consistency were visualized and palpated one on the dorsal tail root on Co5 and the other on ventral proximal tail, between Co6 and Co7 area. No heat or pain was present at palpation of the lumps. Complete Blood Count (CBC) and serum chemistry, auscultation, urinalysis and rectal examination were carried out at presentation. The CBC, serum chemistry and urinalysis values were in normal ranges (Table 1). There were no specific findings at auscultation. No masses were palpated in the rectum. A thorough dermatological examination showed no other skin lesions. The horse showed good appetite and normal performance at exercise suggesting that the patient was healthy other than the dermal lesions. A fine needle aspiration (FNA) biopsy utilizing 3 ml syringe with 23 G needle was conducted for diagnosis. Each lump was infiltrated with 5 ml of 2% lidocaine (Lidocaine Injection; Jeil Pharm. Co.) prior to FNA biopsy. The tumors were confirmed to be malignant melanoma based on the result of FNA biopsy. The FNA samples consisted of numerous erythrocytes, pleomorphic melanocytes with rare neutrophils and some epithelioid cells (Fig. 1). A standard treatment protocol consisting of a series of 4 intratumoral administrations of cisplatin at 2-week intervals was conducted (Théon, 1998). Cisplatin was formulated in 2:1 ratio of water-sesame oil (Sesame oil; Sigma-Aldrich) to deliver 3.3 mg

of cisplatin per milliliter of emulsion so the dosage was 1 mg of cisplatin for each cubic centimeter of tissue in target field (Théon, 1998). The patient was sedated with 40 µg/kg of detomidine (Provet Detomidine; Provet) and was pretreated with cefazolin (Cefazol; Eaglevet) and flunixin meglumine (Finadyne; MSD) for each treatment. Then the tumors were injected with cisplatin emulsion via 22 G needle cautiously. Topical antibiotic ointment consisting of bacitracin, neomycin and polymyxin B

(Banepo; Daihan Pharm. Co.) was applied on treated sites along with flunixin meglumine (Finadyne; MSD) injection to prevent infection and minimize discomfort for 5 days after each treatment. Acute skin reactions including inflammation, swelling and focal ulceration were observed after each chemotherapy but were self-limiting and resolved within 6 weeks of treatment without any scarring or hair loss with no gross evidence of recurrence of tumor (Fig. 2).

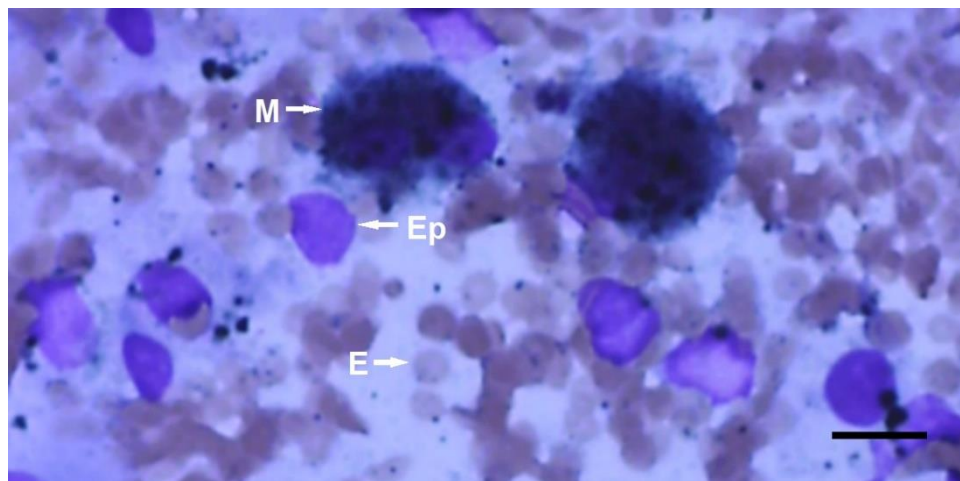


Fig. 1: Cytologic findings. A fine needle aspiration (FNA) biopsy sample was obtained from the round dome-shaped mass with a firm consistency located on the dorsal tail root of the patient. The FNA samples consisted of numerous erythrocytes (E), pleomorphic melanocytes (M) with rare neutrophils and some epithelioid cells (EP) thus confirmed that the tumor was malignant melanoma. Presence of numerous erythrocytes observed along with pleomorphic melanocytes in samples implied neovascularization with further possibility of metastasis of the tumor. Giemsa stain, Scale bar=100 µm.

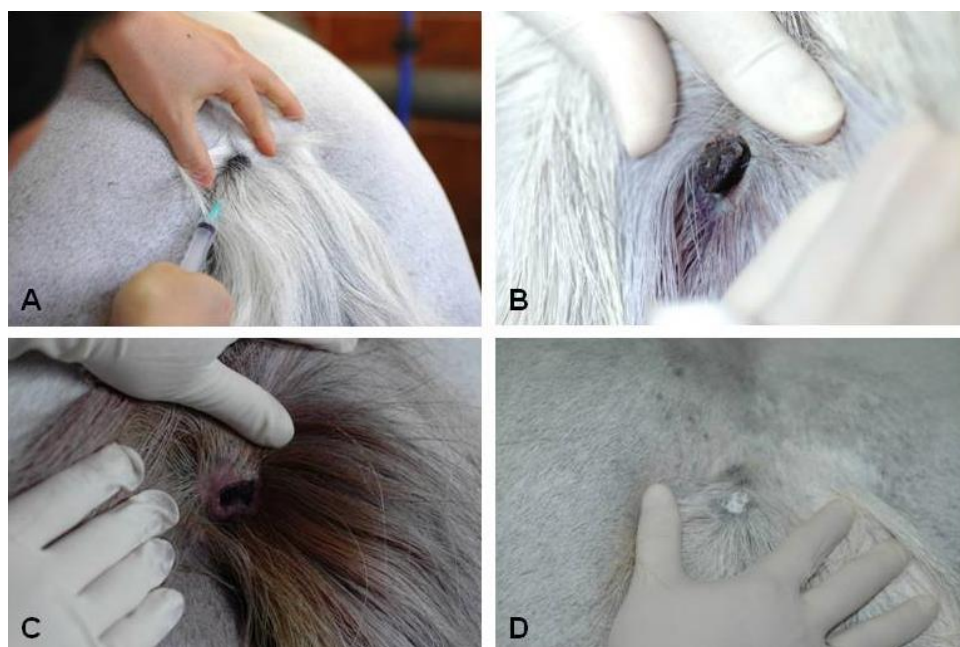


Fig. 2: A photograph taken before the treatment at the initial presentation (A). A photograph taken 2 weeks after the 3rd treatment (B). A photograph taken after 2 weeks of the completion of the chemotherapy. Note the ulcerated lesion after the crust detachment (C). A photograph taken after 6 weeks of the completion of the chemotherapy. Note that the lesion is completely healed (D).

Table 1: Hematological, biochemical parameters and urinalysis results at the initial presentation

Parameter	Normal Range	Value	Parameter	Normal Range	Value	Parameter	Normal Range	Value
Packed cell volume (%)	32-53	40.9	Alkaline phosphatase (IU/L)	138-251	234	Glucose (mg/dl)	75-115	87
Hemoglobin (g/dl)	11-19	15.6	Alanine aminotransferase (IU/L)	3-23	14	Potassium (mmol/L)	2.4-4.7	2.9
Leukocytes (10 ³ /µl)	5.4-14.3	7.58	Aspartate aminotransferase (IU/L)	226-336	315	Sodium (mmol/L)	132-146	139
Neutrophils (10 ³ /µl)	2.3-8.6	3.84	Blood urea nitrogen (mg/dl)	10-24	10.5	Total Protein (g/dL)	5.8-7.7	6.2
Lymphocytes (10 ³ /µl)	1.5-7.7	1.68	Calcium (mg/dL)	11.2-13.6	12.9	Urine specific gravity	1.020-1.050	1.030
Monocytes (/µl)	0-1000	136	Chloride (mmol/L)	99-109	100	Urine pH	7-8	7.5
Platelets (10 ³ /µl)	100-600	173	Carbondioxide (mmol/L)	24-32	31	Urine Protein	Negative-30	Negative
Albumin (g/dL)	2.7-4.2	3.4	Creatinine (mg/dl)	0.9-1.9	1.7	Urine Glucose	Negative	Negative

DISCUSSION

Melanin is an endogenous pigment produced by melanocytes in the basal layer of the skin. It is thought that an interruption in melanin metabolism and transfer related to progressive graying of the hair, owing to increasing age, results in intra-cellular deposition of melanin in grey horses. Surplus accumulation of the pigment in turn stimulates generation of new melanoblasts or elevated melanoblast activity resulting in focal areas of excessive production and neoplastic transformation of melanocytes (Patterson-Kane *et al.*, 2001). While melanomas can be found anywhere on the body of the horse, most tumors develop in the perineal and perianal regions, the ventral surface of the tail, the margin or outer part of the ear and external genitalia as seen in this case (Brown *et al.*, 2014).

Diagnosis of equine melanoma is relatively easy due to its typical location on the body and appearances whereas the differentiation of the benign from malignant tumors is not. Early diagnosis of malignant melanoma is essential due to the high incidence of malignancy (Valentine, 1995; Johnson, 1998). An FNA biopsy was thought to be an excellent diagnostic tool for differential diagnosis of malignant tumor from the benign tumor. Presence of numerous erythrocytes observed along with pleomorphic melanocytes in FNA samples implied neovascularization with further possibility of metastasis of the tumor.

Treatment options for skin melanomas include surgical removal, CO₂ laser excision and cryosurgery (Valentine, 1995; Théon, 1998; Groom and Sullins, 2018). Intratumoral chemotherapy with cisplatin also has been used for the treatment of the melanomas (Théon, 1998). Cimetidine has been described to have anti-neoplastic properties that may help survival in patients with cancer but the efficacy for equine melanoma is controversial (Adams and Morris, 1994; Théon, 1998). Current research is focusing on the development of immunotherapeutic measures including therapeutic vaccination therapies (Théon, 1998; Müller *et al.*, 2011; Brown *et al.*, 2014). The intralesional chemotherapy with cisplatin for equine dermal tumors has been developed with documented efficacy by Théon (1998). Cisplatin is a platinum-based chemotherapeutic drug which takes its action by crosslinking purine residues blocking cell division and augmenting oxidative stress inducing apoptosis (Khosla *et al.*, 2017). For this case, topical chemotherapy using cisplatin in water-oil emulsion was selected as the treatment of the tumors being the least invasive measure and the tumors were in early stage with no signs of metastasis. Intratumoral chemotherapy using cisplatin is

an approach that maximizes local delivery with least side effects to the normal tissues (Théon, 1998). Treatment was safe and resulted in excellent cosmetic and functional results. Drug-related systemic toxicity was not observed in this case. Treatment related skin reactions were minimal and resolved promptly with no evidence of cosmetic or functional deficit. The results suggest that intratumoral chemotherapy with cisplatin is a good therapeutic measure for melanoma in horses compared to other available treatment options especially for the veterinarians in field.

Dermatological tumors located on the tail in a grey mare were diagnosed as malignant melanoma based on the clinical signs and FNA biopsy results. A series of four topical chemotherapy with 2-week intervals using cisplatin in water-sesame seed oil emulsion was effective for the treatment of melanoma without any systemic toxicity with no signs of recurrence of the tumor. Topical chemotherapy using cisplatin may be considered and used for the treatment of malignant melanoma in horses by veterinarians in field.

Authors contribution: HJ and YK conceived and designed the study. HJ and YK equally contributed in writing the manuscript and critically revised the manuscript for important intellectual contents and approved the final version.

REFERENCES

- Adams W and Morris D, 1994. Short-course cimetidine and survival with colorectal cancer. *Lancet* 344:1768-9.
- Brown EL, Ramiya VK, Wright CA, *et al.*, 2014. Treatment of metastatic equine melanoma with a plasmid DNA vaccine encoding *Streptococcus Pyogenes* EMM55 protein. *J Equine Vet Sci* 34:704-8.
- Groom LM and Sullins KE, 2018. Surgical excision of large melanocytic tumors in grey horses: 38 cases (2001-2013). *Equine Vet Educ* 30:438-43.
- Hablovarid MH, 2018. Unilateral malignant melanoma of the adrenal gland with metastatic spread to the thorax in a horse. *Equine Vet Educ* <https://doi.org/10.1111/eve.12919>.
- Johnson PJ, 1998. Dermatologic tumors (Excluding Sarcoids). *Vet Clin North Am Equine Pract* 14:625-58.
- Khosla S, Kennedy L and Abdulaal Y, 2017. Cisplatin induced acute mesenteric ischaemia: A case report and review of the literature. *Int J Surg Case Rep* 41:347-51.
- Müller JMV, Feige K, Wunderlin P, *et al.*, 2011. Double-blind placebo-controlled study with interleukin-18 and interleukin-12-encoding plasmid DNA shows antitumor effect in metastatic melanoma in grey horses. *J Immunother* 34:58-64.
- Patterson-Kane JC, Sanchez LC, Uhl EW *et al.*, 2001. Disseminated metastatic intramedullary melanoma in an aged grey horse. *J Comp Pathol* 125:204-7.
- Théon AP, 1998. Intralesional and topical chemotherapy and immunotherapy. *Vet Clin North Am Equine Pract* 14:659-71.
- Valentine BA, 1995. Equine melanocytic tumors: a retrospective study of 53 horses (1988 to 1991). *J Vet Intern Med* 9:291-7.