



## RESEARCH ARTICLE

### Dose and Time-Related Pathological and Genotoxic Studies on Thiamethoxam in Fresh Water Fish (*Labeo rohita*) in Pakistan

Abdul Ghaffar<sup>1</sup>, Riaz Hussain<sup>2\*\*</sup>, Sobia Noreen<sup>1</sup>, Ghulam Abbas<sup>3</sup>, Iqra Rasheed Chodhary<sup>1</sup>, Ahrar Khan<sup>4,5\*</sup>, Zulfiqar Ahmed<sup>6</sup>, Muhammad Kasib Khan<sup>5</sup>, Kashfa Akram<sup>1</sup>, Mazhar Ulhaq<sup>7</sup>, Noman Ahmad<sup>1</sup>, Farah Ali<sup>2</sup> and Maria Niaz<sup>1</sup>

<sup>1</sup>Department of Zoology; <sup>2</sup>University College of Veterinary and Animal Sciences, The Islamia University of Bahawalpur, Bahawalpur-63100, Pakistan; <sup>3</sup>Centre of Excellence in Marine Biology, University of Karachi, Karachi-75270, Pakistan; <sup>4</sup>Shandong Vocational Animal Science and Veterinary College, Weifang, 261061, China; <sup>5</sup>Faculty of Veterinary Science, University of Agriculture, Faisalabad, Pakistan; <sup>6</sup>Department of Food Science and Technology, College of Agriculture and Environmental Sciences, The Islamia University of Bahawalpur, Bahawalpur-63100, Pakistan; <sup>7</sup>Department of Veterinary Biomedicine, Faculty of Veterinary and Animal Sciences, PMAS Arid Agriculture University, Rawalpindi-46300, Pakistan

\*Corresponding authors: ahrar1122@yahoo.com (AK)\*; driazhussain@yahoo.com (RH)\*\*

#### ARTICLE HISTORY (19-294)

Received: July 17, 2019  
Revised: December 01, 2019  
Accepted: December 02, 2019  
Published online: January 07, 2020

#### Key words:

Genotoxicity  
Hematology  
Histopathology  
*Labeo rohita*  
Thiamethoxam

#### ABSTRACT

A total of 60 fresh-water fish were obtained from a local fish breeding center and carefully transported in plastic bags having adequate amount of oxygen and water. After 7 days of acclimatization, all the fish were randomly divided and kept in five equal groups (A-E). The experimental fish were exposed to various concentrations (0, 0.5, 1.0, 1.5 and 2.0 mg/L) of thiamethoxam for a period of 120 h. Blood and other tissue samples of each treated fish were collected after 72, 96 and 120 h. Various physical responses like operculum and bouncing movement, mucus secretion, darkening of fins, fin tremors, swimming in isolation on one side, surface breathing and erratic swimming were observed in fish treated with higher concentrations. Results indicated that the values of red blood cell counts (RBCs), packed cell volume (PCV) and hemoglobin (Hb) concentrations were significantly lower and white blood cell (WBCs) and neutrophil counts increased significantly in thiamethoxam treated fish as compared to unexposed fish. The frequency of various nuclear (micronuclei, erythrocytes with nuclear remnant, erythrocytes with condensed nuclei and erythrocytes without nucleus) and morphological changes (leptocytes, stomatocytes, dividing erythrocytes and tear shape erythrocyte) in treated fish was significantly higher as compared to control group. Microscopic analysis of gills tissues of various experimental fish exhibited atrophy of secondary lamellae, pyknosis of lamellar epithelial pillar cells, lamellar degeneration, congestion, aneurysm and curling of lamellae.

©2019 PVJ. All rights reserved

**To Cite This Article:** Ghaffar A, Hussain R, Noreen S, Abbas G, Chodhary IR, Khan A, Ahmed Z, Khan MK, Akram K, Ulhaq M, Ahmad N, Ali F and Niaz M, 2020. Dose and time-related pathological and genotoxic studies on thiamethoxam in fresh water fish (*Labeo rohita*) in Pakistan. Pak Vet J, 40(2): 151-156. <http://dx.doi.org/10.29261/pakvetj/2020.002>

#### INTRODUCTION

Contamination with poisonous compounds such as pesticides, trace metal, heavy metals, polycyclic aromatic hydrocarbons and polycyclic aliphatic hydrocarbons and numerous other effluents causes varieties of adverse impacts on living organisms leading to considerable population damage. The development and advancement in technology, industries and common use of numerous synthetic and natural compounds have led to contamination of aquatic ecosystems (Ghaffar *et al.*, 2015a; Ghaffar *et al.*, 2016; Ghaffar *et al.*, 2018a).

Among different synthetic compounds, pesticides are extensively and frequently used in modern agriculture, public health and veterinary practice to remove insects (Hussain *et al.*, 2014; Ali *et al.*, 2020). The pesticides cause harmful and deleterious effects on both terrestrial and aquatic ecosystems (Hussain *et al.*, 2015; Gul *et al.*, 2017; Hussain *et al.*, 2019). Agricultural and industrial routes are continuously releasing their toxic chemicals as waste products which not only contaminate the aquatic biota but also cause numerous tissue changes in variety of exposed organisms (Witeska *et al.*, 2014; Qureshi *et al.*, 2016; Ghaffar *et al.*, 2018b). Thiamethoxam being a

neonicotinoid insecticide is frequently used in agriculture to protect variety of food crops including cotton fields and paddy fields to control pests (whiteflies, aphids and leafhoppers (Gul *et al.*, 2017). Neonicotinoid insecticides (thiamethoxam) obstruct the acetylcholine receptors, therefore disturbing the central nervous system activities leading to death of insects (Green *et al.*, 2005; Shalabey *et al.*, 2010). Recent studies have indicated that among different neonicotinoids, the thiamethoxam is widely used due to its selectivity (Al-Kherb, 2011) against different pests across the globe and affects development, reproductive system and immunity by causing morphological, pathological and physiological changes in non-target organisms (Mason *et al.*, 2013; Thaker, 2014; Ugurlu *et al.*, 2015). Different environmental pollutants particularly pesticides/heavy metal have been linked to cause adverse effects such as apoptosis, poor fertilization, abnormal spermatogenesis, DNA fragmentation, mitochondrial dysfunctions through ROS-scavenging antioxidants depletion in various target and non-target organisms ranging from aquatic life to humans (Khan *et al.*, 2015; Ghaffar *et al.*, 2017a). Aquatic ecosystems are the ultimate basins for agricultural residues as well industrial pollutants (Gupta *et al.*, 2014). Among all aquatic animals, fish are sensitive to water pollution. In fish, different toxicants are mainly absorbed through the gills, skin or alimentary duct and diffuse into different tissues resulting to disruption of physiological and biochemical processes (Qureshi *et al.*, 2016; Ghaffar *et al.*, 2019). It is reported that the sub lethal concentrations of pesticides in aquatic environment induces abnormal metabolisms and changes in behavior and death of aquatic organisms. Monitoring and determination of different adverse effects particularly genotoxicity of pesticides in exposed and non-target species is sensitive and reliable end point (Khan *et al.*, 2015; Ghaffar *et al.*, 2016). Different important biomarkers attract huge attention in screenings of various compounds in environmental studies as a sensitive tool for evaluation and detection of effects of pollutants from natural and anthropogenic sources (Kostić *et al.*, 2017). Therefore, this study aimed at to investigate the effects of thiamethoxam considering DNA damage and histopathological examination of gills as sensitive biomarkers in fresh-water fish.

## MATERIALS AND METHODS

**Experimental fish and management:** The experimental research was planned and conducted at laboratories of Department of Life Sciences (Toxicology and aquaculture laboratory) and Veterinary Sciences (Pathology), Islamia University of Bahawalpur. A total of 60 fresh-water fish were purchased from local fish breeding center Hasilpur. All the experimental fish were carefully transported in plastic bags having adequate amount of oxygen and water. The fish were kept in glass aquaria and handled according to guidelines of Scientific Ethic Committee of Islamia University of Bahawalpur.

Apparently healthy and active fish (n=60) of same weight, age and size were kept in glass aquaria about 64×32×34 cm containing 100 L water capacity and equipped with oxygenators. All the fish were left to acclimatize for 7 days. After seven days of acclimatization the experimental fish were randomly separated into five

groups A, B, C, D and E. Fish present in group served as control group. Different doses of thiamethoxam were given to all remaining groups. All the experimental test specimens in various groups were exposed to different concentrations (0.5, 1.0, 1.5 and 2.0 mg/L) of thiamethoxam were to groups (B, C, D and E) respectively for a period of 120 h. Clinical signs, behavioral changes and mortality were monitored throughout the experiment.

**Hematobiochemical parameters:** Blood samples with and without anticoagulant were collected after 72, 96 and 120 h of treatments from caudal vein by using 26-gauge hypodermic needle. For morphological and nuclear changes in erythrocyte of exposed fish a fine thin blood smear on microscopic slide was prepared from fresh blood of each fish separately. All the blood smears were fixed with absolute alcohol and stained with Giemsa solution. After that they were examined under microscope and photographed. Blood with anticoagulant was processed for hematology. About 5 ml of blood was collected in the clean glass test tube with an anticoagulant. All the collected blood samples were used to determine total red blood cell counts, total and differential leukocyte counts and packed cell volume (Ghaffar *et al.*, 2016).

**Histopathology:** For histopathological changes, gills were quickly removed from fish, rinsed in isotonic saline solution and fixed in 10% neutral buffered formaldehyde (pH 7.2) solution. After fixation, tissues were dehydrated in ascending series of alcoholic solutions and embedded in paraffin wax. Sections of 4-5µm thickness were cut on a rotary microtome (Shandon Finesse, Italy) and dried on a slide warmer at 37°C. The tissues were deparaffinized in xylene and dehydrated in ascending series of alcohol. Sections were stained with standard hematoxylin and eosin (H&E) method. Sections were finally cleared in xylene and mounted in DPX mountant medium. Multiple sections of each test specimen were observed under a light microscope (Leica, Germany).

**Statistical analysis:** Data obtained in this experiment were subjected to statistical analysis (SAS, 2004). Mean ± SE values for hematological and nuclear changes indifferent treatment groups were compared by Tukey's test. Significant difference was accepted at P<0.05 in all cases.

## RESULTS

**Physical and blood biochemical responses:** No mortality and behavioral abnormalities were recorded in untreated fish. Fish received higher concentrations of thiamethoxam showed different physical responses like bouncing movement, darkening of fins, fin tremors, swimming on one side, operculum movement, mucus secretion and surface breathing. Bouncing movement, swimming in isolation and erratic swimming were the characteristic clinical features examined in fish treated with higher concentrations pesticide (1.5, 2.0 mg/L). The results on different blood parameters indicate that the values of red blood cell counts (RBCs) were significantly decreased in pesticide treated fish after 96 and 120 h in groups D and F as compared to unexposed fish (Table 1). The packed cell volume (PCV) and hemoglobin (Hb)

concentrations decreased significantly in group F after 96 h while in groups D and F after 120 h when compared to non-treated fish. The white blood cell (WBCs) and neutrophil counts increased significantly in fish of group F after 72 h while in groups D-F after 96 and 120 h of treatment. The lymphocyte population decreased significantly in fish of group F after 72 and 96 h while in groups D-F after 120 h of treatment as compared to non-treated fish. The monocyte population decreased significantly after 96 h of treatment in fish of group F and in groups E-F after 120 h when compared to non-treated fish.

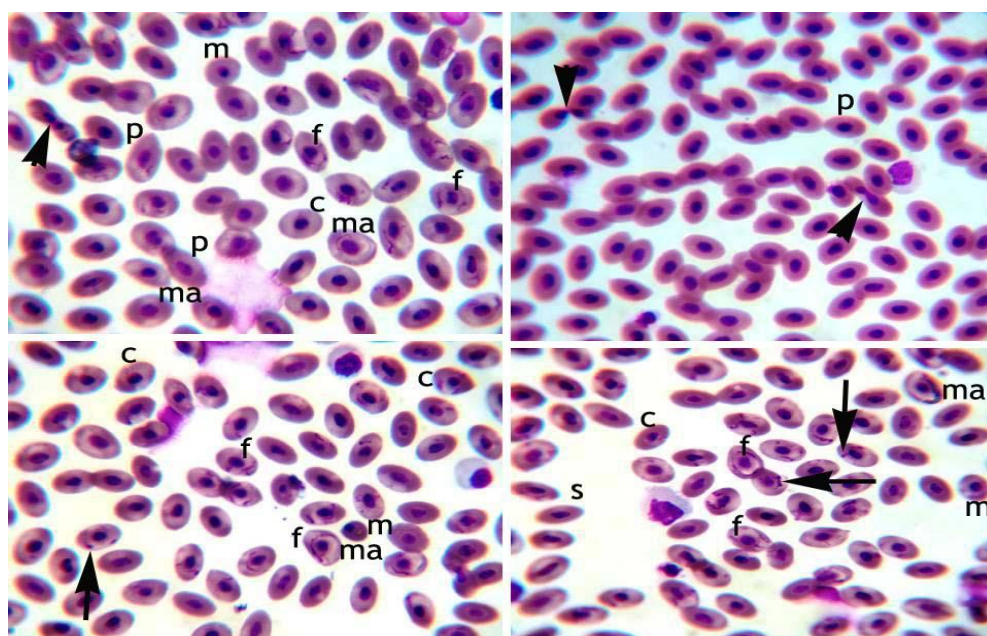
**Genotoxic and morphological changes:** The frequency of DNA damage (micronuclei) and different nuclear abnormalities in erythrocyte of pesticide-treated fish is presented in Table 2. Results indicate that the rate of micronuclei, erythrocytes with nuclear remnant and erythrocytes without nucleus increased significantly in group F after 72 and in groups E-F after 96 and 120 h of treatment (Fig.1). The rate of notched nuclei increased significantly in groups E-F throughout the experimental when compared to untreated fish. The rate of condensed nuclei was significantly higher in fish of groups E-F after 72 and 96 h while in groups D-F after 120 h of treatment. The frequency of vacuolated erythrocyte, leptocytes and tear shape erythrocyte was significantly higher in fish of group F after 72 h while in groups E-F after 96 h and in groups D-F after 120 h of treatment as compared to non-treated fish (Table 3). The frequency of stomatocytes and dividing erythrocytes increased significantly in fish of group F after 72 h while in groups E-F after 96 and 120 h of treatment.

**Histopathological changes in gills:** Histological examination of gill tissue of control fish showed normal arrangements of primary and secondary lamellae (Fig. 2). Gill tissues in treated fish in groups (D and E) after 96 h of treatment presented prominent histopathological changes including atrophy of secondary lamellae, pyknosis of lamellar epithelial pillar cells, disruption and

disorganization of primary and secondary lamellae, lamellar degeneration, congestion, aneurysm and curling of secondary lamellae. Moderate histopathological changes like degeneration, curling and sloughing of lamellar epithelium were observed in gill tissues of fish of group C after 120 h of exposure.

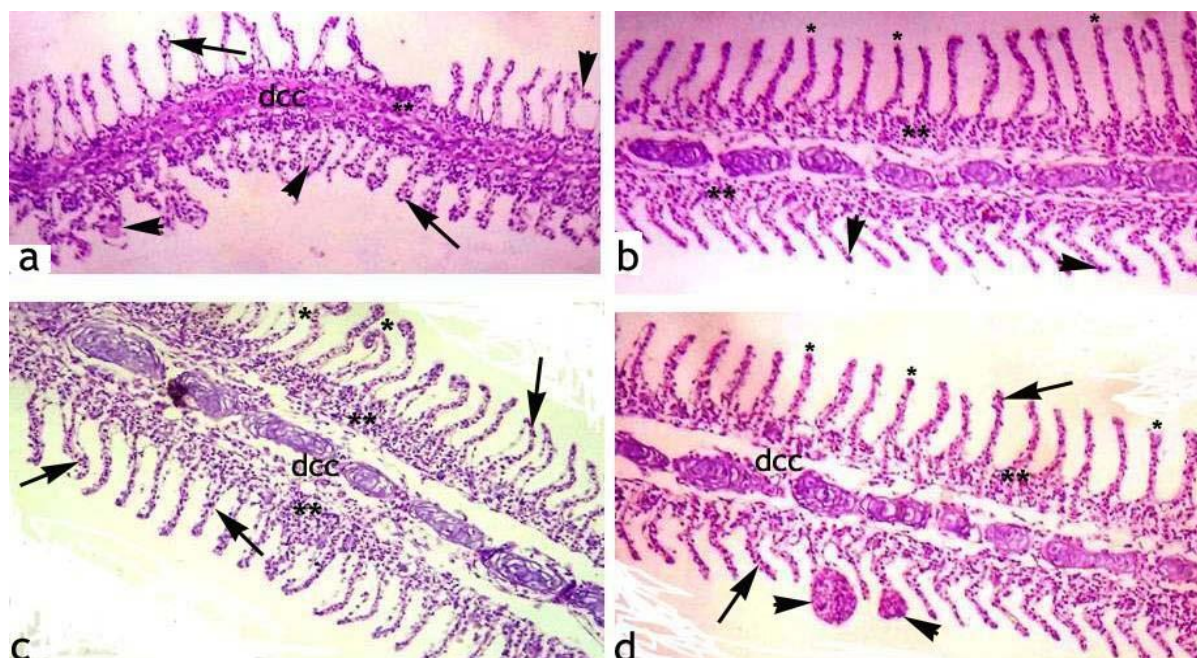
## DISCUSSION

Although no mortality was recorded in treated fish in all experimental groups but exposure of thiamethoxam induced different behavioral changes viz., bouncing movement, erratic swimming, darkening of fins, fin tremors, swimming on one side, operculum movement, increased mucus secretion and swimming in isolation. The clinical and behavioral changes in thiamethoxam treated fish might be due to toxic effects. Previous no report could be found in published literature about the clinical signs and behavioral changes in thiamethoxam treated fish. However, it is reported that neonicotinoids pesticides cause poor growth in both in fry in and adult fish (Hayasaka *et al.*, 2012; Gibbons *et al.*, 2014). Clinical signs like operculum and bouncing movement could be due to inhibition of acetylcholinesterase in treated fish. Previously it is well known that thiamethoxam lowers the activity of acetylcholinesterase and causes adverse consequences in fresh-water fish (Clasen *et al.*, 2018). Moreover, different adverse effects including behavioral disorders in offspring of rats (Gu *et al.*, 2013) and incoordination, reduced movement, cessation of feeding and chick developmental abnormalities in birds have also been reported due to neonicotinoid pesticides such as imidacloprid and fipronil pesticides (Gibbons *et al.*, 2014). In current experimental study, all the hematological changes in treated fish occurred in dose depended mode. Significant decrease in red blood cell counts, hematocrit, hemoglobin concentration, monocyte and lymphocyte while increased values of white blood cell count and neutrophil were observed treated fish. It is reported that the monitoring of functions of hematopoietic



**Fig. 1:** Blood smear of fresh-water fish (*Labeo rohita*) exposed to different concentrations of thiamethoxam (mg/L) 1.15 and 2.0) after 96 and 120 h of experiment exhibiting different nuclear and morphological changes in erythrocytes, i.e., microcytes (m), macrocytes (ma), pear shaped erythrocytes (p), spindle shaped erythrocytes (s), dividing erythrocytes (arrow-heads), erythrocytes with condensed nucleus (c), erythrocyte with micronucleus (arrows) and erythrocyte with fragmented/nuclear remnants (f). Giemsa Stain; X1000.





**Fig. 2:** Photomicrograph of fresh-water fish (*Labeo rohita*) exposed to different concentrations of thiamethoxam (mg/L) (1.15 and 2.0) after 96 and 120 h of experiment exhibiting different histopathological alterations in gills. a) showing dis-organization and disruption of cartilaginous cores (dcc), necrosis of lamellar epithelial cells secondary lamellae (arrows), disorganization of primary lamellae (\*\*), and sloughing of lamellar epithelium (arrow-heads). b) uplifting of secondary lamellae (\*), disruption and disorganization of primary lamellae (\*\*), necrosis of lamellar epithelial cells (arrow-heads). c) curling of secondary lamellae (\*), necrosis and disruption of primary lamellae (\*\*), necrosis of secondary lamellar epithelial cells (arrows) and disruption and disorganization of cartilaginous cores (dcc). d) uplifting of secondary lamellae (\*), sloughing and necrosis of secondary lamellar epithelium (arrows), disorganization and disruption of cartilaginous cores (dcc) and telangiectasis of secondary lamellae (arrow-heads). H & E Stain; X100.

**Table 1:** Effect of Thiamethoxam on some hematological parameters of fresh-water fish *Labeo rohita*

Parameters	Thiamethoxam (mg/L)				
	A (0.0)	B (0.5)	C (1.0)	D (1.5)	E (2.0)
Red blood cells count ( $10^3/\mu\text{L}$ )					
72	3.98±0.05	4.01±0.01	3.97±0.02	3.93±0.01	3.79±0.14
96	4.09±0.03	4.06±0.03	3.79±0.16	3.15±0.11*	3.14±0.01*
120	4.11±0.04	4.01±0.04	3.68±0.04	3.04±0.01*	2.91±0.12*
Hemoglobin (gm/dl)					
72	7.55±0.01	7.38±0.02	6.64±0.01	6.17±0.04	5.99±0.03
96	7.55±0.01	7.38±0.01	6.64±0.11	6.17±0.03	5.33±0.10*
120	7.55±0.02	7.17±0.04	6.17±0.03	5.42±0.07*	5.01±0.03*
Pack cell volume (%)					
72	30.51±0.19	30.34±0.06	30.24±0.05	30.09±0.01	28.67±0.21
96	30.46±0.22	30.27±0.04	29.23±0.01	28.67±0.21	24.22±0.12*
120	33.08±2.31	29.23±0.01	28.67±0.21	24.61±0.20*	22.67±0.12*
White Blood Cells counts ( $10^3/\mu\text{L}$ )					
72	20.71±0.04	20.86±0.06	20.96±0.01	21.40±0.19	25.06±0.06*
96	20.75±0.02	21.25±0.02	21.90±0.69	25.06±0.06*	28.62±0.20*
120	20.65±0.06	21.23±0.03	25.06±0.06*	25.95±0.1*	29.52±0.06*
Neutrophils (%)					
72	15.19±0.22	15.60±0.02	16.41±0.18	16.53±0.08	20.56±0.22*
96	15.12±0.26	16.47±0.20	19.15±0.25	20.56±0.22*	25.10±0.80*
120	14.99±0.19	16.44±0.20	20.36±0.22*	21.40±0.07*	25.06±0.16*
Lymphocytes (%)					
72	22.19±0.08	22.03±0.02	21.45±0.42	20.24±0.15	16.25±0.08*
96	22.16±0.07	21.85±0.22	20.47±0.07	19.30±0.23	16.25±0.08*
120	22.10±0.08	21.61±0.21	19.30±0.23	16.27±0.08*	16.05±0.18*
Monocytes (%)					
72	4.31±0.01	4.14±0.01	4.06±0.02	4.02±0.01	3.71±0.07
96	4.30±0.01	4.09±0.03	4.00±0.01	3.92±0.02	3.03±0.06*
120	4.28±0.01	4.10±0.04	4.03±0.02	3.09±0.05*	2.93±0.12*

The values with asterisk (mean±SE) in the rows differ significantly ( $P\leq 0.05$ ) from control group.

organs and different blood parameters are important and considered as the biomarkers for screening of different toxicants and determination of pathophysiological status of organisms exposed organisms (Roy and Nath, 2011; Ghaffar *et al.*, 2016). The significant decreased red blood cell counts and hemoglobin levels in thiamethoxam treated fish could be due to poor efficiency of fresh-water

fish to deliver enough oxygen to blood forming tissues (Hussain *et al.*, 2014; Ghaffar *et al.*, 2017b). Furthermore, lower values of red blood cell and hemoglobin levels can also be due to fatigue metabolic activities and inefficiency of hemopoietic tissues in pesticide treated fish (Ghaffar *et al.*, 2015b). Previously, significantly reduced hematological values in thiamethoxam treated birds (Gul

**Table 2:** Effect of Thiamethoxam on frequency of different nuclear changes (%) in erythrocytes of *Labeo rohita*

Parameter/HRS	Thiamethoxam (mg/L)				
	A (0.0)	B (0.5)	C (1.0)	D (1.5)	E (2.0)
Micro nucleus (%)					
72	0.32±0.03	0.34±0.02	0.35±0.01	0.37±0.01	1.31±0.02*
96	0.33±0.02	0.35±0.01	0.37±0.01	0.38±0.02*	1.49±0.02*
120	0.34±0.01	0.36±0.02	0.37±0.03	1.33±0.04*	2.42±0.02*
Erythrocytes with Nuclear Remnant (%)					
72	0.32±0.02	0.34±0.02	0.36±0.01	0.38±0.02	0.75±0.01*
96	0.33±0.02	0.35±0.01	0.37±0.02	0.83±0.01*	1.16±0.02*
120	0.32±0.03	0.35±0.02	0.77±0.01*	1.19±0.02*	1.82±0.01*
Blebbled Nucleus in erythrocytes (%)					
72	0.16±0.01	0.17±0.02	0.18±0.01	0.19±0.03	1.14±0.04*
96	0.17±0.01	0.18±0.02	0.22±0.01	1.09±0.04*	2.15±0.07*
120	0.18±0.01	0.21±0.02	0.21±0.02*	1.96±0.02*	2.22±0.04*
Erythrocytes Without Nucleus (%)					
72	0.19±0.01	0.19±0.01	0.22±0.02	0.22±0.01	0.74±0.01*
96	0.20±0.02	0.22±0.02	0.23±0.01	0.25±0.01	1.39±0.02*
120	0.19±0.02	0.23±0.01	0.23±0.01	1.69±0.01*	1.87±0.01*
Notched Nucleus (%)					
72	0.24±0.03	0.26±0.02	0.27±0.02	0.97±0.01*	1.32±0.01*
96	0.25±0.02	0.27±0.01	0.28±0.01	1.30±0.02*	1.98±0.01*
120	0.26±0.02	0.28±0.02	0.29±0.01	1.95±0.02*	2.41±0.01*
Condensed Nucleus (%)					
72	0.13±0.01	0.13±0.02	0.14±0.01	0.72±0.02*	0.97±0.01*
96	0.14±0.02	0.15±0.01	0.18±0.02	0.89±0.01*	1.23±0.02*
120	0.12±0.03	0.14±0.02	0.91±0.01*	1.94±0.01*	2.12±0.02*

The values with asterisk (mean ±SE) in the rows differ significantly ( $P<0.05$ ) from control group. HRS=High Resolution Scenarios.

**Table 3:** Effect of Thiamethoxam on frequency of different morphological changes (%) in erythrocytes of *Labeo rohita*

Parameters/HRS	Thiamethoxam (mg/L)				
	A (0.0)	B (0.5)	C (1.0)	D (1.5)	E (2.0)
Vacuolated nucleus in Erythrocytes (%)					
72	0.42±0.03	0.44±0.01	0.45±0.01	0.96±0.02	1.12±0.01*
96	0.43±0.02	0.45±0.02	0.46±0.01	1.26±0.02*	1.71±0.01*
120	0.43±0.03	0.45±0.01	0.86±0.02*	2.17±0.01*	2.47±0.02*
Leptocytes (%)					
72	0.15±0.01	0.15±0.01	0.15±0.01	0.16±0.02	0.30±0.01*
96	0.14±0.01	0.16±0.02	0.16±0.01	0.19±0.02	0.29±0.01*
120	0.14±0.02	0.15±0.02	0.32±0.01*	0.33±0.01*	0.37±0.02*
Stomatocytes (%)					
72	0.21±0.02	0.22±0.02	0.20±0.01	0.23±0.02	0.98±0.01*
96	0.22±0.02	0.23±0.02	0.23±0.01	0.88±0.01*	1.40±0.02*
120	0.21±0.03	0.23±0.01	0.25±0.01	0.95±0.02*	1.84±0.01*
Dividing erythrocytes (%)					
72	0.26±0.03	0.27±0.02	0.29±0.01	0.59±0.03	0.84±0.02*
96	0.28±0.02	0.29±0.01	0.31±0.02	0.84±0.01*	0.97±0.02*
120	0.29±0.02	0.30±0.01	0.32±0.01	1.38±0.02*	1.45±0.02*
Tear shape erythrocyte (%)					
72	0.17±0.02	0.19±0.01	0.21±0.01	0.23±0.02	0.84±0.01*
96	0.19±0.01	0.21±0.02	0.23±0.02	0.74±0.01*	0.95±0.02*
120	0.18±0.03	0.22±0.01	0.83±0.01*	1.04±0.02*	1.50±0.01*

The values with asterisk (mean ±SE) in the rows differ significantly ( $P<0.05$ ) from control group. HRS=High Resolution Scenarios.

*et al.*, 2017) and *Oreochromis niloticus* (Trewavas) have also been reported (Roy and Nath, 2011). The lower values of red blood cell count and hemoglobin concentrations might also be due to insufficient exchange of gasses by gills (Osman *et al.*, 2009). The significant increased white blood cell counts and lower values of monocyte and lymphocyte population in treated fish could be due to injurious stimulation of thiamethoxam and the sensitivity of immune system.

Different nuclear (micro nuclei, erythrocytes with nuclear remnants, erythrocyte with blebbed nuclei, erythrocytes without nucleus, notched nucleus, condensed nuclei) and morphological (vacuolated erythrocytes, leptocytes, stomatocytes, dividing erythrocytes, tear shape erythrocyte) abnormalities in erythrocytes of thiamethoxam treated fish were observed. Previously, in published literature no report is available about the nuclear and morphological changes in fresh-water fish exposed to thiamethoxam. The nuclear changes in erythrocyte might be due to increased induction of

oxidative stress and caspase-activated DNase activation leading to mitochondrial damage (Campos-Pereira *et al.*, 2012; Yan *et al.*, 2016; Ghaffar *et al.*, 2018a; Hussain *et al.*, 2018). Previously, different studies have reported nuclear and morphological alterations like micronuclei, nuclear condensation, erythrocyte swelling, lobed nuclei, irregular shape of nucleus and deterioration of cell membrane due to different toxicants in exposed species including fish (Strunjak-Perovic *et al.*, 2010; Gibbons *et al.*, 2014; Ghaffar *et al.*, 2015b; Ghaffar *et al.*, 2018b). Moreover, various morphological changes in erythrocyte of treated fish can be due to higher erythropoiesis to compensate the impaired functions and lipid per oxidation (Witeska *et al.*, 2014; Gibbons *et al.*, 2014). Increased DNA breaks in birds due to pesticide has also been reported (Tokumoto *et al.*, 2013). Histologically, gills sections from treated fish exhibited atrophy of secondary lamellae, pyknosis of lamellar epithelial pillar cells, disruption and disorganization of primary and secondary lamellae, lamellar degeneration, congestion, aneurysm

and curling of secondary lamellae. The histological changes in gills of exposed fish could be due to increased lipid peroxidation, catalase activity and glutathione S-transferase levels gills (Yan *et al.*, 2016). Previously, increased protein oxidation, vacuolization and hemostatic infiltration in gills of *Gammarus kischineffensis* and zebrafish exposed to thiamethoxam has been reported (Ugurlu *et al.*, 2015; Clasen *et al.*, 2018).

**Conclusions:** Based on results of current experimental study, it can be concluded that thiamethoxam even at relevant environmental concentrations causes hematological, genotoxic and histopathological changes in fresh-water fish in a time and dose related manner.

**Authors contribution:** RH, AG, SN, AK, MKK and IRC planned and executed the research. AG, RH, GA, FA and KA were involved in statistical analysis. RH, MU, ZA and NA prepared the manuscript.

## REFERENCES

- Ali A, Khatoon A, Abidin ZU, *et al.*, 2020. The adverse effects of carbofuran are efficiently counteracted by the supplementation of star anise (*Illicium verum*) in broiler chicks, Toxin Reviews DOI: 10.1080/15569543.2020.1749082
- Campos-Pereira FD, Camila AO, Acacio AP, *et al.*, 2012. Early cytotoxic and genotoxic effects of atrazine on Wistar rat liver: a morphological immunohistochemical, biochemical, and molecular study. *Ecotoxicol Environ Saf* 78:170-7.
- Clasen B, Loro VL, Murussi CR, *et al.*, 2018. Bioaccumulation and oxidative stress caused by pesticides in *Cyprinus carpio* reared in a rice-fish system. *Sci Total Environ* 19:737-43.
- Ghaffar A, Hussain R, Abbas G, *et al.*, 2017a. Cumulative effects of sodium arsenate and diammonium phosphate on growth performance, hemato-biochemistry and protoplasm in commercial layer. *Pak Vet J* 37:257-62.
- Ghaffar A, Hussain R, Abbas G, *et al.*, 2017b. Arsenic and copper sulfate in combination causes testicular and serum biochemical changes in White Leghorn cockerels. *Pak Vet J* 37:375-80.
- Ghaffar A, Hussain R, Abbas G, *et al.*, 2018b. Sodium arsenate and/or urea differently affect clinical attributes, hemato-biochemistry and DNA damage in intoxicated commercial layer birds. *Toxin Rev* 37:206-15
- Ghaffar A, Hussain R, Abbas G, *et al.*, 2018a. Fipronil (Phenylpyrazole) induces hemato-biochemical, histological and genetic damage at low doses in common carp, *Cyprinus carpio* (Linnaeus, 1758). *Ecotoxicology* 27:1261-71
- Ghaffar A, Hussain R, Abbas G, *et al.*, 2019. Assessment of genotoxic and pathologic potentials of fipronil insecticide in *Labeo rohita* (Hamilton, 1822), *Toxin Rev* DOI: 10.1080/15569543.2019.1684321.
- Ghaffar A, Hussain R, Aslam M, *et al.*, 2016. Arsenic and Urea in Combination Alters the Hematology, Biochemistry and Protoplasm in Exposed Rahu Fish (*Labeorohita*) (Hamilton, 1822). *Turk Fish Aquat Sci* 16:289-96.
- Ghaffar A, Hussain R, Khan A, *et al.*, 2015a. Butachlor induced clinicohematological and cellular changes in fresh water fish *Labeorohita* (Rohu). *Pak Vet J* 35:201-6.
- Ghaffar A, Hussain R, Khan A, *et al.*, 2015b. Hemato-biochemical and genetic damage caused by triazophos in fresh Water fish *Labeorohita*. *Int J Agric Biol* 17:637-42.
- Gibbons D, Morrissey C and Mineau P, *et al.*, 2014. A review of the direct and indirect effects of neonicotinoids and fipronil on vertebrate wildlife. *Environ Sci Pollut Res* 22:103-18.
- Green T, Toghil A, Lee R, *et al.*, 2005. Thiamethoxam induced mouse liver tumors and their relevance to human's part I, mode of action studies in the mouse. *Toxicol Sci* 86:36-47.
- Gu YH, Li Y, Huang XF, *et al.*, 2013. Reproductive effects of two neonicotinoid insecticides on mouse sperm function and early embryonic development in vitro. *PLoS One* 8:e70111.
- Gul ST, Khan A, Farooq M, *et al.*, 2017. Effect of sub lethal doses of thiamethoxam (a pesticide) on hemato-biochemical values in cockerels. *Pak Vet J* 37:135-8.
- Gupta SK, Pal AK, Sahu NP, *et al.*, 2014. Haemato-biochemical responses in *Cyprinus carpio* (Linnaeus, 1758) fry exposed to sub-lethal concentration of a phenylpyrazole insecticide, fipronil. *Proceeding of National Academy of Sciences India Section B Biological Sci* 84:113-22.
- Hayasaka D, Korenaga T, Suzuki K, *et al.*, 2012. Cumulative ecological impacts of two successive annual treatments of imidacloprid and fipronil on aquatic communities of paddy mesocosms. *Ecotoxicol Environ Saf* 80:355-62.
- Hussain R, Ghaffar A, Ali HM, *et al.*, 2018: Analysis of different toxic impacts of Fipronil on growth, hemato-biochemistry, protoplasm and reproduction in adult cockerels. *Toxin Rev* 37:294-303.
- Hussain R, Ali F, Javed MT *et al.*, 2019. Clinico-hematological, serum biochemical, genotoxic and histopathological effects of trichlorfon in adult cockerels, *Toxin Rev* DOI: 10.1080/15569543.2019.1673422.
- Hussain R, Khan A, Mahmood F, *et al.*, 2014. Clinico-hematological and tissue changes induced by butachlor in male Japanese quail (*Coturnix japonica*). *Pest Biochem Physiol* 109:58-63.
- Hussain R, Mahmood F, Khan A, *et al.*, 2015. Genotoxic and pathological effects of malathion in male Japanese quail (*Coturnix japonica*). *Pak J Agri Sci* 52:1143-9.
- Khan HAA, Akram W, Iqbal J, *et al.*, 2015. Thiamethoxam resistance in the house fly, *Musca domestica* L.: Current status, resistance selection, cross-resistance potential and possible biochemical mechanisms. *PLoS One* 10:e0125850.
- Kostić J, Kolarević S, Kračun-Kolarević M, *et al.*, 2017. The impact of multiple stressors on the biomarkers response in gills and liver of freshwater breams during different seasons. *Sci Total Environ* 1:601-2:1670-81.
- Mason R, Tennekes H, Sanchez-Bayo F, *et al.*, 2013. Immune suppression by neonicotinoid insecticides at the root of global wildlife declines. *J Environ Immunol Toxicol* 1:3-12.
- Osman MM, EL-Fiky SA, Soheir YM, *et al.*, 2009. Impact of water pollution on histopathological and electrophoretic characters of *Aurichromis niloticus* fish. *Res J Environ Toxicol* 3:9-23.
- Qureshi IZ, Bibi A, Shahid S, *et al.*, 2016. Exposure to sub-acute doses of fipronil and buprofezin in combination or alone induces biochemical, hematological, histopathological and genotoxic damage in common carp (*Cyprinus carpio* L.). *Aquat Toxicol* 179:103-14.
- Roy B and S Nath, 2011. Some haematological investigations on *Oreochromis niloticus* (Trewavas) following exposure to thiamethoxam. *Acta Zool Lituanica* 21:301-5.
- Shalabey SEM, Farrag ARH and El-Saed GSM, *et al.*, 2010. Toxicological potential of thiamethoxam insecticide on albino rats and its residues in some organs. *J Arab Soc Med Res* 5:165-72.
- Strunjak-Perovic I, Lisicic D, Coz-Rakovac R, *et al.*, 2010. Evaluation of micronucleus and erythrocytic nuclear abnormalities in Balkan whip snake *Hierophisgemonensis*. *Ecotoxicology* 19:1460-5.
- Tokumoto J, Danjo M, Kobayashi Y, *et al.*, 2013. Effects of exposure to clothianidin on the reproductive system of male quails. *J Vet Med Sci* 75:755-60.
- Ugurlu P, Ünlü E and Satar Ei, *et al.*, 2015. The toxicological effects of thiamethoxam on *Gammarus kischineffensis* (Schellenberg 1937) (Crustacea: Amphipoda). *Environ Toxicol Pharmacol* 39:720-6.
- Witeska M, Sarnowski P, Ługowska K, *et al.*, 2014. The effects of cadmium and copper on embryonic and larval development of ide *Leuciscusidus* L. *Fish Physiol Biochem* 40:151-63.
- Yan SH, Wang JH, Zhu LS, *et al.*, 2016. Thiamethoxam induces oxidative stress and antioxidant response in zebrafish (*Danio Rerio*) livers. *Environ Toxicol* 31:2006-15.