



## RESEARCH ARTICLE

### Quantitative Evaluation of Age-Related Anatomical Characteristics of Selected Digestive Organs of Dromedary Camel

Anas Sarwar Qureshi<sup>1\*</sup>, Sarmad Rehan<sup>1</sup>, Muhammad Usman<sup>1</sup>, Khizar Hayat<sup>2</sup>, Zaima Umar<sup>1</sup> and Adeel Sarfraz<sup>3</sup>

<sup>1</sup>Department of Anatomy, University of Agriculture, Faisalabad 38040, Pakistan

<sup>2</sup>Department of Anatomy and Histology, University of Veterinary and Animal Science, Lahore, Pakistan

<sup>3</sup>University College of Veterinary and Animal Sciences, The Islamia University of Bahawalpur 63000, Pakistan

\*Corresponding author: anas-sarwar@uaf.edu.pk

#### ARTICLE HISTORY (19-337)

Received: August 04, 2019  
Revised: December 07, 2019  
Accepted: December 09, 2019  
Published online: December 31, 2019

#### Key words:

Age  
Camel  
Digestive system  
Quantitative anatomy

#### ABSTRACT

This study was undertaken to explicate the age-related anatomical variations in the digestive system of dromedaries that might be very much helpful to understand its unique ability to digest different forages very efficiently than other ruminants. Digestive system organs were collected from 14 clinically healthy dromedaries of two age groups: young (1-2 years) or adult (>5 years) animals, after slaughtering for dissection and measurements. Before measuring and weighing various gastrointestinal sections, the mesentery, adipose tissue, and lymph nodes were removed. Studied parameters of upper digestive system included length and thickness of upper and lower lip along with philtrum, esophageal length and diameter. Furthermore, measurements of compound stomach viz rumino-reticulum length, height, diagonal and pillar thickness, both curvatures (dorsal and ventral), omasal and abomasum height, length and weight were also recorded. Lengths of the small and large intestines (small and large colon) were determined while containing digesta and morphological characters of liver (height, length and weight) were also estimated. An allometric regression model;  $Y (\text{Model}) = \beta (\text{B.wt}) \times \alpha$  was applied for bodyweight relation with digestive tract followed by analysis of means variance to compare the young and adult camels. Statistical analysis of anatomical parameters revealed a significant ( $P < 0.05$ ) improvement in the adult as compared to young dromedary group except the thickness of both (upper and lower) lip and philtrum for which non-significant ( $P > 0.05$ ) trend was recorded. Absolute weights of each organ were proved positively related to body weight, however, the relative weights were found negatively related to body weight. The age-related changes in the digestive system are obvious but quantification of these parameters may have a pivotal role to understand camel's unique and efficient digestive system.

©2019 PVJ. All rights reserved

**To Cite This Article:** Qureshi AS, Rehan S, Usman M, Hayat K, Umar Z and Sarfraz A, 2020. Quantitative evaluation of age-related anatomical characteristics of selected digestive organs of dromedary camel. Pak Vet J, 40(2): 175-180. <http://dx.doi.org/10.29261/pakvetj/2019.129>

#### INTRODUCTION

Camels are the unique creatures having specialties different from other ruminants. In Holy Quran, their importance has been narrated as "Don't they look at the camels, how they were created" (The Holy Quran 88: 17). Camels are very unique creatures with similarities and some striking differences in anatomy and physiology than other ruminants. Camels have upper incisors, while other ruminants don't. They have three-chambered stomach; other ruminants have four chambers (Reece, 2015). Camels have unique ability as they can consume a variety

of different forages containing high crude fiber (CF) as it increases the overall particle retention time in the forestomach. It has been documented that the retention time of fiber in the forestomach of camels may be up to 74 hours. In addition to better utilization of CF, they can also survive on low crude protein diets. They can recycle and utilize the urea present in the body for protein synthesis more efficiently than the true ruminants (Schwartz and Dioli, 1992). Similarly, epithelium of the upper digestive tract is sturdier in camels which allows to eat thorny plant and branches which are frequently found in the desert (Bello *et al.*, 2015). Camels owe their ability

to cope dehydration not only due to efficient urinary system (Rehan and Qureshi, 2007) but also digestive system, due to presence of water saccules in compound stomach (Reece, 2015).

Domestic ruminants, on the basis of type of their digestive system, can be classified as either “Cattle-type” or “Moose-type”. Cattle-type ruminants are considered more adaptable animals which attributed to the higher diversity of micro-flora and increased “wash-out” effect in the gut of these animals (Dittmann *et al.*, 2015). Moose-type ruminants produce relatively less amount of saliva and also are considered as browsers while the Cattle-type are strictly grazers (Hofmann *et al.*, 2008; Codron and Clauss, 2010). Due to high roughages proportion in diet, large number of water saccules in its rumino-reticulum and large amount of produced saliva camel is considered close to cattle type ruminants. In bactrian camels, the stomach is reported to be having two main parts, proventriculus and abomasum. Proventriculus further contains two ventricles having glandular sacs. The abomasum is further divided into anterior and posterior enlargements and a middle part (Wang *et al.*, 2000). Despite being crucial for survivability in harsh desert climate, little literature is available regarding gross anatomical parameters of camel’s digestive system and no literature at all about how age influences these parameters. Therefore, this study was planned for the exploration of age and bodyweight dependent changes in the camel’s digestive system to understand its unique digestive system.

## MATERIALS AND METHODS

This study involved fourteen clinically healthy one-humped camels of either sex of two age groups i.e., young (1 to 2 years) and adult (more than 5 years). Live weights of these animals were estimated using following formula (Abebe *et al.*, 2002).

Live weight (kg) = S(m)\*T(m)\*A(m)\*52±25kg  
where

S: shoulder height, T: thoracic girth and A: abdominal girth

Dentition was used to estimate the age of the animals before slaughtering, as described by Schwartz and Diolli (1992). Different physiological parameters including rectal temperature, respiration rate and pulse rate were determined in each animal before slaughter to ascertain the health status of animals under study. Following collection, samples were transferred to the gross anatomy laboratory of Anatomy Department at University of Agriculture, Faisalabad. The dissection protocol was initiated within thirty minutes of slaughtering of the animals. After weighing, the digestive organs were removed from the body and the different sections were separated by ligating at different points.

Specifications of upper digestive tract like thickness and length of lower and upper lips (Length between commissures) along with philtrum were determined. Esophageal length (Phyrnx to rumen) and diameter were estimated by measuring tape.

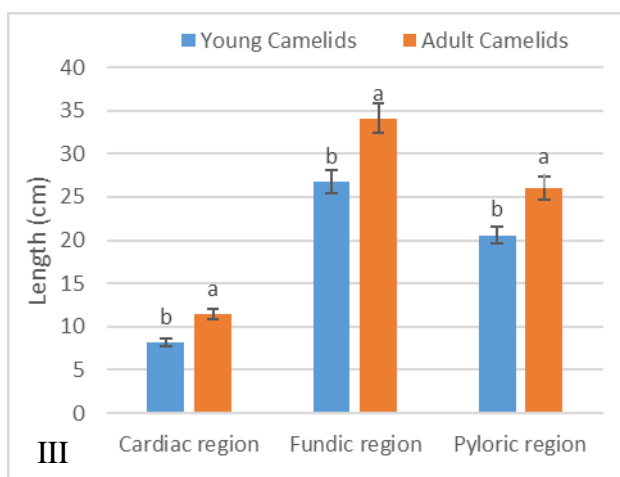
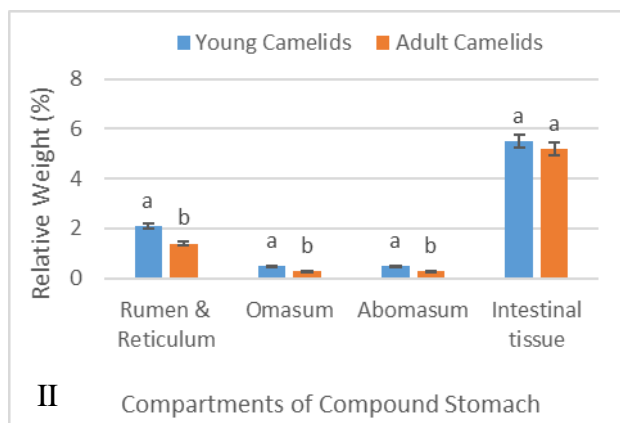
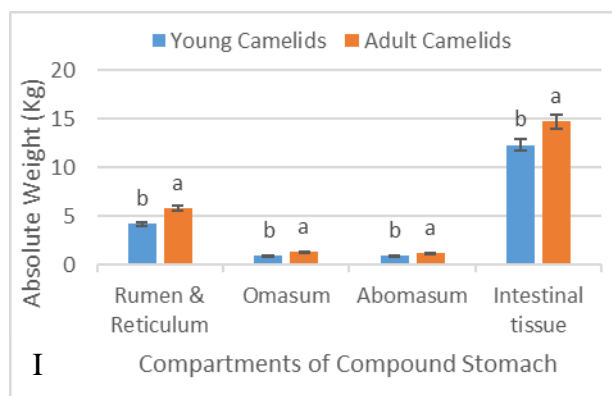
Before measuring and weighing various gastrointestinal (GI) sections, the mesentery, adipose tissue and lymph nodes were removed. Considerable efforts were put into appropriate dissection ensuring an almost complete trimming of all organs prior to data collection. Measurements of rumino-reticulum curvatures (dorsal and ventral), height (dorsal to ventral ruminal sac), diagonal (cranial to caudal border), dorsal and ventral rumen length (cranial to caudal border), omasum height (dorsal to ventral), length (reticulo-omasal to omaso-abomasal junction) and abomasal length (omaso-abomasal junction to start of duodenum) along with different abomasal gastric regions (cardiac, fundic and pyloric) were taken before separating the omasum and abomasum from the reticulorumen. Lengths of the small intestine; SI (start of duodenum to ileocaecal junction), caecum (base to apex of blind sac), small colon (coiled part) and large colon (straight part) were determined while containing digesta. The intestines were laid out in loops on a wet surface with minimal stretching, to measure the length. Each section was then emptied by squeezing out the content and weighed without rinsing. The weights of the different digestive organs were determined using digital weighing balance. The different parameters of liver like height (dorsal to ventral border), weight and length (cardiac to the end of diaphragmatic lobe) was also measured. Relative weight was worked out by using total body and organ weight. Different morphometric parameters like shape, color, length and circumference were calculated by using measuring tape.

**Statistical analysis:** An allometric regression model was described to analyze the effect of body weight (per unit) on digestive tract that is;  $Y (\text{Model}) = \beta (\text{B.wt}) \times \alpha$  where absolute and relative weight of organs are explanatory variables. To compare the young and adult groups of camel, Analysis of Variance (ANOVA) was performed at 5 percent level of significance.

## RESULTS

**Upper digestive tract:** The statistical comparison of different anatomical parameters like length and thickness of upper and lower lips in young and adult camels are given in the Table 1 showing length is significantly ( $P < 0.05$ ) increased in adult camels. The difference of the thickness of both lips was found non-significant ( $P > 0.05$ ) in young and adult camels. The effect of age on philtrum’s length was found significant ( $P < 0.05$ ) as it increased in adult camels group. Mean comparison of esophagus length and diameter depicted significant ( $P < 0.05$ ) increase in adult camels (Table 1).

**Compound stomach:** Camels compound stomach composed of rumino-reticulum, omasum and abomasum (Fig. 2). The absolute weight of all compartments was observed significantly ( $P < 0.05$ ) heavier in adult as compared to the young camels (Fig. 1). Unlike the absolute weight, the relative weight followed the reversed trend i.e significantly ( $P < 0.05$ ) heavier in young camels as compared to the adult. The absolute and relative weight of compartment 1<sup>st</sup> (rumino-reticulum) were seen heavier among all the compound stomach compartments (Fig. 1).



**Fig. 1:** Graphical representation of gross anatomical parameters of different compartments of compound stomach of young and adult camels. I; Represents the significant ( $P < 0.05$ ) heavier absolute weight of compound stomach compartments rumen & reticulum, omasum, abomasum and intestinal tissue in adult camels. II: The relative weight of all above-mentioned organ was found significant ( $P < 0.05$ ) high in young camels. III: Greater areas of different abomasum regions (cardiac, fundic and pyloric) was found in adult camels. Graph column sharing different superscript a & b are statistically different at significant level of 0.05.

**Table 1:** Mean  $\pm$  SEM values of different gross anatomical parameters of upper digestive tract in young and adult camels

Parameters (cm)	Mean $\pm$ SEM		P value
	Young	Adult	
Upper lip length	2.8 $\pm$ 0.3	6.3 $\pm$ 1.2	0.02
Lower lip length	1.5 $\pm$ 0.4	2.7 $\pm$ 0.2	0.03
Upper lip thickness	1.5 $\pm$ 0.3	1.5 $\pm$ 0.6	0.47
Lower lip thickness	0.8 $\pm$ 0.1	0.8 $\pm$ 0.2	0.48
Length of philtrum	1.5 $\pm$ 0.2	2.5 $\pm$ 0.4	0.02
Length of esophagus	101.7 $\pm$ 6.7	149.7 $\pm$ 11.6	0.01
Diameter of esophagus	2.2 $\pm$ 0.8	4.2 $\pm$ 0.6	0.01

Means having  $P < 0.05$  are statistically different.

**Table 2:** Mean  $\pm$  SEM values of different gross anatomical parameters of compound stomach in young and adult camels

Parameters (cm)	Mean $\pm$ SEM		P value
	Young	Adult	
Length of lesser curvature (Ventral curvature) of rumeno-reticulum	115.8 $\pm$ 6.2	57.9 $\pm$ 6.0	0.02
Length of greater curvature (Dorsal curvature) of rumino-reticulum	45.7 $\pm$ 0.7	152.0 $\pm$ 6.0	0.02
Length of rumino-reticulum	49.7 $\pm$ 4.7	94.5 $\pm$ 9.2	0.01
Height of rumino-reticulum	24.4 $\pm$ 6.6	49.0 $\pm$ 7.9	0.01
Thickness of rumeno-reticular pillar	0.3 $\pm$ 0.1	0.6 $\pm$ 0.1	0.07
Length of omasum	57.8 $\pm$ 9.1	79.2 $\pm$ 12.1	0.00
Width of omasum	14.3 $\pm$ 0.1	19.9 $\pm$ 2.7	0.02
Length of abomasum	60.9 $\pm$ 6.2	97.5 $\pm$ 6.5	0.01

Means having  $P < 0.05$  are statistically different.

The mean values of rumino-reticular gross parameters like the length of the rumen, its greater (dorsal) and lesser (lesser) curvature and pillar thickness (Fig. 2) were recorded significantly ( $P < 0.05$ ) higher in adult as compared to young camels (Table 2). Statistical analysis followed the similar trend between the mean values of length and width of omasum and abomasum (Table 2). The regression analysis demonstrated the positive correlation between body weight of camels and the weight of all compartments of the stomach and intestinal tissue while relative weight of aforementioned organs was seen negatively relate to body weight (Table 4).

The length of different gastric regions of the true stomach (abomasum); cardiac, fundic and pyloric regions were also recorded and adult camels are found to have significantly ( $P < 0.05$ ) higher values than the young camels (Fig. 1 & 2).

**Intestines:** The absolute weight of the total intestinal tissue including small and large intestine was significantly ( $P < 0.05$ ) high in the adult camels while this trend was observed non-significant ( $P > 0.05$ ) in case of relative body weight (Fig. 1 & 2). Significantly ( $P < 0.05$ ), more length of small and large intestine was recorded in adult animals as compared to the young camels and the large intestine parts like small and large colon length showed the same trend as that of either intestine (Table 3). The age positively influence the different parameters of liver significantly ( $P < 0.05$ ) as these values recorded more in the adult group of camel. Relationship of absolute and relative weight of some organs (rumen-o-reticulum, omasum, abomasum, intestines) has been mentioned in Table 4. Absolute weight of organs had a positive correlation while relative weight had a negative correlation with body weight. Table 4 also explains the proportionate increase in organ weight with per unit increase in body weight.

## DISCUSSION

The range of length and diameter of lips and esophagus, respectively, recorded in current study is in general agreement with those reported earlier (Abass, 2009; Hussein *et al.*, 2016) in camels (1-2 meters and 6-8 cm), respectively. However, no literature was found to compare values of lips and esophagus in young camels. Longer philtrum in the adult camel is helpful in independent movements of lips halves (right and left halves of upper lips) during browsing.



**Fig. 2:** Camel stomach with measuring points for anatomical parameters demonstrated. 2(A): r = Rumeno-reticular height, rl = Rumeno-reticular length, om = Omasum length, ab = Abomasum length, lo= Lesser omentum, int = Intestine. 2 (B) depicted the internal view of different gastric regions of abomasum namely as c = cardiac region, f = Fundic region, p = Pyloric region, om = Omasum length, r = rumen reticulum sac. 2 (C): gross anatomical view of different Intestinal parts of camels as j = Jejunum, L = Ileum, lc = Large colon, sc = small colon.

**Table 3:** Mean  $\pm$  SEM values of different gross anatomical parameters of intestinal tissues along with their parts in young and adult camels

Parameters (ft)	Mean $\pm$ SEM		P value
	Young	Adult	
Length of small intestine	146.0 $\pm$ 8.5	184.5 $\pm$ 4.5	0.01
Length of large intestine	40.7 $\pm$ 3.3	60.3 $\pm$ 4.4	0.00
Length of small colon	29.7 $\pm$ 2.1	39.0 $\pm$ 1	0.02
Length of large colon	9.3 $\pm$ 1.5	14.0 $\pm$ 1	0.01
Weight of liver (Kg)	4.76 $\pm$ 0.6	8.93 $\pm$ 0.23	0.02
Length of liver	1.60 $\pm$ 0.25	2.19 $\pm$ 0.1	0.04
Height of Liver	1.09 $\pm$ 0.1	1.44 $\pm$ 0.12	0.01

Means having P<0.05 are statistically different.

**Table 4:** Equations of linear regression model considering body weight independent and camels' different organs weight as an explanatory parameter

Parameter(s)	Mean $\pm$ SEM	Effect of b. wt (r)	Model Y= $\beta$ (B.wt) $\times$ $\alpha$	R <sup>2</sup>
Rumen & Reticulum wt (Kg)	4.97 $\pm$ 0.93	0.91	0.0068(B.wt) + 2.8093	0.8452
Rt. wt of Rumen & reticulum (%)	1.74 $\pm$ 0.34	-0.92	-0.0025(B.wt) + 2.5305	0.849
Omasum wt (Kg)	1.15 $\pm$ 0.21	0.96	0.0017(B.wt) + 0.6251	0.9389
Rt. wt of Omasum (%)	0.39 $\pm$ 0.09	-0.86	-0.0007(B.wt) + 0.6022	0.7596
Abomasum wt (Kg)	1.11 $\pm$ 0.17	0.95	0.0013(B.wt) + 0.71	0.9111
Rt. wt of Abomasum (%)	0.40 $\pm$ 0.1	-0.87	-0.0007(B.wt) + 0.6303	0.8003
Total Intestinal Tissue wt (Kg)	17.35 $\pm$ 4.76	0.96	0.0367(B.wt) + 5.7839	0.9255
Rt. wt of Intestinal Tissue (%)	5.59 $\pm$ 0.87	-0.78	-0.0055(B.wt) + 7.3083	0.6121

b. wt: Bodyweight, Rt. wt: Relative weight, SEM: Standard error of mean, r: Correlation factor between b. wt and different organ weight, R<sup>2</sup>: Goodness of model.

The compound stomach of camels consisted of three chambers: rumino-reticulum, omasum and abomasum. The stomach in the alpaca (Vaughan, 2008) and Lama Glama (Lazuli *et al.*, 2004) also consisted of three compartments. Length of rumino-reticulum in this study matches with previous findings (Ibrahim *et al.*, 2014). Large sized rumino-reticulum in camels can be attributed to its unique ability to digest the forages having high crude fiber. This can also be linked with the fact that grazers and browsers require more time for digesta retention hence larger rumen is present (Broom, 2017). Furthermore, the water saccules are present in camel's rumino-reticulum area only, absent in other ruminant species. These water sacs increase surface area for absorption as they can absorb VFAs three to four times faster than other ruminants (Reece, 2015; Gamal, 2016). Moreover, these water sacs could be one mechanism to protect camels from dehydration in hot weather conditions. No literature could be found to compare the effect of age on rumino-reticulum in camels.

The absolute weight of omasum was significantly (P>0.05) higher in adult camels, while relative weight was significantly (P>0.05) higher in young camels. No literature could be found to compare the effect of age on absolute and relative weight of omasum in camels. However, the reported value of relative weight in adult sheep, goat and cows are 0.6, 1.2 and 3.3%, respectively (Holtenius and Björnhag, 1989).

The absolute weight of abomasum was heavier (P>0.05) in adult camels but the relative weight (Fig. 1) exhibited otherwise similar pattern was found for camel



and ruminants heart (Qureshi *et al.*, 2017; Usman *et al.*, 2018). No literature was available to compare the effect of age on absolute and relative weights of abomasum in camels. However, in giraffe absolute weight was reported to be 1.2 kg (Sauer *et al.*, 2016).

The length of small intestine was significantly higher in adult camels (184.5±4.5 ft) than young ones (146.0±8.5 ft). No literature was found to compare the influence of age on small intestine length in camels. The reported length of small intestine in equines (75 ft) and bovines (130 ft) (Pasquini *et al.*, 2003) puts it closer to bovines. The increased small intestine length could be attributed to the provision of increased surface area for nutrient absorption which enables the camels to withstand the harsh conditions of food scarcity and dehydration, thereby increasing efficiency of digestion in camels than other ruminants.

Large intestinal length was also positively related to age and weight of camels and found significantly ( $P>0.05$ ) more in the adults (60.3±4.4 ft) than young (40.7±3.3 ft) camels (Fig. 1). Literature could not be found to compare the influence of body weight and age on large intestine length in camels. Large intestine total length reported in ruminants and equines was 46 and 27ft (Hall and Silver, 2009), respectively, which is not even close to the length of the large intestine of adult camels. Reabsorption of water primarily takes place in the large intestine (Hall and Silver, 2009), hence, more length can be correlated to more water absorption area in camel which enables camels to survive in desert conditions.

The cumulative relative weight of small and large intestines followed the unlike trend (Fig. 1) which may be linked to the lengthening of small intestine, thus providing more area for the absorbance of glucose and lactose due to the presence of a substance called beta-galactosidase, necessary for lactose digestion in young animals (Saqib *et al.*, 2017).

Out of large intestine, large colon length was measured as 9.3±1.5 and 14.0±1 ft in young and adult camels, respectively ( $P<0.05$ ). Literature could not be found to compare the influence of age on large colon length in camels. However, these values of adult camels are in line with the equids large colon (14.7 ft) length (Ross and Hanson, 1992). Although, large colon in equines is organized into the left ventral, left dorsal, right ventral and right dorsal sacs.

The small colon length was significantly ( $P>0.05$ ) high in adults (39±1 ft) as compared to the young camels (29.7±2.1 ft). No literature was available about the influence of age on small colon length in camels. These values also depict huge difference from equines in which length of small colon is only 13.12 feet (Ross and Hanson, 1992). The increased length of small colon could be attributed to the provision of increased surface area for nutrient absorption, increased mucus secretion and ultimately lubrication of undigested food, thereby further increasing digestive efficiency in camels than other animals.

The average weight of liver in adults (8.93±0.23 Kg) was significantly ( $P<0.05$ ) higher than young camels (4.74±0.6 Kg). No scientific literature could be found regarding liver weight in different age groups of camels. However, liver weight in adult camels was in agreement

with previous reports (Smuts *et al.*, 1987). In equines and bovines it's weight is 5 kg and 3-4 kg (Pasquini *et al.*, 2003), respectively, that led to the conclusion that camels have far heavier liver than these animals. Being large-sized and without a gall bladder puts camel closer to equines than bovines. Large-sized liver could facilitate digestive processes, blood detoxification and increased interleukin production (potentially increased immunity) than other species. The absence of gallbladder can be attributed to an increased liver weight in camels that enables the liver to produce enough bile sufficient for digestion of forages.

**Conclusions:** The water saccules are present in camel's rumino-reticulum area only, absent in other ruminant species. The lengths of small and large intestines are more than bovines and equines and could be attributed to the provision of increased surface area for nutrient and water absorption. Camels have far heavier liver than equines and bovines. Large-sized liver could facilitate digestive processes, blood detoxification and increased interleukin production (potentially increased immunity) than other species. Based on this data, we can conclude that camel digestive system is neither like ruminants nor equines and have very special anatomical properties to cope the stresses of harsh climate.

**Acknowledgments:** We would like to thank the Dr. Maqsood Alam and his staff for assistance and support in sampling from the local slaughter house.

**Authors contribution:** ASQ conceived the idea and finalized manuscript. SR, MU, KH, AS and ZU completed the sampling, applied the statistics and prepared rough draft of manuscript.

## REFERENCES

- Abass TA, 2009. Morphohistological study of the Esophagus of the one Humped Camel (*Camelus dromedarius*) Al- Anbar J Vet Sci 2:46-52.
- Abebe W, Getinet AM and Mekonne HM, 2002. Study on live weight, carcass weight and dressing percentage of Issa camels in Ethiopia. *Revue Méd Vét* 153:713-6.
- Bello O, Alimi OO, Sonfanda ML, *et al.*, 2015. Histomorphometric study of the prenatal development of the circumvallate papillae of one-humped camel (*Camelus dromedarius*). *Anat Physiol* 05: <https://doi.org/10.4172/2161-0940.1000168>.
- Broom DM, 2017. Components of sustainable animal production and the use of silvopastoral systems. *R Bras Zootec* 46:683-8.
- Codron D and Clauss M, 2010. Rumen physiology constrains diet niche: linking digestive physiology and food selection across wild ruminant species. *Canad J Zool* 88:1129-38.
- Dittmann MT, Jurgen H, Hammer S, *et al.*, 2015. Digesta kinetics in gazelles in comparison to other ruminants: Evidence for taxon-specific rumen fluid throughput to adjust digesta washing to the natural diet. *Comp Biochem Physiol* 185:58-68.
- Gamal MA, 2016. Anatomical study of the water cells area in the dromedary camel's rumen (*Camelus dromedarius*). *Nova J Med Biol Sci* 5:10.20286/nova-jmbs-050183.
- Hall JB and Silver S, 2009. Digestive system of the cow. *Sciences-New York* pp:1-4.
- Hofmann RR, Streich WJ, Fickel J, *et al.*, 2008. Convergent evolution in feeding types: Salivary gland mass differences in wild ruminant species. *J Morphol* 269:240-57.
- Holtenius K and Björnhag G, 1989. The significance of water absorption and fibre digestion in the omasum of sheep, goats and cattle. *Comparative Biochemistry and Physiology. Comp Physiol* 94:105-9.

- Hussein AJ, Cani MM and Hussein DM, 2016. Anatomical and histological studies of esophagus of one-humped camel (*Camelus dromedarius*). MRVSA 5:11-8.
- Ibrahim AA, Hassan A and Zarroug HI, 2014. Gross anatomical and histometric studies on the stomach glandular sacs of the dromedary camel (*Camelus dromedarius*). Sudan J Sci Technol 15:46-56.
- Lazuliet RH, Ghazi MD, Gideon EJ et al., 2004. Topography and morphology of the llama (*Lama glama*). Int'l J Morph 22:155-64.
- Pasquini C, Spurgeon T and Pasquini S, 2003. Anatomy of domestic animals; Systemic and regional approach. SUDZ Publishing, Pennsylvania, United States 10<sup>th</sup> Edit.
- Qureshi AS, Muhammad SK, Shah MG, et al., 2017. human anatomy open access journal functional morphometric research on blood regulating organs in animal models with special emphasis on cardiovascular conditions : A Review. J Hum Anat 1:1-11.
- Reece WO, Erickson HE, Goff JP, et al., 2015. Dukes' physiology of domestic animals. 13<sup>th</sup> Edit. Ross WR, Hanson RR, 1992. Large intestine. In: Auer JA (ed): Equine Surgery. Philadelphia: WB Saunders; 379-406.
- Saqib S, Akram A, Halim SA, et al., 2017. Sources of  $\beta$ -galactosidase and its applications in food industry. 3 Biotech 7:79-9.
- Sauer C, Bertelsen MF, Lund P, et al., 2016. Quantitative macroscopic anatomy of the giraffe (*Giraffa camelopardalis*) digestive tract. J Vet Med Series C: Anat Histol Embryol 45:338-349.
- Schwartz HJ and Dioli M, 1992. The one-humped camel (*Camelus dromedarius*) in eastern Africa : a pictorial guide to diseases, health care and management. Margraf ISBN: 3-8236-1218-2.
- Smuts MMS and Bezuidenhout AJ, 1987. Anatomy of the dromedary. Oxford, Clarendon Press, New York Oxford University Press.
- Rehan S and Qureshi AS, 2007. Morphometric analysis of heart, kidneys and adrenal glands in dromedary camel calves. J Cam Prac Res 14:27-31.
- Usman M, Qureshi AS, Sarmad R, et al., 2018. Histomorphometric evaluation of dromedarian (*Camelus Dromedarius*) heart. J Cam Prac Res 25:231-6.
- Vaughan J, 2008. Managing alpacas in Australia 3<sup>rd</sup> Ed. Australian Alpaca Association Ltd.
- Wang JL, Lan G, Wang GX, et al., 2000. Anatomical subdivisions of the stomach of the Bactrian camel (*Camelus bactrianus*). J Morphol 245:161-7.