



## RESEARCH ARTICLE

### Casticin Alleviates Testicular and Spermatological Damage Induced by Cisplatin in Rats

Muhammad Umar Ijaz<sup>1</sup>, Arfa Tahir<sup>1</sup>, Abdul Samad<sup>1</sup>, Asma Ashraf<sup>2</sup>, Muhammad Ameen<sup>3</sup>, Muhammad Imran<sup>4\*</sup>, Saima Yousaf<sup>1</sup> and Noreen Sarwar<sup>5</sup>

<sup>1</sup>Department of Zoology, Wildlife and Fisheries, University of Agriculture, Faisalabad, Pakistan

<sup>2</sup>Department of Zoology, Government College University, Faisalabad, Pakistan

<sup>3</sup>Department of Zoology, University of the Punjab, Lahore, Pakistan

<sup>4</sup>Department of Parasitology, University of Agriculture, Faisalabad, Pakistan

<sup>5</sup>Department of Microbiology, University of Veterinary and Animal Sciences, Lahore, Pakistan

\*Corresponding author: imran.asghar@uaf.edu.pk

#### ARTICLE HISTORY (19-414)

Received: September 11, 2019

Revised: September 19, 2019

Accepted: December 02, 2019

Published online: December 31, 2019

#### Key words:

Casticin

Cisplatin

Oxidative stress

Testes

Testicular damage

#### ABSTRACT

Cancer is one of the leading causes of mortality in animals. Cisplatin (CP) is a chemotherapeutic drug, which is used in treatment of several types of solid tumors. However, it causes numerous side effects on multiple organs, specifically to testicular tissues. This study elucidated the alleviative effects of casticin (CAS) on CP induced damages in testes of rats. Twenty-four adult male Sprague Dawley rats were used and divided into four groups. Each group consisted of six animals. These four groups were treated as followed: Control group (0.9% saline), CP treated group (10 mg/kg. b.wt.), CP+CAS treated group (10 mg/kg. b.wt. CP and 50 mg/kg. b.wt. CAS) and CAS treated group (50 mg/kg. b.wt.). The treatment duration was one week. Biochemical, histomorphometric, hormonal and spermatogenic profiles were assessed. Results of present investigation indicated that CP treatment significantly decreased the activities of catalase (CAT), superoxide dismutase (SOD), peroxidase (POD) and glutathione reductase (GSR), while thiobarbituric acid reactive substances (TBARS) level was increased. Furthermore, the count of germ cells and Leydig cells, epithelial height and diameter of seminiferous tubules, plasma and intratesticular testosterone concentrations as well as daily sperm production (DSP) along with its efficiency were decreased. Whereas, luminal diameter and interstitial spaces were increased. CAS is a flavonoid, which exhibits antioxidant and reactive oxygen species (ROS) scavenging properties. Therefore, it restored these damages to some degree by attenuating CP induced toxicity in testicular tissues.

©2019 PVJ. All rights reserved

**To Cite This Article:** Ijaz MU, Tahir A, Samad A, Ashraf A, Ameen M, Imran M, Yousaf S and Sarwar N, 2020. Casticin alleviates testicular and spermatological damage induced by cisplatin in rats. Pak Vet J, 40(2): 234-238. <http://dx.doi.org/10.29261/pakvetj/2019.127>

#### INTRODUCTION

Cisplatin (CP), also known as cis-diamminedichloro-platinum, is an extensively used antineoplastic drug. It is used for the treatment of numerous types of cancers including neck, bladder, head, cervix, ovaries, stomach, lungs and testes. Despite having broad efficacy against multiple cancers, its clinical usage is restricted owing to its unlimited organ toxicities, especially testicular toxicity (Kabel, 2017). The exact mechanism of CP-generated toxicity on male reproductive system is still not completely known. However, the damages are caused due to overproduction of ROS in testicular tissues, which

gives rise to oxidative stress. The excessive ROS may lead to necrosis and organ damage by lipid peroxidation (LP) and denaturation of proteins (Fallahzadeh *et al.*, 2017).

CP is basically a DNA alkylating agent, that causes its anti-cancerous effects by enforcing DNA crosslinking and breaking the double strands. These effects of CP may attribute to disturbance of DNA replication and transcription mechanisms, ultimately causing apoptosis. CP treatment can also damage the semen profile and interstitial cells with visible shrinking and vacuolation (Reddy *et al.*, 2016). The ROS has potential to impair the cellular structures like mitochondria, DNA, endoplasmic reticulum and lipids (Gevrek and Erdemir, 2018).

Collectively, CP treatment may result into inhibition of spermatogenesis, testicular atrophy and reduction in number, motility and viability of sperms in male reproductive system (Hamza *et al.*, 2016). Azoospermia, oligospermia, dropping of testicular weight and ultimately permanent or temporary male sterility occurs with exposure of this drug (Vassilakopoulou *et al.*, 2016). Early experimental studies revealed the alleviative roles of several antioxidants against CP-induced testicular damages (Fouad *et al.*, 2017). Casticin (CAS) having chemical formula "3', 5-dihydroxy-3, 4', 6, 7-tetramethoxyflavone" is a flavonoid, which is obtained from various parts of Vitex species. CAS exhibits antioxidant, anti-inflammatory and anti-cancerous properties (Lee *et al.*, 2015).

CAS also shows immunomodulatory, anti-asthmatic, analgesic, tracheospasmodic, anti-hyperprolactinemia, opioidergic, anti-glioma and anti-angiogenic features. Moreover, it also displays mitigating properties for lung toxicity, liver fibrosis and rheumatoid arthritis (Chan *et al.*, 2018). Therefore, present experiment was designed to explore alleviative impacts of CAS against CP-caused damages in testes of adult male rats.

## MATERIALS AND METHODS

**Chemicals:** Both CP and CAS were purchased from the Sigma-Aldrich (Germany).

**Animals:** Twenty-four adult male Sprague-Dawley rats (200-300 grams) were used for experimentation in Animal house of University of Agriculture, Faisalabad and kept on 12 hrs light: 12 hrs dark cycles with controlled temperature (26±2°C). For feeding, food pellets and tap water was given to rats.

**Experimental design:** After acclimatization to the laboratory conditions for one week, rats were separated into four groups and each group consisted of six rats. They were provided with following treatments: control group (was provided with 0.9% saline orally); CP-treated group (received 10 mg/kg. b.wt. of CP intraperitoneally once in a week). Group III (CP+CAS treated group) received both 10 mg/kg. b.wt. of CP intraperitoneally and 50 mg/kg. b.wt. of CAS by oral gavage and CAS-treated group received 50 mg/kg. b.wt. of CAS daily by oral gavage. The experiment lasted for one week (Donmez and Bozdogan, 2014). The rats were anesthetized and decapitated. Both testes were removed and washed by using normal saline. Tissues were minced, homogenized with distilled water and centrifuged (3000 rpm for about 15 min).

**Biochemical analysis:** The activities of antioxidant enzymes CAT, SOD, POD, GSR and TBARS level were analysed in testicular homogenate. CAT and POD activity was evaluated in accordance with the methodology of Chance and Maehly (1955). SOD activity was assessed by noticing the colour intensity as proposed by Kakkar *et al.* (1984). GSR activity was measured according to the method of Carlberg *et al.* (1975). As TBARS is the by-product of LP, thus, LP content was expressed by the level of TBARS. TBARS level was estimated by computing optical density of supernatant with the help of spectrophotometer according to method described by Wright *et al.* (1981).

**Hormonal analysis:** The concentrations of plasma and intratesticular testosterone were determined with the help of enzyme-linked immuno sorbent assay (ELISA) kits (Sensitivity 98%; Catalog# EK-311-15) which were bought from Amegnix, Burlingame, CA, USA.

**Estimation of DSP:** Spermatid count in homogenate was taken by methodology of Robb *et al.* (1978). Homogenization was carried out in 5 mL of 0.9% saline solution and twenty microliters of sample was put on Neubauer chamber. Counting of late spermatids was done at 40x under microscope. Efficiency of sperm production (i.e., spermatids number per gram of testes) was estimated by using this obtained value. The DSP was computed by dividing the number of homogenization-resistant spermatids by 6.3 as shown below:

$$DSP = Y/6.3$$

Where, Y= number of spermatids present in homogenate

**Histopathological analysis:** The testicular tissues were fixed in 10% neutral buffered formalin for 48 hrs, dehydrated with different concentrations of ethanol, cleared with xylene and fixed in paraffin. Finally, 4 µm thick sections were prepared and stained with hematoxylin and eosin. The structural changes of the sections were assessed with the help of microscope. Interstitial spaces, epithelial height, diameter, lumen of seminiferous tubules and tunica albuginea thickness were calculated by operating image J2x software (Jensen, 2013).

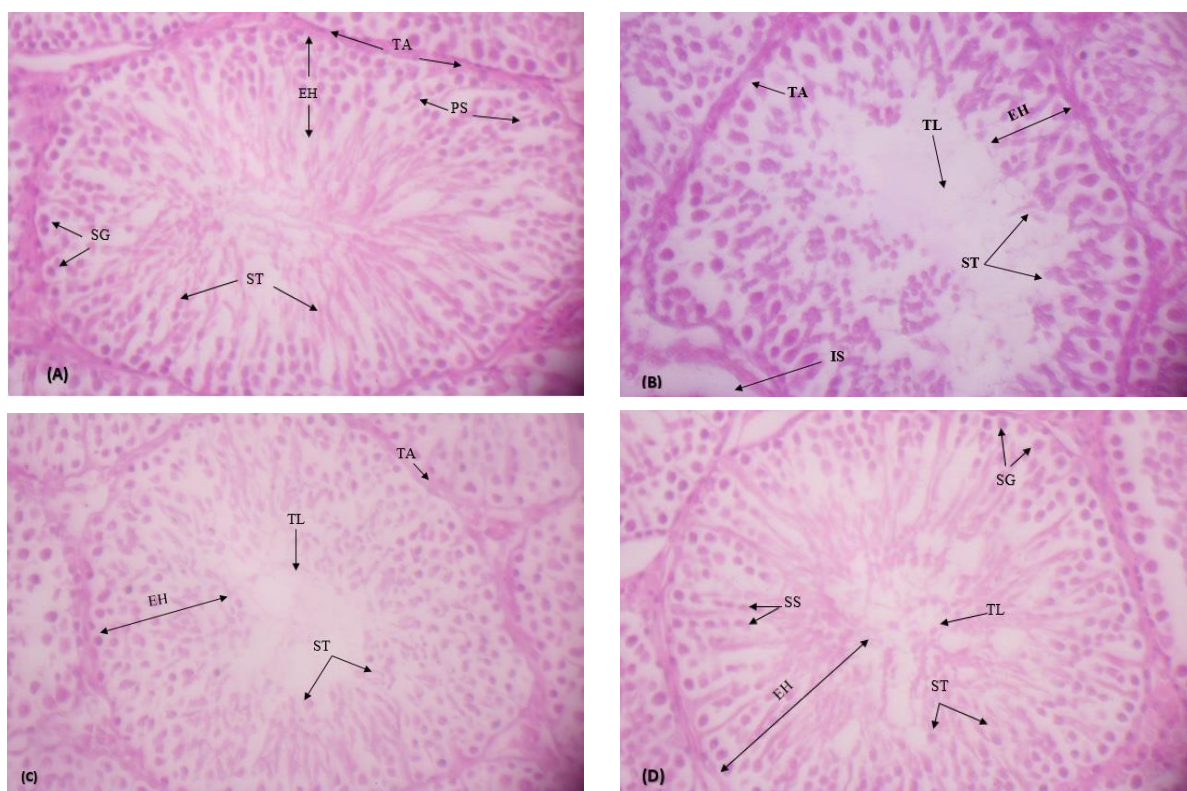
**Statistical analysis:** The results were expressed as Mean ± SEM. All the data was subjected to Tuckey's test after one-way analysis of variance (ANOVA). Graph pad prism 5 software was used for comparing various groups. Significant level was adjusted at P<0.05.

## RESULTS

**Effect of CAS on testicular antioxidant enzymes:** CP administration brought significant (P<0.05) reduction in activities of CAT, SOD, POD and GSR but significantly (P<0.05) increased TBARS level in testicular tissues in comparison to control group. CAS alone or in combination with CP led to significant (P<0.05) escalation in activities of CAT, SOD, POD and GSR, whereas TBARS level was reduced as compared with CP-induced group (Table 1).

**Effect of CAS on intratesticular and plasma testosterone:** The plasma and intratesticular testosterone concentrations in CP administered group were significantly (P<0.05) reduced in comparison to control group. CAS administration alone and accompanied with CP, led to a significant (P<0.05) elevation in the plasma testosterone and intratesticular testosterone concentrations as compared with CP induced group (Table 2).

**Effect of CAS on DSP and efficiency of DSP:** The significant (P<0.05) reduction in DSP and efficiency of DSP was noticed in CP-intoxicated groups as compared with control group. Nonetheless, DSP and efficiency of DSP was elevated significantly in CP+CAS as well as CAS (alone) treated groups in comparison to CP-administered group (Table 3).



**Fig. 1:** Testicular histopathology of control and treated rats (H&E, 40X) from: **(A)** Control group displaying thick germinal epithelium comprising of different stages of germ cells and narrow luminal area containing spermatozoa; **(B)** CP treated group displaying sloughing of epithelial layer, empty lumen and degeneration of interstitial spaces; **(C)** CP+CAS treated groups showing decreased sloughing of germinal epithelium, tubular lumen filled with spermatids and restoration of degenerated interstitial spaces; **(D)** CAS treated group displaying compact seminiferous tubules with less interstitial spaces and normal spermatogenesis with filled lumen. Tunica albuginea (TA), Epithelial height (EH), Spermatogonia (SG), Spermatids (ST), Primary spermatocytes (PS), Secondary spermatocytes (SS), Interstitial spaces (IS), Tubular lumen (TL).

**Table 1:** Effect of CP, CP+CAS and CAS on the biochemical constituents in testes

Groups	CAT (U/mg protein)	SOD (U/mg protein)	POD (nmole/mg protein)	GSR (nM NADPH oxidized/min/mg tissue)	TBARS (nM/mg tissue)
Control	6.31±0.16 <sup>b</sup>	4.08±0.08 <sup>a</sup>	3.40±0.06 <sup>a</sup>	2.71±0.14 <sup>a</sup>	12.71±0.47 <sup>b</sup>
CP	3.03±0.11 <sup>c</sup>	2.12±0.06 <sup>b</sup>	1.84±0.06 <sup>b</sup>	0.94±0.06 <sup>b</sup>	22.88±0.50 <sup>a</sup>
CP + CAS	6.57±0.10 <sup>ab</sup>	4.06±0.04 <sup>a</sup>	3.08±0.05 <sup>a</sup>	14.74±0.41 <sup>ab</sup>	2.65±0.12 <sup>b</sup>
CAS	7.02±0.09 <sup>a</sup>	4.24±0.11 <sup>a</sup>	3.29±0.07 <sup>a</sup>	12.12±0.61 <sup>ab</sup>	2.27±0.72 <sup>b</sup>

**Table 2:** Effect of CP, CP+CAS and CAS on the intratesticular and plasma testosterone concentrations in testes

Groups	Intratesticular testosterone concentrations (ng/g tissue)	Plasma testosterone concentrations (ng/mL)
Control	92.33±4.33 <sup>a</sup>	6.83±0.31 <sup>a</sup>
CP	34.33±8.09 <sup>b</sup>	3.62±0.33 <sup>b</sup>
CP + CAS	105.33±7.54 <sup>a</sup>	7.37±0.26 <sup>a</sup>
CAS	120.66±8.09 <sup>a</sup>	7.61±0.43 <sup>a</sup>

Means that do not share a letter are significantly different.

**Table 3:** Effect of CP, CP+CAS and CAS on the DSP and efficiency of DSP in testes

Groups	DSP × 10 <sup>5</sup> /testes	Efficiency of DSP × 10 <sup>5</sup> /g of testes
Control	17.50±0.37 <sup>ab</sup>	11.44±0.66 <sup>ab</sup>
CP	3.78±0.32 <sup>c</sup>	2.18±0.53 <sup>c</sup>
CP + CAS	16.05±0.28 <sup>b</sup>	9.56±0.50 <sup>b</sup>
CAS	19.08±0.50 <sup>a</sup>	13.06±1.15 <sup>a</sup>

Means that do not share a letter are significantly different.

### Effect of CAS on histomorphometry of testicular tissues:

Histomorphometric analysis of testes of rats belonging to control group displayed wide and compact germinal epithelium comprising of different stages of germ cells in addition to narrow luminal area stuffed with spermatids (Fig. 1A). The diameter of seminiferous tubules and tunica albuginea as well as its epithelial height were decreased, while increase in luminal area and

interstitial spaces was noticed in CP-administered group (Fig. 1B). Sections of testes from CP+CAS and CAS (only) treated rats displayed considerable elevation in diameter and epithelial height of Seminiferous tubules in addition to increased tunica albuginea height in comparison to CP-treated group. While, lumen of both these groups showed fairly mature spermatids when compared with CP group (Fig. 1C and 1D). A significant ( $P<0.05$ ) reduction in germinal epithelium thickness and ST diameter was found in CP induced rats as compared to rats of control group. However, CP+CAS administration brought about significant ( $P<0.05$ ) elevation in epithelial height and diameter of seminiferous tubules in comparison to CP induced group (Table 4). The interstitial spaces between ST and diameter of tubular lumen in CP inoculated rats also displayed significant increase ( $P<0.05$ ) as compared to rats of control group. The administration of CAS along with CP significantly ( $P<0.05$ ) amended the diameter of tubular lumen in addition to interstitial spaces in comparison to CP (alone) induced group (Table 4). Height of tunica albuginea was drastically decreased in CP intoxicated group in comparison to control group. On the other hand, CAS treatment by itself and in combination with CP, increased

**Table 4:** Effect of CP, CP+CAS and CAS on the morphometry of testes

Groups	Interstitial space ( $\mu\text{m}$ )	Tunica albuginea height ( $\mu\text{m}$ )	ST diameter ( $\mu\text{m}$ )	ST epithelial height ( $\mu\text{m}$ )	Tubular lumen ( $\mu\text{m}$ )
Control	8.50 $\pm$ 0.28 <sup>a</sup>	21.2 $\pm$ 0.70 <sup>ab</sup>	177.10 $\pm$ 1.70 <sup>a</sup>	75.50 $\pm$ 0.76 <sup>a</sup>	13.70 $\pm$ 0.64 <sup>b</sup>
CP	13.53 $\pm$ 0.26 <sup>a</sup>	15.05 $\pm$ 0.26 <sup>c</sup>	151.33 $\pm$ 1.85 <sup>b</sup>	28.00 $\pm$ 1.15 <sup>c</sup>	64.33 $\pm$ 0.88 <sup>a</sup>
CP + CAS	11.47 $\pm$ 0.25 <sup>c</sup>	19.5 $\pm$ 0.31 <sup>bc</sup>	174.77 $\pm$ 0.34 <sup>a</sup>	60.33 $\pm$ 0.88 <sup>b</sup>	19.33 $\pm$ 0.66 <sup>b</sup>
CAS	9.53 $\pm$ 0.26 <sup>b</sup>	26.83 $\pm$ 0.73 <sup>a</sup>	176.66 $\pm$ 0.88 <sup>a</sup>	76.33 $\pm$ 1.20 <sup>a</sup>	13.67 $\pm$ 0.88 <sup>b</sup>

Means that do not share a letter are significantly different.

**Table 5:** Effect of CP, CP+CAS and CAS on the various germ cell stages and Leydig cells in testes

Groups	Spermatogonia	Primary spermatocyte	Secondary spermatocyte	Spermatids	Leydig cells/cm <sup>2</sup>
Control	45.66 $\pm$ 1.20 <sup>ab</sup>	38.33 $\pm$ 0.88 <sup>ab</sup>	30.07 $\pm$ 0.51 <sup>a</sup>	48.3 $\pm$ 0.88 <sup>a</sup>	4.32 $\pm$ 0.31 <sup>ab</sup>
CP	30.33 $\pm$ 1.45 <sup>c</sup>	21.66 $\pm$ 0.88 <sup>c</sup>	19.18 $\pm$ 0.60 <sup>a</sup>	28.7 $\pm$ 0.88 <sup>c</sup>	3.20 $\pm$ 0.20 <sup>b</sup>
CP + CAS	40.00 $\pm$ 0.57 <sup>b</sup>	32.66 $\pm$ 1.20 <sup>b</sup>	29.99 $\pm$ 0.93 <sup>a</sup>	42.6 $\pm$ 0.88 <sup>b</sup>	3.54 $\pm$ 0.28 <sup>b</sup>
CAS	46.00 $\pm$ 1.52 <sup>a</sup>	41.00 $\pm$ 2.30 <sup>a</sup>	34.32 $\pm$ 0.66 <sup>a</sup>	51.3 $\pm$ 0.88 <sup>a</sup>	5.19 $\pm$ 0.19 <sup>a</sup>

Means that do not share a letter are significantly different.

the tunica albuginea height when compared with CP induced rats (Table 4). The number of spermatogonia, secondary spermatocytes, primary spermatocytes, spermatids and Leydig cells was decreased significantly in CP induced rats as compared to rats of control group. Whereas, administration of CAS (alone) and in combination with CP brought about significant ( $P < 0.05$ ) regain in count of the germ cells, spermatids and Leydig cells as compared to CP induced rats (Table 5).

## DISCUSSION

Cisplatin is extensively used for the treatment of variety of cancers. But its effectiveness is challenged due to its associated detrimental effects, especially to male reproductive system (Ilbey *et al.*, 2009). In current study, biochemical, hormonal and histomorphometric analyses were performed to check the alleviative effects of CAS on CP induced testicular toxicities. The ROS generated due to oxidative stress have adverse impacts on the tissues. Body develops an antioxidant mechanism consisting of antioxidant enzymes like CAT, SOD, POD and GSR. Antioxidants scavenge ROS, hence, suppressing oxidation of various macromolecules which ultimately avoid further tissue damage. However, these antioxidants can also be supplemented from plant sources to limit oxidative stress (Nahid *et al.*, 2017).

It has been reported that CAS is extracted from different plant species, which exhibits antioxidant properties as it is useful in decreasing levels of ROS by escalating levels of antioxidant enzymes (Ekinci-Akdemir *et al.*, 2018). Current study demonstrated that single intraperitoneal CP dose@10 mg/kg. b.wt. instigated oxidative lesions/injury in whole reproductive system of male rats. It is well-acknowledged that antioxidant enzymes such as CAT, SOD and GS(Px) are essential to lessen the ROS, generated due to CP-induced oxidative stress, to prevent further harm (Aksu *et al.*, 2017). CP administration generates free oxygen radicals in mitochondria including superoxide anion, hydrogen peroxide and hydroxyl radicals, leading to oxidative injury (Aksu *et al.*, 2016). Oxygen radicals are altered to hydrogen peroxide by SOD while, CAT alters hydrogen peroxide into oxygen and water (Zhao *et al.*, 2014). The LP occurs due to these excessively produced free radicals and this CP-induced LP is revealed by significant rise in TBARS level.

CP treatment led to a significant reduction in activities of antioxidant enzymes i.e., CAT, SOD, POD and GSR while level of TBARS was increased. These findings were in accordance with previous investigations, as Reddy *et al.* (2016) indicated that CP treatment instigated a significant reduction in activities of CAT and SOD while significant increase was seen in TBARS level in testes of rats. Decreased level of GSR imply that GSH was not generated in large quantity, which is mandatory for suppression of hydrogen peroxide. This build-up of hydrogen peroxide leads to oxidative stress and gonadotoxicity in males. The changes in antioxidant enzymes' levels in the testes are shown in table 1. To assess the influences of CAS on CP-induced damages to testes, we treated our animals with CAS along with CP. Treatment with CAS alleviated the testes against the adverse impacts/influences of CP and minimized the oxidative stress. We found that CAS escalated the activities of CAT, SOD, POD and GSR, while, decreased the TBARS level significantly. The alleviative effects of CAS on antioxidant enzymes were due to its antioxidant properties.

The concentrations of plasma and intracellular testosterone were also reduced in CP-administered rats in comparison to the control group as shown in table 2. The enzymes like 17 $\beta$ -Hydroxysteroid dehydrogenase and 3 $\beta$ -Hydroxysteroid dehydrogenase are potentially involved in the regulation of steroidogenic processes. CP intoxication reduced the level of these enzymes, which may be the reason behind reduced concentration of testosterone (Abarikwu *et al.*, 2012). CP treatment reduced the number of Leydig cells and DSP along with efficiency of DSP in testicular tissues. Leydig cells secrete testosterone, which is crucial for production of sperms in males (Tremblay, 2015). Amin *et al.* (2012) stated that CP can considerably damage the testicular tissues and decrease the rate of gametes generation due to liberation of ROS. This might be due to decline in number and performance of Leydig cells, which led to reduction in concentrations of testosterone; ultimately decreasing DSP along with its efficiency in rats. CAS treatment restored the number of Leydig cells, concentration of testosterone and consequently DSP including its efficiency to some degree as shown in tables 5, 2 and 3 respectively.

Histomorphometric examination exhibited that CP administration resulted in reduction in number of germ cells, decline in whole process of spermatogenesis, depreciation of epithelial thickness and diameter of

seminiferous tubules. However, tubular lumen was increased as shown in table 4. There was also a significant reduction in thickness of seminiferous tubules and increase in interstitial spaces in CP-induced rats. In a nutshell, several minor CP-instigated damages amalgamate to create a huge impact on overall testicular toxicity. While, directly or indirectly, oxidative stress is responsible for all the CP-induced damages in testes (Attehsahin *et al.*, 2006). CAS reversed these detrimental effects of CP to some extent due to its antioxidant property and ROS scavenging ability. Our findings proposed that CAS may prove to be an effective candidate for the suppression of testicular toxicities caused by CP in rats. However, further investigations are required to explicate the mechanism behind alleviative effects of CAS against CP induced testicular toxicities.

**Conclusions:** CP administration caused oxidative stress due to over-production of ROS, which led to decrease in activities of CAT, SOD, POD and GSR and increase of TBARS level. The number of Leydig cells was also reduced, which instigated a significant reduction in plasma and intratesticular testosterone concentrations and DSP along with the efficiency of DSP. While, tubular laminal diameter and interstitial spaces were increased. These CP induced testicular damages were recovered to some extent by its co-treatment with CAS. Therefore, CAS may be used as an associative agent along with CP to alleviate its testicular toxicities.

**Acknowledgements:** This piece of work was funded by University of Agriculture, Faisalabad, Pakistan.

**Authors contribution:** MUI, AT and SY conceived and designed the experiments. AS and MA performed the experiments. AA helped in statistical analysis and data interpretation. MUI, MI and NS wrote the manuscript.

## REFERENCES

- Abarikwu S, Otuechere C, Ekor M, *et al.*, 2012. Rutin ameliorates cyclophosphamide-induced reproductive toxicity in male rats. *Toxicol Int* 19:207.
- Aksu EH, Kandemir FM, Altun S, *et al.*, 2016. Ameliorative effect of carvacrol on cisplatin-Induced reproductive damage in male rats. *J Biochem Mol Toxicol* 30:513-20.
- Aksu EH, Kandemir FM, Ozkaraca M, *et al.*, 2017. Rutin ameliorates cisplatin-induced reproductive damage via suppression of oxidative stress and apoptosis in adult male rats. *Andrologia* 49:e12593.
- Amin A, Abraham C, Hamza AA, *et al.*, 2012. A standardized extract of *Ginkgo biloba* neutralizes cisplatin-mediated reproductive toxicity in rats. *Biomed Res Int* 1:678-82.
- Attehsahin A, Karahan I, Türk G, *et al.*, 2006. Protective role of lycopenene on cisplatin-induced changes in sperm characteristics, testicular damage and oxidative stress in rats. *Reprod Toxicol* 21:42-7.
- Carlberg I and Mannervik B, 1975. Purification and characterization of the flavoenzyme glutathione reductase from rat liver. *J Biol Chem* 250:5475-80.
- Chan EWC, Wong SK and Chan HT, 2018. Casticin from *Vitex* species: a short review on its anticancer and anti-inflammatory properties. *J Integr Med* 16:147-52.
- Chance B and Maehly A, 1955. [136] assay of catalases and peroxidases. *Methods Enzymol* 2:764-75.
- Donmez DB and Bozdogan S, 2014. Effect of sodium selenite on testicular damage induced by cisplatin in adult male rats. *Biol Med* 6:209.
- Ekinci-Akdemir FN, Yildirim S, Kandemir FM, *et al.*, 2018. The effects of casticin and myricetin on liver damage induced by methotrexate in rats. *Iran J Basic Med Sci* 21:1281-8.
- Fallahzadeh A, Rezaei Z, Rahimi H, *et al.*, 2017. Evaluation of the effect of pentoxifylline on cisplatin-induced testicular toxicity in rats. *Toxicol Res* 33:255-63.
- Fouad AA, Qutub HO, Fouad AE, *et al.*, 2017. Epigallocatechin-3-gallate counters cisplatin toxicity of rat testes. *Pharm Biol* 55:1710-4.
- Gevrek F and Erdemir F, 2018. Investigation of the effects of curcumin, vitamin E and their combination in cisplatin induced testicular apoptosis using immunohistochemical technique. *Turk J Urol* 44:16-23.
- Hamza AA, Elwy HM and Badawi AM, 2016. Fenugreek seed extract attenuates cisplatin-induced testicular damage in Wistar rats. *Andrologia* 48:211-21.
- Ilbey YO, Ozbek E, Cekmen M, *et al.*, 2009. Protective effect of curcumin in cisplatin-induced oxidative injury in rat testis: mitogen-activated protein kinase and nuclear factor-kappa B signalling pathways. *Hum Reprod* 24:1717-25.
- Jensen EC, 2013. Quantitative analysis of histological staining and fluorescence using Image. *J Anat Rec* 296:378-81.
- Kabel AM, 2018. Zinc/alogliptin combination attenuates testicular toxicity induced by doxorubicin in rats: Role of oxidative stress, apoptosis and TGF- $\beta$ 1/NF- $\kappa$ B signaling. *Biomed Pharmacother* 97:439-49.
- Kakkar P, Das B and Viswanathan PN, 1984. A modified spectrophotometric assay of superoxide dismutase. *Ind J Biochem BioPhys* 21:130-2.
- Lee H, Jung KH, Lee H, *et al.*, 2015. Casticin, an active compound isolated from *Vitex Fructus*, ameliorates the cigarette smoke-induced acute lung inflammatory response in a murine model. *Int Immunopharmacol* 28:1097-101.
- Nahid A, Neelabh C and Navneet K, 2017. Antioxidant and antimicrobial potentials of *Artemisia indica* collected from the Nepal region. *J Pharm Sci Rev* 9:1822-6.
- Reddy KP, Madhu P and Reddy PS, 2016. Protective effects of resveratrol against cisplatin-induced testicular and epididymal toxicity in rats. *Food Chem Toxicol* 91:65-72.
- Robb GW, Amann RP and Killian GJ, 1978. Daily sperm production and epididymal sperm reserves of pubertal and adult rats. *J Reprod Fertil* 54:103-7.
- Tremblay JJ, 2015. Molecular regulation of steroidogenesis in endocrine Leydig cells. *Steroids* 103:3-10.
- Vassilakopoulou M, Boostandoost E, Papaxoinis G, *et al.*, 2016. Anticancer treatment and fertility: Effect of therapeutic modalities on reproductive system and functions. *Crit Rev Oncol Hematol* 97:328-34.
- Wright J, Colby H and Miles P, 1981. Cytosolic factors which affect microsomal lipid peroxidation in lung and liver. *Arch Biochem Biophys* 206:296-304.
- Zhao YM, Gao LP, Zhang HL, *et al.*, 2014. Grape seed proanthocyanidin extract prevents DDP-induced testicular toxicity in rats. *Food Funct* 5:605-11.