



RESEARCH ARTICLE

Effect of Jig on the Precision of Tibial Plateau Leveling Osteotomy in Toy-Breed Dogs

YH Roh, JW Yun, JH Lee and HB Lee*

College of Veterinary Medicine, Chungnam National University, 99 Daehak-ro, Yuseong-gu, Daejeon, 34134 Republic of Korea

*Corresponding author: seatiger76@cnu.ac.kr

ARTICLE HISTORY (19-363)

Received: August 11, 2019
Revised: July 29, 2020
Accepted: July 31, 2020
Published online: August 13, 2020

Key words:

Cranial cruciate ligament
Jig
Tibial plateau leveling
osteotomy
Toy-breed dogs

ABSTRACT

Because of plate development, it is now possible to perform tibial plateau leveling osteotomy (TPLO) in small-breed dogs with cranial cruciate ligament rupture. Compared with conventional treatment, faster walking and better function are reported post-TPLO. However, TPLO can be more difficult in toy-breed dogs than large-breed dogs. Because of the smaller bones, it is difficult to manipulate the bone fragments during surgery, and small movements of bones can cause major differences in limb alignment. In TPLO, a jig is conventionally recommended to increase the accuracy of alignment; however, installation of the jig can be difficult in small-breed dogs, and it may cause problems such as iatrogenic fracture. The present study thus aimed to evaluate the accuracy of TPLO without a jig in toy-breed dogs. Paired stifles (n=22) obtained from 11 toy-breed dogs cadavers (body weight range, 2.0-7.4 kg) were randomly assigned to a jig or non-jig group. Radiographic images were obtained preoperative and postoperative TPLO. Tibias were dissected from the hindlimb and measured for evaluation of accuracy. The following postoperative parameters were compared: tibial plateau angle, mechanical medial proximal tibial angle, osteotomy location, tibia crest thickness, gap between segments, and orientation line angles. There were no significant differences between the two groups, demonstrating that jig usage does not affect precision of TPLO in toy-breed dogs. Therefore, it is better not to use a jig in toy-breed dogs with relatively small bones, considering the risk of iatrogenic injury, cost and operation time.

©2020 PVJ. All rights reserved

To Cite This Article: Roh YH, Yun JW, Lee JH and Lee HB, 2020. Effect of jig on the precision of tibial plateau leveling osteotomy in toy-breed dogs. Pak Vet J, 40(4): 484-488. <http://dx.doi.org/10.29261/pakvetj/2020.070>

INTRODUCTION

Cranial cruciate ligament rupture (CCLR) is a major cause of orthopedic diseases leading to lameness and osteoarthritis of pelvic limbs in small-breed dogs (Innes *et al.*, 2000). Conservative treatments are typically used for dogs weighing less than 10 kg. However, in recent decades, surgical methods have been developed to prevent the progression of arthritis caused by instability of joints secondary to cranial cruciate ligament damage. These surgical treatments include intracapsular reconstruction, extracapsular sling, and tibial plateau leveling osteotomy (TPLO). Extracapsular stabilization techniques are traditionally used to treat CCLR in small-breed dogs (Lazar *et al.*, 2005). However, in some cases, this technique fails because of the presence of an excessive tibial plateau angle (TPA) (Barnes *et al.*, 2016; Knight and Danielski, 2018). Because of plate development, TPLO has been increasingly performed in small-breed

dogs in recent years. Within a few days after TPLO, most small-breed dogs can put weight on the operated leg. It has been suggested that the short-term and long-term outcomes of TPLO are more favorable than those of other techniques (Garnett and Daye, 2014; Witte and Scott, 2014; Cosenza *et al.*, 2015; Barnes *et al.*, 2016; Janovec *et al.*, 2017; Knight and Danielski, 2018).

However, TPLO is a relatively difficult procedure due to the distinctive shape of the tibia bone (Burton *et al.*, 2013). The proximal tibia is triangular in cross-section and has great anatomic variation. Many surgical errors can occur because of this characteristic. In addition, differences between small and large-breed dogs can make TPLO difficult. Small-breed dogs are reported to have a higher TPA than large-breed dogs, which is associated with caudal deformity of the proximal tibia (Macias *et al.*, 2002). A higher TPA in small-breed dogs may contribute to tibial tuberosity fracture with excessive rotation of the tibia beyond the point of patellar ligament insertion. If the

tibial osteotomy is not parallel to the tibial plateau and orthogonal to the long axis of the tibia, angular and rotational deformities can occur (Windolf *et al.*, 2008; Boudrieau, 2009). Malposition of the osteotomy too far cranially or distally can result in a high TPA and tibial tuberosity fracture following TPLO (Kowaleski *et al.*, 2005). Even if osteotomy is properly performed, technical errors during reduction and rotation of the segments can result in angular and torsional deformities after surgery (Bergh *et al.*, 2012). Therefore, the original TPLO technique designed by Slocum described application of a jig, and recent studies have reported that a novel jig guide have been developed to overcome these difficulties and reduce technical errors (Slocum and Slocum, 1993; Bell and Ness, 2007; Schmerbach *et al.*, 2007; Burton *et al.*, 2013; Tan *et al.*, 2014; Mariano *et al.*, 2016).

Prior to osteotomy, the jig is secured to the proximal and distal tibia by inserting two pins placed orthogonal to the tibial long axis. The pins are removed after rotation and fixation of the proximal segment. The jig pins help the surgeon align the saw blade perpendicular to the tibial long axis and maintain a fixed plane orientation of the tibial segments intraoperatively. In this way, the jig and jig pins adjunctively help correct tibial valgus or varus angulation. However, the jig has several drawbacks. Securing the jig can increase the probability of the incision line being located cranially and distally, which can result in a greater angle than the planned TPA. This problem may be more serious in small-breed dogs with small bones (Kowaleski *et al.*, 2005). The proximal pin may be inserted incorrectly into the joints, which can damage the articular cartilage and result in iatrogenic fractures. When the pin is inserted, it may not enter the plateau perpendicularly, causing the position of the osteotomy parallel to the jig pin to be inaccurate. The inserted jig pin and jig can also collide with the implant, implant screws, and pins required for tibial rotation and temporary fixation. Iatrogenic fractures can also occur because of the relatively large size of the jig pins compared with the bones (Bergh *et al.*, 2012; Cosenza *et al.*, 2015).

Some studies have reported that a jig for TPLO has been questionable although TPLO osteotomy and reduction were improved with a jig (Bell and Ness, 2007; Schmerbach *et al.*, 2007; Burton *et al.*, 2013; Mariano *et al.*, 2016). However, there has been no study of whether jig placement is advantageous in TPLO for small-breed dogs. Since small-breed dogs have small bones, even small movements are likely to cause abnormal bone alignment. The objective of this cadaveric study was to investigate the effectiveness of a jig during TPLO in toy-breed dogs. On the basis of the assumption that even small movements can make a significant difference in such breeds, we hypothesized that use of a jig could significantly affect the results of TPLO in toy-breed dogs.

MATERIALS AND METHODS

Specimens and groups: In total, 22 stifle joints were obtained from the toy-breed dog cadavers. None of the dogs had stifle joint abnormalities on radiographic examination. The cadavers were stored at -20°C and thawed at room temperature for 24h before surgery. Tibiae operated on with

a jig were classified as the jig group, whereas the other tibiae were classified as the non-jig group.

Surgical procedure: All TPLO surgeries were performed by an experienced orthopedic surgeon. Dogs were placed in the dorsal recumbent position. If the jig (Mini TPLO Jig, IMEX® Veterinary, Inc., Mississauga, Canada) was used for one leg, the jig was not used for the other leg. After identifying the medial collateral ligament (MCL), a 1.6 mm K-wire was inserted just caudal to the MCL and distal to the joint surface. Another identical pin was inserted into the distal tibial diaphysis. Reduction and fixation with pins and the TPLO plate were performed (Slocum and Slocum, 1993). A TPLO saw (12 mm), 2.0 mm Synthes plate, and locking and cortical screws (Mini TPLO system, DePuy Synthes Vet, Solothurn, Switzerland) were used. After surgery, radiographic images were taken and assessed. Next, the tibia was detached from the body, and all soft tissues were removed. With the tibia bone positioned on a table, the desired parameters were measured using a caliper (Vernier caliper, Bluebird®, Seoul, Korea).

TPA and mechanical medial proximal tibial angle: Preoperative and postoperative TPA and mechanical medial proximal tibial angle (mMPTA) values were measured using a radiographic software program (Viewrex®, Techheim CO. LTD., Seoul, Korea) (Bell and Ness, 2007).

Osteotomy location: The osteotomy location (the relationship between the central circle of the saw and the intercondylar tubercle) was measured using a radiographic software program (Viewrex®, Techheim CO. LTD., Seoul, Korea) (Fig. 1A). The long axis of the tibia was drawn from the intercondylar tubercle superimposition to the center of the talus. The appropriate size of the circle was drawn along the osteotomy line, and the center of the circle was marked to evaluate the precision of the osteotomy. The distance between the intercondylar tubercle and center of the circle was divided by the radius of the circle and recorded in %. The direction of eccentricity was classified according to the position of the center based on the long axis of tibia: cranioproximal, caudoproximal, craniodistal, or caudodistal.

Craniocaudal orientation line angle and proximodistal orientation line angle: The craniocaudal orientation line angle (CrCaOLA) and proximodistal orientation line angle (PrDiOLA) were measured by radiographs (Fig. 1B and 1C) (Wheeler *et al.*, 2003; Schmerbach *et al.*, 2007). The open angle of the medial side was defined as positive, and the open angle of the lateral side was defined as negative.

Tibia crest thickness and gap between fragments: The postoperative tibial crest thickness (PoTCT) was measured. The distance of the tibia crest was determined from the lines perpendicular to the patellar ligaments from Sharpe's fibers to the cutting line. The gap between the proximal and distal fragments was measured using a caliper (Fig. 2). Both the inside and outside were measured, and the widest gap was used as the reference.

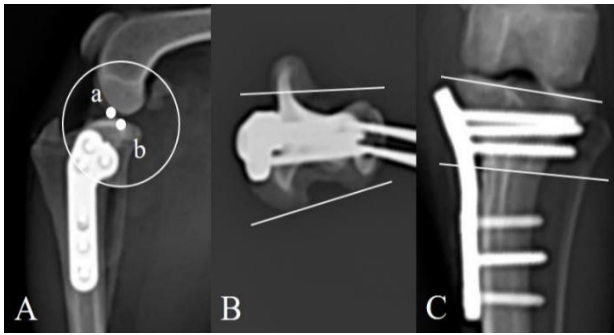


Fig. 1: Radiographic measurements of the proximal tibia. Measurement of osteotomy location (A). Point (a) indicates the location of the intercondylar tubercle. After surgery, a circle was drawn along the osteotomy line. The center of the circle is point (b). The distance between point (a) and point (b) was measured. Measurement of craniocaudal and proximodistal orientation line angle (B and C). Two reference lines were measured in the proximal tibia fragments. Reference line 1 (RL1) was the line of the medial and lateral posterior connections of the tibial plateau. Reference line 2 (RL2) was the most distal junction line of the medial and lateral sides of the tibial plateau. The angle between RL1 and the postoperative osteotomy line was termed the craniocaudal orientation line angle (CrCaOLA), whereas the angle between RL2 and the osteotomy line was termed the proximodistal orientation line angle (PrDiOLA).




Fig. 2: Measurement of the medial and lateral gap between the segments. The widest part of the gaps was measured using a caliper.

Statistical analysis: Data are expressed as the mean±standard deviation (SD). T-tests were performed to assess differences between the groups, and 95% confidence intervals of the differences between the means of each variable for each group were calculated. A P-value <0.05 was considered to be statistically significant.

All statistical analyses were performed using SPSS software, version 22.0 (IBM SPSS Statistics 22.0, IBM Corp, New York, USA).

RESULTS

The results of the statistical analysis are summarized in Table 1. The breeds included mongrel (n=6), poodle (n=2), maltese (n=2), and miniature pinscher (n=1). The sample comprised six male and five female dogs with a mean body weight of 4.3 kg (range, 2.0-7.4 kg).

TPA: The mean preoperative TPA (PrTPA) was $26.1 \pm 3.57^\circ$. The mean postoperative TPA was $5.38 \pm 0.62^\circ$ in the jig group and $5.51 \pm 0.75^\circ$ in the non-jig group, which was not a significant difference ($P=0.67$).

Limb alignment: The mean postoperative mMPTA (PomMPTA) was $97.05 \pm 4.14^\circ$ in the jig group and $95.16 \pm 2.69^\circ$ in the non-jig group. The difference between groups was not statistically significant ($P=0.22$). The mean CrCaOLA was $10.34 \pm 6.89^\circ$ in the jig group and $6.46 \pm 6.38^\circ$ in the non-jig group, which was not a significant difference ($P=0.22$). The mean PrDiOLA was $1.35 \pm 1.41^\circ$ in the jig group and $0.76 \pm 0.93^\circ$ in the non-jig group. This was not a significant difference between the two groups ($P=0.27$).

Osteotomy Location: The mean deviation of the osteotomy location was $10.01 \pm 1.71\%$ in the jig group and $9.53 \pm 1.08\%$ in the non-jig group. There was no significant difference between the groups in terms of osteotomy location ($P=0.44$). All directions of the osteotomy location in the two groups, without regard to the jig, were caudodistal.

Tibial crest thickness and gap between the segments: The mean PoTCT was 6.69 ± 1.01 mm in the jig group and 7.2 ± 2.16 mm in the non-jig group, which was not a statistically significant difference ($P=0.49$). In the jig group, the mean lateral gap between the proximal and distal fragments (LGPDF) was 1.05 ± 0.89 mm and the mean medial gap between the proximal and distal fragments (MGPDF) was 0.29 ± 0.36 mm. In the non-jig group, the mean LGPDF was 1.29 ± 1.31 mm and the mean MGPDF was 0.3 ± 0.41 mm. These group differences were not statistically significant ($P=0.61$ for LGPDF and $P=0.96$ for MGPDF).

Table 1: Preoperative TPA, postoperative TPA, preoperative mMPTA, postoperative mMPTA, osteotomy location, postoperative tibial crest thickness, gap between the proximal and distal fragment, craniocaudal and proximodistal orientation line angle with and without a jig.

	PrTPA (Deg.)	PoTPA (Deg.)	PrmMPTA (Deg.)	PomMPTA (Deg.)	OL (%)	PoTCT (mm)	LGPDF (mm)	MGPDF (mm)	CrCaOLA (Deg.)	PrDiOLA (Deg.)
Group 1 (jig)	26.1 ± 3.57	5.38 ± 0.62	95.02 ± 2.69	97.05 ± 4.14	10.01 ± 1.71	6.69 ± 1.01	1.05 ± 0.89	0.29 ± 0.36	10.34 ± 6.89	1.35 ± 1.41
Group 2 (Non-jig)	26.1 ± 3.57	5.51 ± 0.75	94.23 ± 1.89	95.16 ± 2.69	9.53 ± 1.08	7.2 ± 2.16	1.29 ± 1.31	0.3 ± 0.41	6.46 ± 6.38	0.76 ± 0.93
P value	1	0.67	0.43	0.22	0.44	0.49	0.61	0.96	0.22	0.27
95%* confidence interval†	3.18 to - 3.17	0.48 to - 0.74	2.86 to - 1.28	4.95 to - 1.18	1.76 to - 0.79	0.99 to - 2.0	0.75 to - 1.24	0.33 to - 0.35	9.48 to - 2.33	1.64 to - 0.48

PrTPA, Preoperative TPA; PoTPA, Postoperative TPA; PrmMPTA, Preoperative mMPTA; PomMPTA, Postoperative mMPTA; OL, Osteotomy location; PoTCT, Postoperative tibial crest thickness; LGPDF, Lateral gap between proximal and distal fragments; MGPDF, Medial gap between proximal and distal fragments; CrCaOLA, Craniocaudal orientation line angle; PrDiOLA, Proximodistal orientation line angle. * Denotes significant difference ($P < 0.05$). † The 95% confidence interval for the difference between the mean values for groups.

DISCUSSION

The present study examined whether the use of a jig affects the accuracy of TPLO surgery in toy-breed dogs. In our experiment, the use of a jig did not affect the accuracy of TPLO. Furthermore, there were no statistically significant differences between the jig and non-jig groups in terms of TPA, limb alignment, osteotomy location, tibial tuberosity thickness, and gap and osteotomy line between the segments. These results are similar to the reported findings in large-breed dogs (Bell and Ness, 2007; Schmerbach *et al.*, 2007; Tan *et al.*, 2014).

This study also examined whether a jig affects the osteotomy location. A suitable osteotomy line has the center point of the circle in the intercondylar tubercle. If the center of the saw blade is not positioned at this point, incomplete leveling may occur because of the geometric phenomenon known as tibial long axis shift. If the center of the TPLO deviates distally, the tibial plateau may deviate craniodistally, which may increase TPA after surgery (Kergosien *et al.*, 2004; Kowaleski *et al.*, 2005). In our study, the surgical method aimed to achieve a postoperative TPA of 5°. Regardless of jig use, the TPA values were near the intended value of 5° (mean postoperative TPA was 5.38° in the jig group and 5.51° in the non-jig group). Cranial tibial thrust did not occur. Taken together, our findings suggest that postoperative TPA value is unaffected by jig use. Distal caudal deviation of the osteotomy location has also been reported to occur following TPLO surgery (Tan *et al.*, 2014). In our study, postoperative images showed that the center of the saw was deviated from the intercondylar eminence. All centers of the osteotomy circle tended to deviate in the caudodistal direction. The mean value of deviation was 10.01% in the jig group and 9.53% in the non-jig group. However, there was no significant group difference in the amount of deviation ($P=0.44$). When using a jig, the proximal jig pin does not physically affect the osteotomy in a direct way. However, the osteotomy line may be placed further because the surgeon intends to avoid the jig pin and ensure adequate bone stock for the TPLO plate (Kowaleski *et al.*, 2004; Kowaleski *et al.*, 2005; Tan *et al.*, 2014). Alternatively, there may be compression in the caudodistal direction leading to distraction in the cranioproximal fragments in the course of rotation and reduction (Wheeler *et al.*, 2003).

Tibial tuberosity fracture is related to the small tibial tuberosity segment and rotation of the fragment beyond the safe point (Bergh *et al.*, 2012). In addition, inappropriate osteotomy placement or selection of saw blade is considered to be the causes of narrow tibial tuberosity, which results in tibial tuberosity fracture. A tibial tuberosity width of 6.5 mm is reported to be safe for avoiding tibial tuberosity fracture in small dogs (Barnes *et al.*, 2016). In this study, the mean \pm SD PoTCT was 6.69 \pm 1.01 mm in the jig group and 7.2 \pm 2.16 mm in the non-jig group, which was not a statistically significant difference ($P=0.49$). This result indicates that the jig did not seem to cause instability leading to tibia fracture. A tibia tuberosity fracture is likely to occur with a combination of various forces, bone density and damage during osteotomy in small-breed dogs (Barnes *et al.*, 2016).

Angular and torsional deformities after TPLO surgery have been reported. The osteotomy saw should be parallel to the tibial plateau and perpendicular to the sagittal plane of the tibia. Angled osteotomy results in translation with rotation (Wheeler *et al.*, 2003; Windolf *et al.*, 2008; Boudrieau, 2009; Bergh *et al.*, 2012). However, this technique is more demanding in small-breed dogs because of the narrow surgical view and variation in the tibia such as high TPA and excessive rotation. If the cranio-caudal orientation line and proximodistal orientation line are not parallel to the plateau, varus–valgus or internal–external rotation deformity can occur (Wheeler *et al.*, 2003). The CrCaOLA, PrDiOLA, and PomMPTA were all measured to determine whether a jig directly affects the varus–valgus after surgery. The mean CrCaOLA was 10.34 \pm 6.89° in the jig group and 6.46 \pm 6.38° in the non-jig group, which was not a significant group difference ($P=0.22$). The mean PrDiOLA was 1.35 \pm 1.41° in the jig group and 0.76 \pm 0.93° in the non-jig group, which was also not a significant difference ($P=0.27$). Therefore, we conclude that the jig did not affect the osteotomy line pattern. The normal mMPTA value reported in small-breed dogs is 95.2 \pm 3.5° (mean \pm SD) (Kim *et al.*, 2016). In our study, the comparison of PrmMPTA and PomMPTA showed no significant change. Regardless of jig use, the mean PomMPTA was within the normal range for small-breed dogs (97.05 \pm 4.14° in the jig group and 95.16 \pm 2.69° in the non-jig group) (Kim *et al.*, 2016). Thus, the jig did not affect the PomMPTA values. Even if the jig does not have a significant impact on TPLO results, jig application in patients with tibial varus–valgus and torsional deformities may be beneficial because of evaluation of the alignment of the tibia and temporary stabilization.

In addition to osteotomy line assessment affecting alignment during the TPLO procedure, the accuracy of fragment reduction can be assessed by measuring the lateral and medial gap between fragments. The widest part of the gap was measured and recorded. We found no significant difference between the groups ($P=0.96$ in the medial gap and $P=0.61$ in the lateral gap). However, the mean LGPDF was significantly wider than the mean MGPDP in all groups. These results are consistent with the findings of similar studies in large-breed dogs. These results likely occur because the surgeon sees the medial side and not the lateral side and because the force acts on the medial side to the lateral side during application of the plate. The characteristics of the tibia front may also affect the results. The gaps were always on the cranioproximal part of the osteotomy line. The gaps and osteotomy distraction in the cranioproximal part were created by the tibial compression mechanisms during the TPLO procedure (Wheeler *et al.*, 2003; Schmerbach *et al.*, 2007). In our study, postoperative images showed that the center of the saw was deviated from the intercondylar eminence. Therefore, it is likely that gap formation results from osteotomy distraction with caudodistal compression. Taken together, our findings demonstrate that use of a jig does not affect gap formation in toy-breed dogs.

There is limitation to this study that a small number of cadaveric stifle bones was used to assess the accuracy. There were no specimens with a high TPA (>35), and the mean prTPA was 26°. There were also no cases with rotated fragments beyond the safe point. The proportion of

small-breed dogs with a high TPA is greater than that of large-breed dogs (Barnes *et al.*, 2016). Inclusion of small-breed dogs with a high TPA, osteoarthritis, or bone deformities would increase the generalizability of our results. However, such dogs were excluded because these factors would preclude comparison of the measured values after surgery. Other factors such as muscle and ligament forces likely have effects on the results of surgery in vivo. However, this study was only intended to investigate the accuracy of surgery with and without jig.

Conclusions: The results of our study do not support our hypothesis that jig usage affects the precision of TPLO surgery in toy-breed dogs. A jig is not necessary in toy-breed dogs for precise osteotomy and reduction of bone. Several retrospective papers have reported that the outcomes of TPLO in terms of bone healing and client assessment at follow-up were good without a jig in small-breed dogs (Witte and Scott, 2014; Cosenza *et al.*, 2015). Regardless of whether a jig is used, the surgeon should optimize osteotomy, reduction, and rotation with maximal accuracy to minimize postoperative complications. It may also be prudent to consider the characteristics of the tibia and TPLO techniques because a small field of view is a problem when performing TPLO in toy-breed dogs. Therefore, for experienced surgeons, we recommend performing TPLO without a jig due to the small bone size, difficulty of manipulation, complications associated with jig use, cost of installing a jig, and operation time.

Ethics approval and consent to participate: All procedures were approved by the Chungnam National University Animal Care and Use Committee. Eleven adult toy-breed dog cadavers were obtained from an animal shelter. The animals had been euthanized for reasons unrelated to this study.

REFERENCES

- Barnes DC, Trinterud T, Owen MR, *et al.*, 2016. Short-term outcome and complications of TPLO using anatomically contoured locking compression plates in small/medium-breed dogs with "excessive" tibial plateau angle. *J Small Anim Pract* 57:305-10.
- Bell JC and Ness MG, 2007. Does use of a jig influence the precision of tibial plateau leveling osteotomy surgery? *Vet Surg* 36:228-33.
- Bergh MS and Peirone B, 2012. Complications of tibial plateau levelling osteotomy in dogs. *Vet Comp Orthop Traumatol* 25:349-58.
- Boudrieau RJ, 2009. Tibial plateau leveling osteotomy or tibial tuberosity advancement? *Vet Surg* 38:1-22.
- Burton NJ, Fitzpatrick N and Wallace AM, 2013. Evaluation of cut accuracy and cis cortical damage for tibial plateau leveling osteotomy performed with and without aid of a novel saw guide: an in vitro study. *Vet Surg* 42:28-37.
- Cosenza G, Reif U and Martini FM, 2015. Tibial plateau levelling osteotomy in 69 small breed dogs using conically coupled 1.9/2.5 mm locking plates. *Vet Comp Orthop Traumatol* 28:347-54.
- Garnett SD and Daye RM, 2014. Short-term complications associated with TPLO in dogs using 2.0 and 2.7 mm plates. *J Am Anim Hosp Assoc* 50:396-404.
- Innes JF, Bacon D, Lynch C, *et al.*, 2000. Long-term outcome of surgery for dogs with cranial cruciate ligament deficiency. *Vet Rec* 147:325-8.
- Janovec J, Kyllar M, Midgley D, *et al.*, 2017. Conformation of the proximal tibia and cranial cruciate ligament disease in small breed dogs. *Vet Comp Orthop Traumatol* 30:178-83.
- Kergosien DH, Barnhart MD, Kees CE, *et al* 2004. Radiographic and clinical changes of the tibial tuberosity after tibial plateau leveling osteotomy. *Vet Surg* 33:468-74.
- Kim J, Heo S, Na J, *et al.*, 2016. Determination of femoral and tibial joint reference angles in small-breed dogs. *J Vet Clin* 33:340-5.
- Knight R and Danielski A, 2018. Long-term complications following tibial plateau levelling osteotomy in small dogs with tibial plateau angles >30°. *Vet Rec* 182:461.
- Kowaleski MP and McCarthy RJ, 2004. Geometric analysis evaluating the effect of tibial plateau leveling osteotomy position on postoperative tibial plateau slope. *Vet Comp Orthop Traumatol* 17:30-4.
- Kowaleski MP, Apelt D, Mattoon JS, *et al.*, 2005. The effect of tibial plateau leveling osteotomy position on cranial tibial subluxation: an in vitro study. *Vet Surg* 34:332-6.
- Lazar TP, Berry CR, Dehaan JJ, *et al.*, 2005. Long-term radiographic comparison of tibial plateau leveling osteotomy versus extracapsular stabilization for cranial cruciate ligament rupture in the dog. *Vet Surg* 34:133-41.
- Macias C, McKee WM and May C, 2002. Caudal proximal tibial deformity and cranial cruciate ligament rupture in small-breed dogs. *J Small Anim Pract* 43:433-8.
- Mariano AD, Kowaleski MP and Boudrieau RJ, 2016. Novel TPLO alignment jig/saw guide reproduces freehand and ideal osteotomy positions. *PLoS One* 11:e0161110.
- Schmerbach KI, Boeltzig CKM, Reif U, *et al* 2007. In vitro comparison of tibial plateau leveling osteotomy with and without use of a tibial plateau leveling jig. *Vet Surg* 36:156-63.
- Slocum B and Slocum TD, 1993. Tibial plateau leveling osteotomy for repair of cranial cruciate ligament rupture in the canine. *Vet Clin North Am Small Anim Pract* 23:777-95.
- Tan CJ, Bergh MS, Schembri MA, *et al.*, 2014. Accuracy of tibial osteotomy placement using 2 different tibial plateau leveling osteotomy jigs. *Vet Surg* 43:525-33.
- Wheeler JL, Cross AR and Gingrich W, 2003. In vitro effects of osteotomy angle and osteotomy reduction on tibial angulation and rotation during the tibial plateau-leveling osteotomy procedure. *Vet Surg* 32:371-7.
- Windolf M, Leitner M, Schwieger K, *et al.*, 2008. Accuracy of fragment positioning after TPLO and effect on biomechanical stability. *Vet Surg* 37:366-73.
- Witte PG and Scott HW, 2014. Tibial plateau leveling osteotomy in small breed dogs with high tibial plateau angles using a 4-hole 1.9/2.5 mm locking T-plate. *Vet Surg* 43:549-57.