



SHORT COMMUNICATION

Proliferating Cell Nuclear Antigen Expression in Canine and Feline Spontaneous and Injection-site Fibrosarcomas

Ishtiaq Ahmed^{1*} and Mahmut Sozmen²

¹Department of Pathobiology, College of Veterinary and Animal Sciences Jhang, Subcampus of University of Veterinary and Animal Sciences Lahore, Pakistan; ²Department of Veterinary Pathology, Faculty of Veterinary Medicine, Ondokuz Mayıs University, Samsun, 55139, Turkey

*Corresponding author: ishtiaqahmed@uvas.edu.pk

ARTICLE HISTORY (20-017)

Received: January 18, 2020
Revised: February 01, 2020
Accepted: February 02, 2020
Published online: February 15, 2020

Key words:

Canine
Feline
Fibrosarcoma
Injection-site Sarcoma
PCNA

ABSTRACT

Fibrosarcoma, a tumor composed of spindle-shaped fibroblasts, is grouped in soft tissue sarcomas which constitute one of the most important tumors in companion animals. Cell proliferation index is a good indicator of the biological behavior of the tumors which is estimated either by mitotic index or cell proliferation markers. In the current study, we investigated the immunohistochemical expression of proliferating cell nuclear antigen (PCNA) in spontaneous and injection-site fibrosarcomas in dogs and cats. A positive correlation was noticed between the PCNA expression, mitotic index, tumor grade and degree of differentiation of the tumor cells in tumors from both of these species. PCNA expression was significantly different between different tumor grades in dogs and cats. It can be concluded from this study that PCNA is a useful marker for predicting the outcome of the canine and feline fibrosarcomas.

©2020 PVJ. All rights reserved

To Cite This Article: Ahmed I and Sozmen M, 2020. Proliferating cell nuclear antigen expression in canine and feline spontaneous and injection-site fibrosarcomas. Pak Vet J, 40(4): 531-533. <http://dx.doi.org/10.29261/pakvetj/2020.019>

INTRODUCTION

Fibrosarcoma is a malignant neoplasm of spindle-shaped cells fibroblasts. Skin, subcutaneous tissue, or oral cavity are the usual sites of development of this malignancy. Generally, there is no breed or gender predisposition but aged animals are at high risk of developing this tumor. Histological appearance of fibrosarcoma may vary from well-differentiated spindle cells with interwoven or herringbone pattern to poorly differentiated pleomorphic cells with a high mitotic index. The tumor is generally locally infiltrative with rare metastasis (Vascellari *et al.*, 2003).

Vaccine-associated sarcoma or injection-site sarcoma (ISS) is a relatively new subtype of soft tissue sarcomas observed more commonly in cats than dogs (Vascellari *et al.*, 2003). Though ISS may develop into different types of mesenchymal tumors, fibrosarcoma is the predominant subtype (Woodward, 2011). Though initially, tumor development was linked to chronic inflammatory response following administration of aluminum-based vaccine (especially rabies & feline leukemia virus), recent advancements in the literature suggest that other foreign materials e.g. long-acting antibiotics, microchips can also

lead to a neoplastic growth (Jacobs *et al.*, 2017; Zabielska-Koczywaś *et al.*, 2017). Chronic inflammation is believed to play a significant role in the pathogenesis of these injection-site sarcomas by DNA damage, cellular transformation, and clonal expansion (Woodward, 2011).

PCNA or cyclin is a well-conserved protein involved in DNA replication, DNA repair, chromatin remodeling, and control of cell cycle and is present in all eukaryotic species as well as in prokaryotes. The degree of PCNA expression has been correlated with the degree of malignancy in many canine and feline tumors (Carvalho *et al.*, 2016; Tiwari *et al.*, 2016). However, less is known about the correlation of PCNA expression with the tumor grade and mitotic index in canine and feline cutaneous fibrosarcomas. The current study highlights the significance of PCNA as an indicator of cellular proliferation index in canine and feline fibrosarcomas.

MATERIALS AND METHODS

A total of 22 cases of tumors (12 cats with age varying from 5-13 years & 10 dogs of 4-14 years age) diagnosed as soft tissue sarcomas were selected from the departmental archive. Paraffin-embedded blocks were

sectioned at 4µm and slides were stained with hematoxylin and eosin technique. The tumors were reanalyzed and classified based upon their histological characteristics. Grading of the tumors was carried out as per criteria established for soft tissue sarcomas which take into consideration the mitotic index, necrosis, and degree of differentiation of neoplastic cells (Vascellari *et al.*, 2003). Mitotic count was determined in an area of 2.37mm² at 40x (10 high power field) by using a microscope assembled with an ocular of field number (FN) 22mm.

Histogenesis of the tumors was confirmed by using mesenchymal marker vimentin. PCNA was used to assess the proliferating potential of the tumor cells through a streptavidin-biotin peroxidase immunohistochemical staining technique. Briefly, after hydration, sections were treated with 3% H₂O₂ to block endogenous peroxidase activity for 10 minutes. After washing with phosphate-buffered saline (PBS, pH 7.4), for antigen retrieval sections were incubated with citrate buffer (pH 6.0) for 10 minutes in a microwave oven (600W). To prevent nonspecific binding of antibodies to tissues, all sections were pre-incubated in a blocking solution (Zymed Laboratories, Inc.; San Francisco, CA, USA) at room temperature for 10 minutes. After washing with PBS, incubation with primary antibodies (PCNA 1:100, Polyclonal, Thermo scientific, PA5-27214; Vimentin 1:10000, Monoclonal, Abcam, ab 28028) was done for 1 hour at room temperature in a humidified chamber. After rinsing 2-3 times, the biotin-conjugated secondary antibody was applied for 20 minutes at room temperature. It was followed by washing and application of streptavidin-biotin-peroxidase complex for 20 minutes.

After brief rinsing with PBS labeling was “visualized” with 3-amino-9-ethylcarbazole (AEC substrate kit; Invitrogen, Camarillo, Canada) as the chromogen. Sections were counterstained briefly with Harris hematoxylin for 1 minute, rinsed with tap water, and mounted with an aqueous mounting medium (Vision Mount; Lab Vision, USA). Appropriate positive and negative controls were used for immunohistochemistry. For calculation of proliferation index photographs of 10 high power microscopic fields were captured and cells were manually counted (Sozmen *et al.*, 2014).

Statistical analysis: The mitotic index and PCNA expression, degree of differentiation & PCNA were subjected to Spearman’s correlation coefficient analysis while PCNA expression amongst different grades was compared by using the Kruskal-Wallis test (dogs) and Mann-Whitney (cats) using GraphPad Prism version 8.

RESULTS AND DISCUSSION

The 8 cases from dogs were classified as spontaneous cutaneous fibrosarcomas while 2 showed features of injection-site fibrosarcoma. Injection-site fibrosarcoma has been observed in dogs at sites of microchip implants or other foreign materials (Jacobs *et al.*, 2017), however, in the present study history about any foreign material injection or implant was unavailable. All the feline tumors were consistent with the histological features of injection-site fibrosarcoma. Most of these ISS were located in the cervical region while few were found in the flank region.

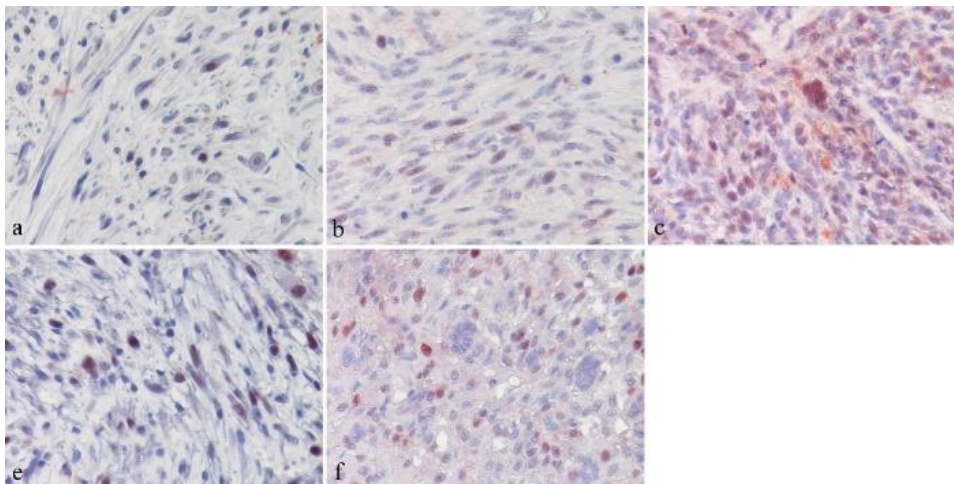


Fig. 1: a, b and c demonstrate the PCNA expression in grade I, grade II and grade III canine fibrosarcomas while d and e show nuclear staining of PCNA in grade II and grade III feline injection-site fibrosarcomas (IHC, 400x). The number of positive cells varies across different tumor grades.

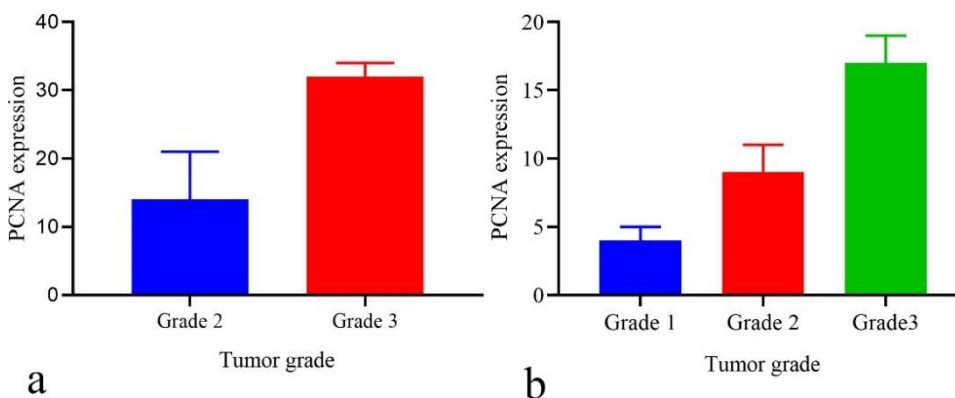


Fig. 2: Comparison of PCNA expression amongst different tumor grades in the cat (P=0.0040) and dog (P=0.0286) fibrosarcomas, respectively.

Injection-site fibrosarcoma and spontaneous fibrosarcoma differ in terms of histopathological features where the former has intense mononuclear cell infiltration in the tumor periphery, presence of central necrotic area in the tumor and cellular pleomorphism i.e. presence of multinucleated giant cells, sometimes with phagocytosed foreign material (Woodward, 2011). Amongst canine tumors, three were placed in grade I, four in grade II and three in grade III category. Out of 12 feline cases, 8 were classified as grade II and 4 as grade III tumors. As observed in this as well as previous studies, injection-site fibrosarcomas are more aggressive in nature and mostly fall in the category of grade II or grade III sarcomas (Jacobs *et al.*, 2017; Zabielska-Koczywaś *et al.*, 2017).

All tumors stained positive with vimentin. PCNA expression (Fig. 1a-c) in canine fibrosarcomas varied to as low as 1% in grade I tumors to as high as 19% in grade 3 tumors. There was a strong positive correlation ($r=0.7130$, $P\text{ value}=0.0384$) between the mitotic index and PCNA expression as well as between tumor grade and PCNA ($r=0.7664$, $P=0.0129$). Moreover, the degree of tumor differentiation and PCNA were also positively correlated ($r=0.7485$, $P=0.0286$) in canine tumors. The results are in agreement with previous studies which showed that PCNA activity is increased in different types of high-grade tumors e.g. in canine round cell and mammary tumors (Carvalho *et al.*, 2016; Tiwari *et al.*, 2016). However, we found only one study reporting a differential expression of PCNA in canine fibromas and fibrosarcomas (Hung *et al.*, 2000). As the high-grade tumors have a faster rate of cell division so there will be an increase in the concentration of proliferative proteins such as PCNA (Martano *et al.*, 2016). A high proliferation rate is indicative of malignancy and usually correlated with guarded prognosis (Dutra *et al.*, 2008). In feline cases, the correlation coefficient for mitotic index and PCNA expression (Fig. 1d & e) was 0.6728 ($P=0.0208$), for tumor grade and PCNA was 0.8222 ($P=0.0040$) while between the degree of differentiation and PCNA was 0.2077 ($P=0.5909$). The median values of PCNA expression amongst different grades of tumors differed significantly in cats as well as in dogs (Fig 2a & b). Similar results have been reported by a previous study using a chicken chorioallantoic membrane model for feline injection-site fibrosarcomas and spontaneous fibrosarcomas (Zabielska-Koczywaś *et al.*, 2017). They concluded that PCNA expression is strongly correlated with tumor grade than ki67 and is a better prognostic marker for feline injection-site fibrosarcomas. Though due to the role of PCNA in the DNA repair process, ki67 is

considered a more specific marker in human and veterinary oncology, a marked variation occurs in the expression pattern of these two markers across different tumors (Zabielska-Koczywaś *et al.*, 2017). So, as supported by a previous study, it can be concluded that PCNA expression can be used to predict the biological behavior of feline and canine injection-site fibrosarcomas and canine spontaneous fibrosarcomas. However, further studies using large cohorts of animals are necessary.

Acknowledgments: IA is thankful to the Turkish Scientific and Technological Research Council for providing the grant for doctoral studies under the Tubitak-2215 program and University of Veterinary & Animal Sciences Lahore for study leave.

Authors contribution: IA and MS equally contributed to the project design, execution, and data analysis and manuscript preparation.

REFERENCES

- Carvalho MI, Pires I, Prada J *et al.*, 2016. Ki-67 and PCNA expression in canine mammary tumors and adjacent nonneoplastic mammary glands: prognostic impact by a multivariate survival analysis. *Vet Pathol* 53:1138-46.
- Dutra AP, Junior GMA, Schmitt FC *et al.*, 2008. Assessment of cell proliferation and prognostic factors in canine mammary gland tumors. *Arq Bras Med Vet Zootec* 60:1403-12.
- Hung LC, Pong VF, Cheng CR *et al.*, 2000. An improved system for quantifying AgNOR and PCNA in canine tumors. *Anticancer Res* 20:3273-80.
- Jacobs TM, Poehlmann CE and Kiupel M, 2017. Injection-site sarcoma in a dog: clinical and pathological findings. *Case Rep Vet Med* pp:6952634, 4 pages.
- Martano M, Restucci B, Ceccarelli DM *et al.*, 2016. Immunohistochemical expression of vascular endothelial growth factor in canine oral squamous cell carcinomas. *Oncol Lett* 11:399-404.
- Sozmen M, Devrim AK, Tunca R, *et al.*, 2014. Protective effects of silymarin on fumonisin B-1 induced hepatotoxicity in mice. *J Vet Sci* 15:51-60.
- Tiwari KP, Bhaiyat MI, Chikweto A *et al.*, 2016. Expression pattern of proliferating cell nuclear antigen (PCNA) in round cell tumors of dogs from Grenada, West Indies. *Indian J Vet Pathol* 40:144-7.
- Vascellari M, Melchiotti E, Bozza MA, *et al.*, 2003. Fibrosarcomas at presumed sites of injection in dogs: Characteristics and comparison with non-vaccination site fibrosarcomas and feline post-vaccinal fibrosarcomas. *J Vet Med A Physiol Pathol Clin Med* 50:286-91.
- Woodward KN, 2011. Origins of injection-site sarcomas in cats: the possible role of chronic inflammation-a review. *ISRN Vet Sci* pp:210982, 16 pages.
- Zabielska-Koczywaś K, Wojtkowska A, Dolka I, *et al.*, 2017. 3D chick embryo chorioallantoic membrane model as an in vivo model to study morphological and histopathological features of feline fibrosarcomas. *BMC Vet Res* 13:201.