



## CASE REPORT

### Canine Disorder of Sex Differentiation

Hee-Ryung Lee<sup>1,2§</sup>, Gareeballah Osman Adam<sup>2,3#</sup>, Dong Kwon Yang<sup>2</sup>, Sei-Jin Lee<sup>4</sup>, Hee-Seo Kim<sup>2,\*</sup> and Shang-Jin Kim<sup>2\*</sup>

<sup>1</sup>Hansarang Animal Hospital, Seoul, 02880, Republic of Korea; <sup>2</sup>Department of Pharmacology, College of Veterinary Medicine, Jeonbuk National University, Iksan Campus, 79 Gobong-ro, Iksan-si, Jeollabuk-do 54596 Republic of Korea;

<sup>3</sup>Department of Veterinary Medicine and Surgery, College of Veterinary Medicine, Sudan University of Science and Technology, P.O. Box No. 204, Hilat Kuku, Khartoum, Sudan; <sup>4</sup>Korea Basic Science Institute Jeonju Center, Deokjin-gu, Jeonju-si, Jeollabuk-do 54896, Republic of Korea

<sup>§</sup>These authors contributed equally to this work.

\*Corresponding author: smart\_sense@naver.com (HS Kim); abbasj@jbnu.ac.kr (SJ Kim)

#### ARTICLE HISTORY (20-120)

Received: March 18, 2020  
Revised: April 27, 2020  
Accepted: May 03, 2020  
Published online: May 25, 2020

#### Key words:

Pseudo-hermaphroditism  
Dog  
Cocker Spaniel  
Y-Chromosome  
Surgical correction

#### ABSTRACT

The disorder of the X chromosome causes defects in sex differentiation in the female phenotype. This work reports a six-month-old, Cocker Spaniel dog with intersex disorder diagnosed as pseudo-hermaphroditism. The dog was brought to the clinic with a swollen reddish penis-like protrusion, which was partially covered by the sheath. Clinical examination revealed the presence of raised nipple-like structures, resembling the nipples and extending from chest to groin region. However, the testes could not be detected. PCR analysis revealed the absence of the Y chromosome. A corrective surgery, including clitoridectomy, and removal of uterus and testicles-like structures, was performed. Histological examination of the removed organs showed underdeveloped testes and well-recognized endometrium. This report suggests that surgical correction may be used to overcome any possible complications in a six-month-old dog with pseudo-hermaphroditism.

©2020 PVJ. All rights reserved

**To Cite This Article:** Lee HR, Adam GO, Yang DK, Lee SJ, Kim HS and Kim SJ, 2020. Canine disorder of sex differentiation. Pak Vet J, 40(4): 540-542. <http://dx.doi.org/10.29261/pakvetj/2020.050>

#### INTRODUCTION

Disorder of sexual differentiation (DSD) is caused by chromosomal abnormalities, mainly DAX-1 duplication gene on the X chromosome. During normal embryogenesis, DSD can occur, which results in genital tract malformations that can be mild or severe, including pseudo-hermaphroditism (PHP) (García-Acero *et al.*, 2020). Most frequently reported PHP is found in the male, and is due to the failure of paramesonephric duct to regress (Persistent Mullerian Duct Syndrome, PMDS) or due to the failure of masculinization because of hormonal disorders such as androgen insensitivity syndrome (Mullen and Behringer, 2014). PMDS, which is a hereditary autosomal recession in the miniature Schnauzer, is most common in the dog.

After the diagnosis of sexual disorder using different methods and identifying the gender of the animal, surgical intervention seems to be the only available approach to treat the condition (Torad and Hassan, 2016). The objective of this study was to report the history and clinical signs, identify the sexual identity and surgical correction of the deformed parts in a dog.

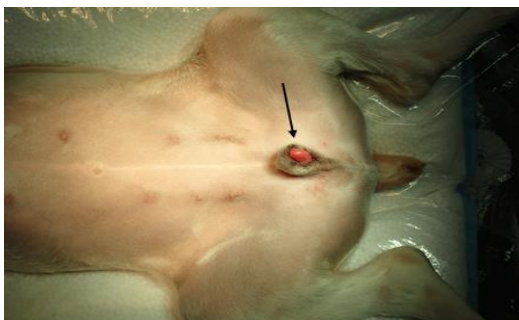
**History and clinical examination:** A six-month-old, Cocker Spaniel dog, looking apparently healthy and weighing 6.75 kg, was brought to Sarang Veterinary Clinic, Seoul, Republic of Korea. The owner wondered if the dog was a male or female. Clinical examination of the animal showed a penis-like protrusion, which was swollen and reddish in color (Fig. 1). This penis-like protrusion was partially covered by the sheath. Moreover, raised structures resembling the nipples and extending from chest to groin region were also observed (Fig. 1). However, the testicles were not palpable in the area between the inguinal ring and the under-developed scrotum. A radio-opaque urinary catheter was inserted via the urethral orifice to take a right lateral abdominal radiograph, which demonstrated the course of the urethra through the radio-opaque catheter (Fig. 2A). Also, a ventral-abdominal radiograph was taken without a catheter, which revealed the presence of a faintly radio-opaque penis-like structure, which was assumed to be the os-clitoridis (Fig. 2B). As a tentative diagnosis, it was suggested that the dog was suffering from cryptosporidium.

**Chromosomal analysis:** To determine the sexual identity of the dog, PCR was undertaken for the detection of Y

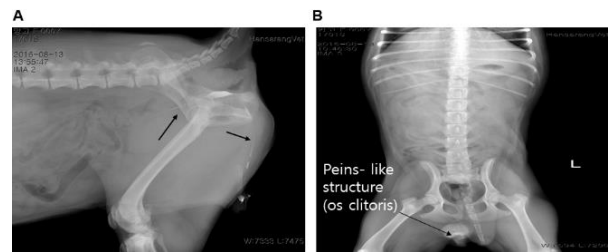
chromosome. Primers of canine sex-determining region Y (SRY) genomic sequence were designed according to a previously published study, forward CTCGCGATCAAAG GCGCAAGAT and reverse TTCGGCTTCTGTAAGCAT TTTC (Prugnard *et al.*, 2016). PCR kit (Promega Co., Madison, WI, USA) was used for the chromosomal analysis. The PCR was carried out in a thermal cycler (Takara Bio, Inc., Japan) and the product was run in the gel with a DNA ladder marker. The bands were detected using SYBR Green I (Sigma, St. Louis, MO, USA) staining and a blue light trans-illuminator (Piazza *et al.*, 2017). PCR electrophoresis revealed the absence of Y chromosome in the dog (Fig. 3), which suggested that sex identity of the dog was a female. Therefore, the surgical removal of the male gonads like structures was performed, as described below:

**Surgical intervention:** Surgical removal of the male gonads like structures was performed through celiotomy, gonadectomy, and clitoridectomy, as described by Sumner *et al.* (2018). Briefly, after induction of anesthesia, a ventral midline incision (15 cm) was made. A testicle-like structure connected to epididymis, identified in the right caudal abdomen, was ligated using 3-0 synthetic polymer (Go, Medical Korea) and removed. Then, a 3-cm incision was made over the subcutaneous mass, the left testicle was isolated and removed. After cleaning, a 3-0 synthetic polymer was used to close the skin incision. For clitoridectomy, urethral opening was located using urinary catheter (size 16). Surgical incision was made over the dorsal aspect of the os-clitoris, which was removed using blunt dissection. The prostate gland couldn't be found. The anomalous gonads and the uterus were removed and a routine closure was made. Simple continues suturing was used to close the clitoral incision. The abdomen was closed, as previously prescribed. To ensure resolving of swelling in the operation site, the urinary catheter was kept for 24 h. Urination was followed up after removal of the urinary catheter to encounter any possible complications. The position of internal genitalia after surgical removal is shown in Fig. 4. Post-operative care included administration of ceftriaxone HCL 500 mg (Daewoong pharm. co. Ltd, Korea) for five days, as well as vaginal wash using povidone-iodine (Daewoong pharm. co. Ltd, Korea). The dog showed complete recovery without any complication.

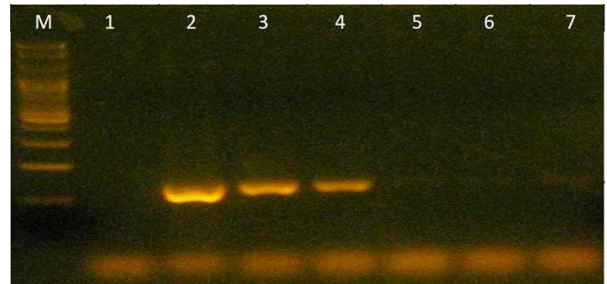
**Differential diagnosis:** Immediately after removal, samples of testes-like and uterine tube-like structures were taken. These samples were processed for the routine hematoxylin and eosin (H&E) staining for histological examination (Webster *et al.*, 2017).



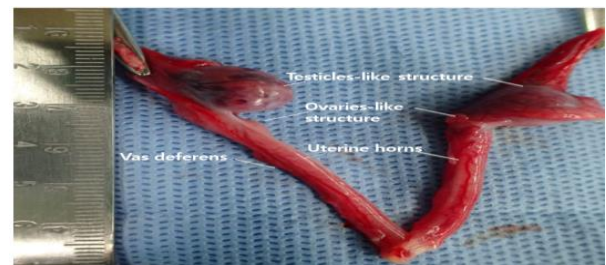**Fig. 1:** Six-month-old dog with large protruded genitalia (arrow). Raised structures, resembling the ripples and extending from chest to groin region can also be seen.



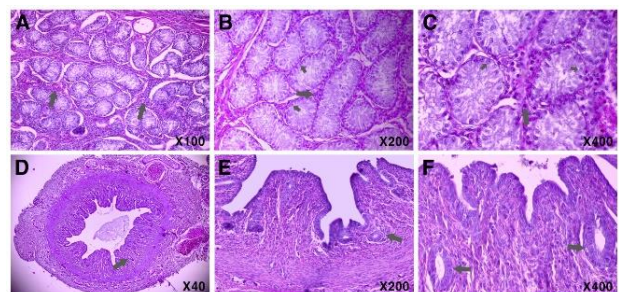
**Fig. 2:** (A) Lateral radiograph of a 6-month old pseudo-hermaphrodite dog, demonstrating the course of the urethra through a radio-opaque catheter (arrows); (B) ventral abdominal radiograph showing a faintly radio-opaque penis-like structure or os-clitoridis. L, left side.



**Fig. 3:** Sexual chromosome differentiation test. Gender identification of dog by PCR amplification of Y chromosome-specific sequences from genomic DNA isolated from whole blood. M; marker, 1; specimen, 2-4; xy control, 5-7; xx control.



**Fig. 4:** Depiction of internal genitalia after surgical removal.



**Fig. 5:** Photomicrograph of testis-like structure. (A) arrows indicate the interstitial tissue (100 magnification); (B & C) large arrows indicate round Leydig cells (200 & 400 magnification); (D-F) uterine tube-like parts, arrows indicate the endometrial glands (40x, 200x, & 400x magnification)

Histologically, interstitial tissue in the testis was more abundant compared to the healthy adult dog (Fig. 5A), with round Leydig cells were detected in interstitial tissue (Fig. 5B&C). Meanwhile, only spermatogonia were identified in seminiferous tubules (Fig. 5B&C), without any indication of active spermatogenesis. Uterine tissue with endometrial glands could also be detected in the tubule (Fig. 5D-F). These histological findings suggested the distorted testes with aspermatogenesis.

## DISCUSSION

The chromosomal study of the dog suggested the absence of Y chromosome. Therefore, the possibility of the dog to be a male was excluded. A previous study also revealed that numerous species including, humans and dogs experienced urogenital defects during development (Dietz *et al.* 2018). Szczerbal *et al.* (2017) also observed that disorder of sex development in a cat with chromosome mosaicism showed external genitalia ambiguity, such as undeveloped penis and scrotum.

The urethra was abnormally widely separated from the enlarged protruded os-clitoris. Hence, the removal of the clitoris with its entire os-clitoris was done carefully. Urinary tract infection, which is common in such a surgical operation (Park *et al.*, 2016), was successfully avoided.

Removal of testes, ovaries, and uterine horn-like structure is the central part of corrective surgery of FPH to minimize the risk of ovaries and uterine diseases or abnormal growth (Gregory and Trower, 1997; Sacks and Béraud, 2012). In the present study, the externally protruded part in the dog appeared to be an os-clitoris or enlarged clitoris. Corpora cavernosa of male penis resembles the roots of the clitoris in dogs (Gregory and Trower, 1997), ossification and hyperfibroplasia of the corpora cavernosa leads to canine os penis. Os-clitoris could be the outcome of the similar ossification process.

Because of difficulties in performing usual skin preparation for clitoridectomy, antibiotics were used postoperatively. Instead of resembling the normal anatomical position of either a male (distal end of the pars longa glands) or female (approximately 3 cm cranial to the clitoris), the urethral opening was located along the caudo-ventral surface of the clitoris at the caudal end of the hypospadias, which is abnormally located urinary orifice in the male due to incomplete masculinization of urogenital sinus (Marei *et al.*, 2016). Initially, the embryo has the undifferentiated ducts and structures, from which both internal and external genitalia develop (Marei *et al.*, 2016; Araujo *et al.*, 2018). The possible cause of this condition seems to be the genetic disorder during embryogenesis.

**Conclusions:** The case study has shown that a sex disorder of external genitalia can be confirmed by chromosomal analysis. A surgical management of the external genitalia in case of feminine sexual disorder is recommended in dogs with similar clinical signs.

**Acknowledgments:** The Ministry of Science and Technology, the Republic of Korea supported this work (NRF-2018R1A2B6003332 and 2018R1D1A1B07042552).

This work was supported by Korea Institute of Planning and Evaluation for Technology in Food, Agriculture and Forestry (IPET) through Agriculture, Food and Rural Affairs Convergence Technologies Program for Educating Creative Global Leader, funded by Ministry of Agriculture, Food and Rural Affairs (MAFRA; 320005-4). The authors would like to thank the staff of Hansarang Veterinary Clinic, Seoul, Korea for their technical and clinical assistance.

**Authors contribution:** Shang-Jin Kim and Hee-Soo Kim conceptualized and designed the study. Gareeballah Osman Adam and Hee-Ryung Lee contributed in the treatment of the dog and writing of the manuscript. Yang Dong Kwon contributed to materials and chromosomal study and critical review of the final version of the manuscript.

## REFERENCES

- Araujo MS, Paulo OL, Camargo LS, *et al.*, 2018. Gonadal steroid hormones levels in a bitch with true bilateral hermaphroditism. *J Pharma Pharmacol* 6:521-5.
- Dietz L, Arnold AMK, Goerlich-Jansson VC, *et al.*, 2018. The importance of early life experiences for the development of behavioural disorders in domestic dogs. *Behaviour* 155:83-114.
- García-Acero M, Moreno O, Suárez F, *et al.*, 2020. Disorders of sexual development: Current status and progress in the diagnostic approach. *Curr Urol* 13:169-78.
- Gregory SP and Trower ND, 1997. Surgical treatment of urinary incontinence resulting from a complex congenital abnormality in two dogs. *J Small Anim Pract* 38:25-8.
- Marei MM, Fares AE, Abdelsattar AH, *et al.*, 2016. Anatomical measurements of the urogenital sinus in virilized female children due to congenital adrenal hyperplasia. *J Pediatr Urol* 12: 282e1-282e8.
- Mullen RD and Behringer RR, 2014. Molecular genetics of Müllerian duct formation, regression and differentiation. *Sex Dev* 8:281-96.
- Park KM, Nam HS, Hussein KH, *et al.*, 2016. Surgical management of vesicoureteral reflux with recurrent urinary tract infection after renal transplantation in a dog. *J Am Vet Med Assoc* 248:309-14.
- Piazza VG, Bartke A, Miquet JG, *et al.*, 2017. Analysis of different approaches for the selection of reference genes in RT-qPCR experiments: A case study in skeletal muscle of growing mice. *Int J Mol Sci* 18:1060.
- Prugnard C, Lamia AB, Cherel Y, *et al.*, 2016. Early sex determination in the canine foetus by ultrasound and PCR. *Anim Reprod Sci* 165:56-68.
- Sacks MK and Béraud R, 2012. Female pseudo-hermaphroditism with cloacal malformation and related anomalies in a dog. *Can Vet J* 53:1105-8.
- Sumner SM, Grimes JA, Wallace ML, *et al.* 2018. Os clitoris in dogs: 17 cases (2009-2017). *Can Vet J* 59:606-10.
- Szczerbal I, Stachowiak M, Nowacka-Woszek J, *et al.*, 2017. Disorder of sex development in a cat with chromosome mosaicism 37, X/38, X, r (Y). *Reprod Domest Anim* 52:914-7.
- Torad FA and Hassan EA, 2016. Surgical correction of female pseudohermaphroditism in five pit bull dogs. *Asian J Anim Sci* 10:77-84.
- Webster KA, Schach U, Ordaz A, *et al.*, 2017. Dmrt1 is necessary for male sexual development in zebrafish. *Dev Biol* 422:33-46.